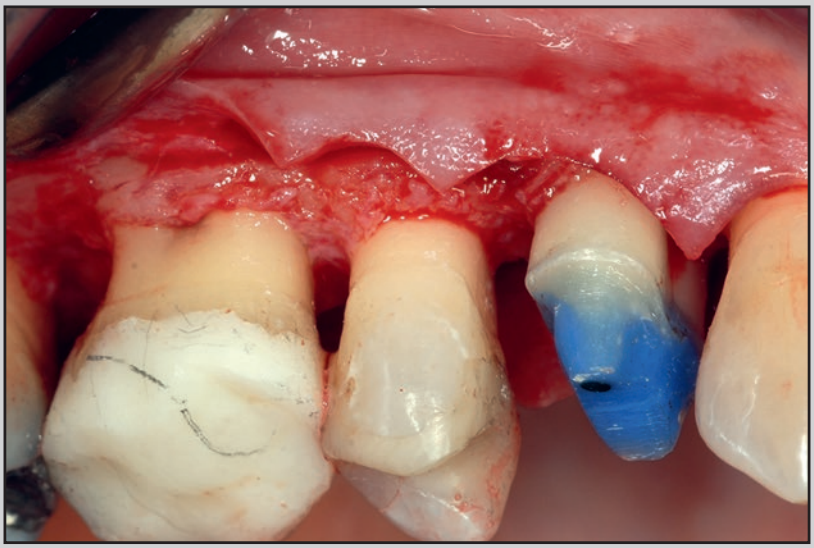

© 2021 BY QUINTESSENCE PUBLISHING CO, INC. PRINTING OF THIS DOCUMENT IS RESTRICTED TO PERSONAL USE ONLY.
NO PART MAY BE REPRODUCED OR TRANSMITTED IN ANY FORM WITHOUT WRITTEN PERMISSION FROM THE PUBLISHER.

Treatment of Teeth with Insufficient Clinical Crown. Part 1: One-Year Clinical Outcomes of a Minimally Invasive Crown-Lengthening Approach

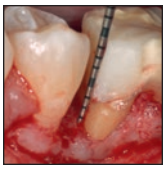

Pierpaolo Cortellini, MD, DDS[1]
Simone Cortellini, DDS, MSc[2]
Daniele Bonaccini, DDS[3]
Gabrielle Stalpers, DDS[1]
Aniello Mollo, DDS[3]

This study describes a clinical strategy based on a flowchart developed to facilitate the treatment of teeth with a severely compromised clinical crown. A group of 168 teeth in 126 patients required periodontal surgery and received a minimally invasive crown-lengthening procedure with the aim to reach a minimal supracrestal tissue attachment width of 2.5 mm, including a free space between the cervical margin of the restoration and the bottom of the sulcus. Surgery was performed with the aid of an operating microscope and microsurgical instruments, trying to reduce bone surgery and invasiveness as much as possible. An average postsurgical radiographic bone resection of 1 ± 0.6 mm was measured. Endodontic treatment was necessary in 73 teeth, re-treatment in 51. Most of the teeth (124 in 94 patients) received a full crown, while the remaining 44 received a direct (24 teeth) or an indirect (20 teeth) reconstruction. Six teeth were orthodontically extruded before surgery. The 1-year average pocket depth at the treated units was 2.5 ± 0.5 mm, resulting in a reduction of 0.7 ± 0.9 mm compared to the preoperative measurement (P < .0001). Bleeding on probing was detected in 19 sites (11.3%) and was significantly reduced from the preoperative condition (57 sites, 33.9%). The distance between the apical margin of the restoration and the gingival margin was 0.2 ± 0.4 mm (range: 0 to 1 mm); clinical attachment level was 2.7 ± 0.6 mm. A clinical approach based on minimally invasive crown lengthening with minimal or no ostectomy and high-quality restorative dentistry resulted in healthy periodontal and dental condition of all the treated units at the 1-year follow-up.
Int J Periodontics Restorative Dent 2021;41:487–496. doi: 10.11607/prd.5660

[1]Private Practice, Florence, Italy; Accademia Toscana di Ricerca Odontostomatologica (ATRO) Florence, Italy; Section of Periodontology, Department of Oral Health Sciences, KU Leuven & Dentistry, University Hospitals, KU Leuven, Leuven, Belgium.
[2]Private Practice, Florence, Italy; Section of Periodontology, Department of Oral Health Sciences, KU Leuven & Dentistry, University Hospitals, KU Leuven, Leuven, Belgium.
[3]Private Practice, Florence, Italy.

Correspondence to: Dr Pierpaolo Cortellini, Via Carlo Botta 16, 50136 Firenze, Italy.
Email: sandro@cortellini.org

Submitted January 22, 2021; accepted March 10, 2021.
©2021 by Quintessence Publishing Co Inc.

Clinicians are frequently challenged with decision-making when treating teeth with severely compromised clinical crowns that often require complex multidisciplinary intervention. Crown lengthening is often required to provide adequate access and isolation of the cervical margin of the lesion, grant sufficient crown length, avoid an invasion of the supracrestal connective tissues, and render the cervical margin of the restoration cleansable for the patient and inspectable for the dentist.[1–3] Available evidence supports that infringement within the supracrestal tissue attachment and subgingival positioning of restorative cervical margins might be associated with inflammation and loss of clinical attachment.[1,4,5] The amount of tooth structure to be exposed with periodontal surgery is often debated. Authors have proposed a range of values from 3 to 5 mm,[6–11] historically based on the variability of the biologic width,[2,10,12,13] recently renamed "supracrestal tissue attachment width" by the 2017 consensus of the American Academy of Periodontology (AAP) and the European Federation of Periodontology (EFP).[5] Consistent bone removal is associated with many problems, such as the reduction of support of the treated tooth, bone removal from neighboring teeth, invasion of sensitive areas like furcations, and

© 2021 BY QUINTESSENCE PUBLISHING CO, INC. PRINTING OF THIS DOCUMENT IS RESTRICTED TO PERSONAL USE ONLY.
NO PART MAY BE REPRODUCED OR TRANSMITTED IN ANY FORM WITHOUT WRITTEN PERMISSION FROM THE PUBLISHER.

esthetic impairment. Adopting the biologically driven concept of minimally invasive crown lengthening, to create a minimal supracrestal tissue attachment width based on the position of the coronal portion of the supracrestal attachment rather than on the position of bone, might help to save periodontal support and reduce the amount of resective surgery. This case cohort evaluated the 1-year outcomes of a minimally invasive crown-lengthening procedure performed to allow for reconstruction of teeth with insufficient clinical crown.

Materials and Methods

Study Population and Experimental Design

This retrospective analysis from a periodontal case registry cohort established at the private practice of the authors in Florence, Italy, is in accordance with the Helsinki Declaration on experimentation involving human subjects. The present retrospective analysis was approved by the local ethical committee for clinical research of the Health Service of Tuscany (University Hospital of Firenze protocol ATRO2019, registration no. 15106_oss). All subjects gave informed written consent. Study population is represented by 168 teeth in 126 patients who were treated with a surgical approach for crown lengthening and tooth reconstruction between January 2010 and December 2013. Patient inclusion criteria were as follows: *(1)* aged 18 years or older, not pregnant or lactating, and in good general health; *(2)* presence of at least one tooth requiring crown reconstruction; *(3)* nonsmokers or those smoking 20 cigarettes/day; and *(4)* absence of untreated periodontal disease (patients with gingivitis or periodontitis were preliminarily treated with cause-related therapy). Patients received endodontic treatment, provisional reconstruction, orthodontic extrusion, surgical crown lengthening, and definitive reconstruction according to indications, as illustrated in Fig 1. All patients were offered to participate in a professional recall system (supportive periodontal care [SPC]) and to be reevaluated after 1 year.

Baseline Clinical Records

The following clinical parameters were recorded by an independent calibrated clinician (D.B.) at patient intake and at baseline,[14,15] before surgery: *(1)* full-mouth plaque scores (FMPS), recorded as the percentage of total surfaces (four aspects per tooth) that revealed the presence of plaque; *(2)* bleeding on probing (BOP), assessed dichotomously, and full-mouth bleeding scores (FMBS) were then calculated; *(3)* pocket depth (PD) and BOP at the treated teeth, measured at the site associated with the most apical position of the cervical lesion with a manual periodontal probe (PCP UNC15, Hu-Friedy). Patients were classified as periodontally healthy or presenting either with gingivitis or periodontitis. The cause of the clinical crown destruction (crown fracture, caries, reconstruction to be replaced) was registered, along with the sequence of interventions necessary for resolution of the clinical problem.

1-Year Clinical Records

At 1 year, the following clinical parameters were registered by the same calibrated clinician (D.B.): *(1)* FMPS and FMBS; *(2)* PD, gingival recession (REC), and BOP, measured at the same PD and BOP baseline measurement site; *(3)* clinical attachment levels (CAL), calculated as the sum of PD + REC; and *(4)* dental and periodontal complications or recurrences that occurred after the definitive restoration.

Measurements on Radiographs

Measurements were made on periapical radiographs taken immediately before surgery and at completion of teeth reconstruction by an independent calibrated clinician (S.C.): *(1)* distance from the cervical margin of the restoration to the alveolar bone (CM–BC); and *(2)* distance from the cervical margin of the restoration to the apex of the tooth (CM–A). The radiographs were measured with an electronic ruler at ×10 magnification (Sorriso, version 13, Dental Trey) on a high-definition monitor at a resolution of 1,600 × 1,200 pixels.

Investigator Calibration

A calibration exercise was performed by the clinical examiner

© 2021 BY QUINTESSENCE PUBLISHING CO, INC. PRINTING OF THIS DOCUMENT IS RESTRICTED TO PERSONAL USE ONLY.
NO PART MAY BE REPRODUCED OR TRANSMITTED IN ANY FORM WITHOUT WRITTEN PERMISSION FROM THE PUBLISHER.

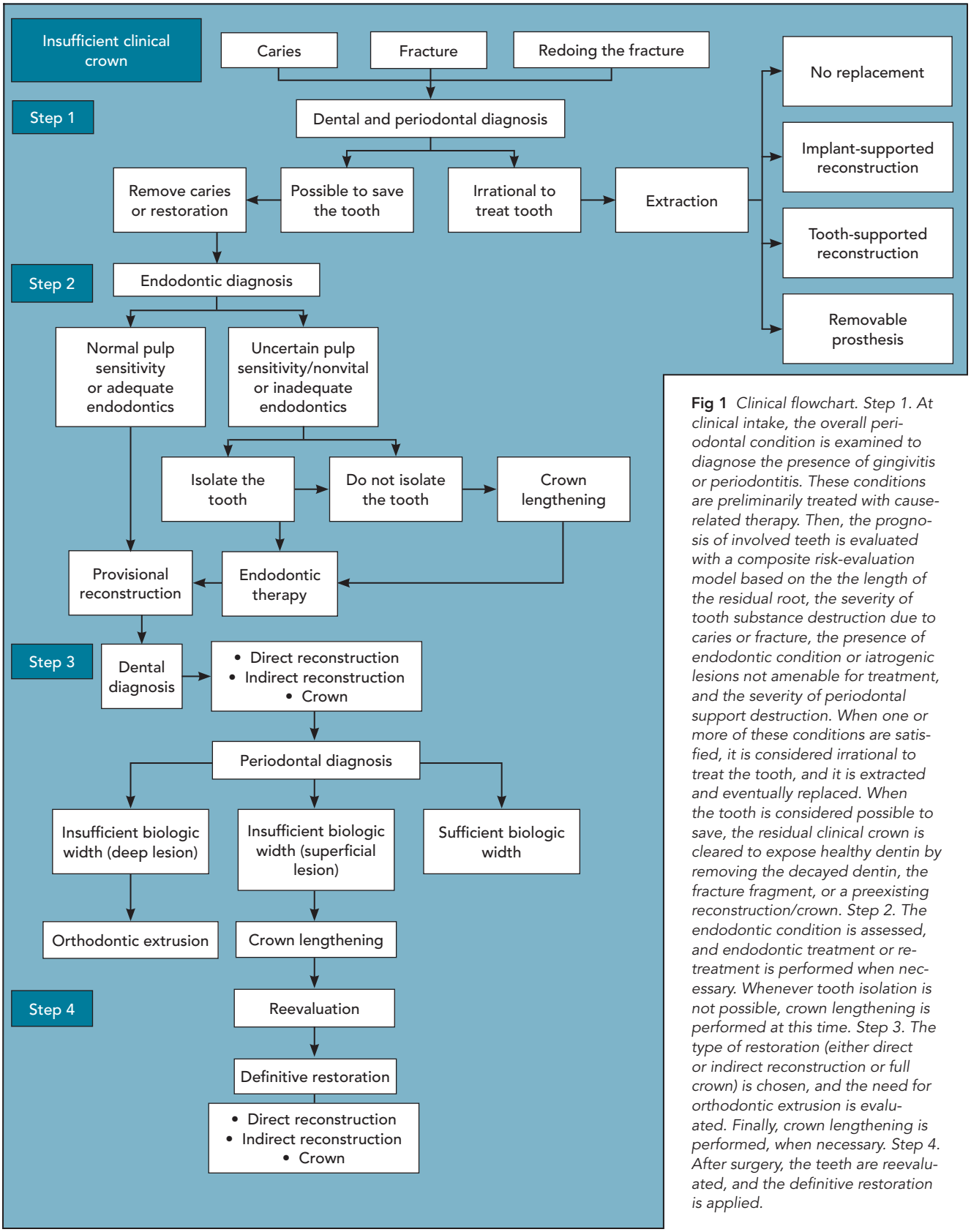

Fig 1 *Clinical flowchart. Step 1. At clinical intake, the overall periodontal condition is examined to diagnose the presence of gingivitis or periodontitis. These conditions are preliminarily treated with cause-related therapy. Then, the prognosis of involved teeth is evaluated with a composite risk-evaluation model based on the the length of the residual root, the severity of tooth substance destruction due to caries or fracture, the presence of endodontic condition or iatrogenic lesions not amenable for treatment, and the severity of periodontal support destruction. When one or more of these conditions are satisfied, it is considered irrational to treat the tooth, and it is extracted and eventually replaced. When the tooth is considered possible to save, the residual clinical crown is cleared to expose healthy dentin by removing the decayed dentin, the fracture fragment, or a preexisting reconstruction/crown. Step 2. The endodontic condition is assessed, and endodontic treatment or retreatment is performed when necessary. Whenever tooth isolation is not possible, crown lengthening is performed at this time. Step 3. The type of restoration (either direct or indirect reconstruction or full crown) is chosen, and the need for orthodontic extrusion is evaluated. Finally, crown lengthening is performed, when necessary. Step 4. After surgery, the teeth are reevaluated, and the definitive restoration is applied.*

© 2021 BY QUINTESSENCE PUBLISHING CO, INC. PRINTING OF THIS DOCUMENT IS RESTRICTED TO PERSONAL USE ONLY.
NO PART MAY BE REPRODUCED OR TRANSMITTED IN ANY FORM WITHOUT WRITTEN PERMISSION FROM THE PUBLISHER.

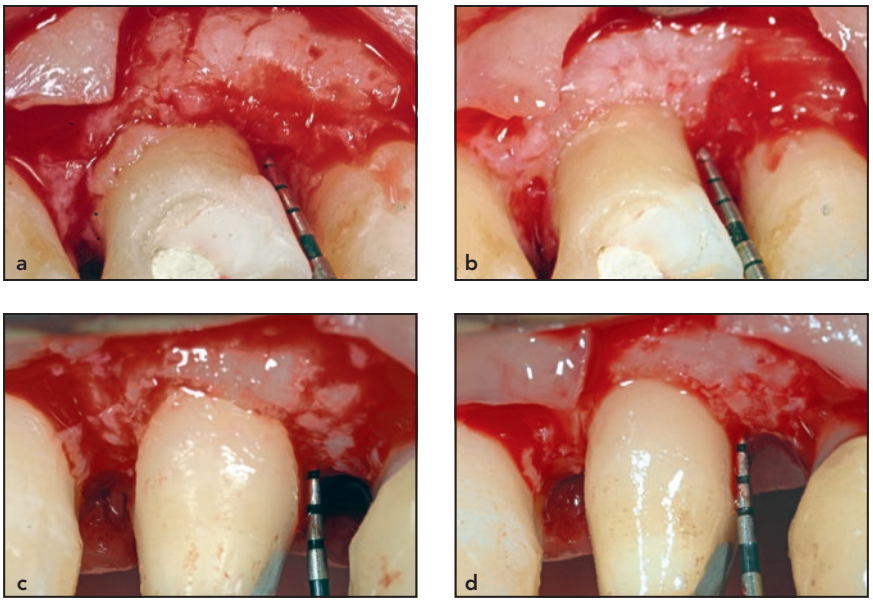

Fig 2 *Two examples of the creation of the minimal supracrestal tissue attachment width.* (a) *First example. The distance between the cervical margin and the bone is < 2 mm.* (b) *The tooth will be reconstructed with an overlay, requiring a 2-mm distance between the bone and cervical margin. This distance is obtained with ostectomy followed by careful root planing to the bone crest.* (c) *Second example. The distance between the cervical margin of the restoration and the bone is 3 mm.* (d) *The tooth will be restored with a full crown, requiring extra space for the ferrule effect. Ostectomy was performed to reach a 4-mm distance between the planned cervical margin and the root carefully planed to bone crest.*

(D.B.) with a PCP UNC15 periodontal probe to obtain acceptable reproducibility for PD and REC. He carried out duplicate measurements on five patients with conditions and treatments similar to the ones of the present case cohort. The intraexaminer agreement ± 1 mm of the measurements was > 90% ($P = .081$, paired *t* test). A calibration exercise was performed by the examiner of the radiographs (S.C.) on a set of 30 pairs of radiographs taken from patients with conditions and treatments similar to the ones of the present case cohort. The clinical examiner carried out duplicate measurements, and the intraexaminer agreement ± 0.2 mm of the measurements was 50%; ± 0.3 mm was 80%; and ± 0.4 mm was 95% ($P = .286$, paired *t* test).

Surgical Approach

Surgery consisted of apically positioned flaps with or without bone surgery (ostectomy and/or osteoplasty). Mesiodistal extension of the flap was kept at a minimum, involving the neighboring teeth and seldom extending further. Full-thickness envelope-like flaps were elevated slightly apical to the mucogingival junction. Vertical releasing incisions and periosteal fenestration were applied only when strictly necessary. With the root surface exposed, the cervical margin (CM) of the reconstruction was detected. CM was considered the most apical portion of healthy dentin when a direct or an indirect restoration had to be placed; in case of reconstruction with a full crown, an extra space of at least 2 mm was added for the ferrule effect. The distance between CM and the alveolar bone was measured with a periodontal probe. When this distance was ≥ 2.0 mm, ostectomy was not performed; when the distance was < 2 mm, ostectomy was performed to reach a 2.0-mm distance between the planned CM and bone. The root surface was planed with a curette for an extension of 2.0 mm apical to CM, removing all supracrestal fibers (Fig 2). Osteoplasty was performed when necessary to improve bone anatomy and favor the flap adaptation. Ostectomy and osteoplasty were extended to the neighboring teeth to create a flat-to-positive bone/gingival anatomy. The flap margin was apically positioned at the level of the crestal bone and sutured with external mattress sutures. All surgical procedures were performed by an experienced clinician (P.C.) with the aid of an operating microscope and microsurgical instruments (Protégé Global) at ×4 to ×16 magnification.[14] Patients were recalled at 1 week for suture

© 2021 BY QUINTESSENCE PUBLISHING CO, INC. PRINTING OF THIS DOCUMENT IS RESTRICTED TO PERSONAL USE ONLY.
NO PART MAY BE REPRODUCED OR TRANSMITTED IN ANY FORM WITHOUT WRITTEN PERMISSION FROM THE PUBLISHER.

Fig 3 (a and b) *A young patient with a very low level of oral hygiene presented with a mandibular left first molar with a fracture of the mesial aspect of the tooth, caries, and periapical lesions.* (c and d) *After cause-related therapy and removal of the old restoration, endodontic re-treatment and reconstruction were done, and the tooth was orthodontically extruded.* (e and f) *Following tooth extrusion, crown lengthening including ostectomy was performed to reach the due distance between the cervical margin of the restoration and the bone crest; the root surface was carefully planed to bone. An indirect reconstruction was then cemented.* (g) *Clinical and* (h) *radiographic views of the healthy dental and periodontal tissues at 1 year.*

removal and at 3 weeks for control and prophylaxis. Teeth were reconstructed with direct/indirect restorations (Fig 3) or full crowns (Fig 4) and enrolled in a 3- to 6-month SPC program.

Data Analysis

Anonymized data were entered in a personal computer and proofed for entry errors. No data points were missing. Descriptive statistics was expressed as means ± SD for continuous variables and percentages for categorical variables. Radiographic bone changes (CM–BC) and residual PD were the primary outcome variables. In order to estimate the distortion of the radiographs between the pre- and postsurgical exposure, the ratio between the linear measurements of pre- and postsurgery root length (RL1 and RL2, respectively) were calculated for the individual pair of radiographs (RL1/RL2). The RL1/RL2 ratio was used to correct posttreatment linear measurements to estimate radiographic bone changes. The tooth population was divided into two subgroups: one with a presurgical CM–BC < 2 mm and the other with CM–BC ≥ 2 mm. The population was also divided by separating periodontitis patients and the healthy/gingivitis ones, creating two sets of two subgroups (one set of subgroups categorized by CM–BC < 2 mm vs ≥ 2 mm, and the second set of subgroups categorized by the presence or absence of periodontitis). Comparisons between both sets of subgroups were made using unpaired *t* test. All statistical comparisons were conducted at the 0.05 level of significance.

© 2021 BY QUINTESSENCE PUBLISHING CO, INC. PRINTING OF THIS DOCUMENT IS RESTRICTED TO PERSONAL USE ONLY.
NO PART MAY BE REPRODUCED OR TRANSMITTED IN ANY FORM WITHOUT WRITTEN PERMISSION FROM THE PUBLISHER.

Fig 4 (a to c) *A patient presented with deep caries on the maxillary right first premolar and a fracture on the first molar.* (d and e) *Endodontic treatment and reconstruction were provided to the nonvital premolar along with caries elimination and reconstruction to the molar.* (f) *Surgery involved both teeth and was supplemented with bone resection on the premolar to create* (g) *a 4-mm distance between the planned cervical margin of the full crown and the bone crest. (h) The root was carefully planed to bone, and the flap was positioned at the bone crest.* (i) *Clinical and* (j) *radiographic views of the healthy dental and periodontal tissues at 1 year.*

Results

Baseline Characteristics

Crown lengthening and reconstruction was performed on 168 teeth in 126 patients (75 women) with a mean age of 45.7 ± 13.5 years (range: 20 to 76 years). Of the patients, 13 were smokers (13.1 ± 5.5 cigarettes/day; range: 3 to 20) and 3 were former smokers for a period > 10 years. Twelve patients were diagnosed as healthy, 78 with generalized gingivitis, and 36 with stage II, III or IV periodontitis. Average baseline FMPS and FMBS were 42.1% ± 24.9% and 22.5% ± 19.7%, respectively. The treated teeth were: 2 incisors (maxilla), 1 canine (maxilla), 46 premolars (27 maxillary, 19 mandibular), and 119 molars (48 maxillary, 71 mandibular). Reasons for intervention were caries in 128 teeth, fracture in 8 teeth, and need to replace a preexisting crown in 32 teeth. The baseline reconstructive and endodontic conditions are reported in Table 1.

© 2021 BY QUINTESSENCE PUBLISHING CO, INC. PRINTING OF THIS DOCUMENT IS RESTRICTED TO PERSONAL USE ONLY.
NO PART MAY BE REPRODUCED OR TRANSMITTED IN ANY FORM WITHOUT WRITTEN PERMISSION FROM THE PUBLISHER.

Table 1 Teeth Treated with Crown Lengthening and Crown Restoration

Type of clinical crown restoration	Total, n	Endodontic condition, n		
		No Endo Tx	Endo Tx	Endo Re-Tx
Baseline				
Reconstruction	102	75	27	
Full crown	46	13	33	
No restoration	20	20	–	
Total	168	108	60	
Final				
Reconstruction	44	28	15	1
Full crown	124	7	67	50
Total	168	35	82	51

Reconstruction = direct or indirect restoration; No restoration = teeth without any restorative reconstruction; No Endo Tx = teeth without any endodontic treatment, either vital or nonvital; Endo Tx = teeth with endodontic treatment; Endo Re-Tx = endodontic re-treatment.

Table 2 Presurgical and 1-Year Clinical Parameters of the Crown-Lengthening Group

	Preoperative	1 y	Difference	*P*
FMPS, %	11.9 ± 3.9	13.2 ± 2.5	–	.0002
FMBS, %	7.8 ± 2.8	7.7 ± 2.9	–	.332
PD, mm	3.2 ± 0.7	2.5 ± 0.5	0.7 ± 0.9	< .0001
REC, mm	–	0.2 ± 0.4	–	–
CM–BC, mm	1.6 ± 0.8	2.6 ± 0.7	1 ± 0.6	< .0001

FMPS = full-mouth plaque score; FMBS = full-mouth bleeding score; PD = pocket depth; REC = distance between the apical margin of the restoration and the gingival margin; CM–BC = radiographic distance between the cervical margin of the restoration and the crestal bone.

Surgical and Reconstructive Phase

At the first reevaluation after cause-related therapy, average FMPS was 11.9% ± 3.9% (range: 3.4% to 21%) and average FMBS was 7.8% ± 2.8% (range: 0.8% to 15%). Differences with baseline were clinically and statistically highly significant (*P* < .0001). Average PD (Table 2) was 3.2 ± 0.7 mm (range: 2 to 6 mm). PD was deeper in the periodontitis patients (3.4 ± 0.9 mm) than in the healthy/gingivitis patients (3.1 ± 0.5 mm); the difference was statistically significant (*P* = .027). BOP was detected in 57 sites (33.9%), and 21 of those sites were in periodontitis patients. The average presurgical radiographic CM–BC (Table 2) was 1.6 ± 0.8 mm (range: –1 to 5 mm), which was greater in periodontitis patients (1.9 ± 0.8 mm) than in healthy/gingivitis patients (1.5 ± 0.7 mm); the difference was statistically significant (*P* = .0006).

All teeth entered into the study successfully completed the planned treatment until definitive reconstruction. The type of definitive tooth restoration is reported in Table 1. Six teeth were treated with orthodontic extrusion before surgery, 73 teeth received endodontic treatment, and 51 teeth received endodontic re-treatment (Table 1). Crown lengthening was performed before endodontic treatment in 46 sites in 43 patients to allow for proper field isolation. The postsurgical radiographic measurements report an average distance between the cervical margin of the restoration and the crestal bone (CM–BC) of 2.6 ± 0.7 mm (range: 1.3 to 4.8 mm). The difference between preoperative and postoperative radiographic

© 2021 BY QUINTESSENCE PUBLISHING CO, INC. PRINTING OF THIS DOCUMENT IS RESTRICTED TO PERSONAL USE ONLY.
NO PART MAY BE REPRODUCED OR TRANSMITTED IN ANY FORM WITHOUT WRITTEN PERMISSION FROM THE PUBLISHER.

Table 3 Ostectomy Measured on Radiographs in Teeth Restored with Full-Crown or Conservative Restorations

Bone resection class	Full crown, n	Conservative, n	Total, n
< 1 mm	65	28	93
≥ 1, < 2 mm	49	15	64
≥ 2 mm	10	1	11
Total	124	44	168

measurements (radiographic bone resection [RBR]) averaged 1 ± 0.6 mm, which was highly statistically significant ($P < .0001$). An RBR < 2 mm was seen in most cases (93.5%; Table 3). When splitting the population into subgroups by presurgical CM–BC measurements (< 2 mm and ≥ 2 mm), the RBR was significantly greater for CM–BC < 2 mm (1.2 ± 0.7 mm vs 0.7 ± 0.5 mm; $P < .0001$). No difference ($P = .169$) was detected in the amount of RBR between periodontitis patients (0.9 ± 0.7 mm) and healthy/gingivitis patients (1 ± 0.6 mm). Greater RBR was measured in teeth restored with a full crown than in teeth restored with direct/indirect reconstructions (Table 3).

1-Year Clinical Outcomes

At 1 year (Table 2), average FMPS was 13.2% ± 2.5% (range: 7% to 19%) and average FMBS was 7.7% ± 2.9% (range: 1% to 15%). Differences compared to presurgical reevaluation were significant for FMPS ($P = .0002$) but not significant for FMBS ($P = .332$). The average PD was 2.5 ± 0.5 mm, with a PD reduction of 0.7 ± 0.9 mm ($P < .0001$). PD averaged 2.6 ± 0.6 mm in the periodontitis patients and 2.5 ± 0.5 mm in the healthy/gingivitis patients ($P = .198$). BOP was detected in 19 sites (11.3%), of which 3 sites were in periodontitis patients, with a significant reduction with respect to baseline. The average distance between the apical margin of the restoration and the gingival margin was 0.2 ± 0.4 mm (range: 0 to 1 mm). Average CAL was 2.7 ± 0.6 mm.

Discussion

Treatment with minimally invasive crown lengthening (Fig 1) resulted in successful reconstruction and healthy periodontal conditions of 168 teeth at 1 year. Most of the treated teeth presented with very severe destruction of the clinical crown and associated endodontic problems requiring treatment or retreatment and the application of a full crown (Table 1). A very conservative approach was applied to determine the safe distance between the planned cervical margin of the restoration and the periodontal attachment apparatus. To overcome the issue of the ample variability of the supracrestal tissue attachment width,[2,5,12] it was decided to adopt the novel concept of minimal supracrestal tissue attachment width, reducing surgical invasiveness and ostectomy in particular. This concept is supported by studies that show a reduction of the supracrestal dimension after crown lengthening[11,13] and a postsurgical crestal bone remodeling/resorption with exposure of supracrestal fibers after ostectomy and root instrumentation.[10,16] Additionally, the potential to maintain periodontal health when optimal cervical restoration margins are positioned within the gingival sulcus without infringing the attachment apparatus[17–19] is reported in a recent AAP/EFP consensus.[5]

Based on this background, the surgical goal was to reach a minimal supracrestal tissue attachment width of 2.5 mm, including supracrestal connective tissue, junctional epithelium, and a free space between the cervical margin and the bottom of the sulcus. The clinical reference to determine the 2.5-mm space was the coronal portion of the supracrestal connective tissue,[20] not the bone crest, which is reported in most of the published studies.[9–11,13,21,22] Technically, during surgery, the root surface was carefully instrumented for 2 mm apical to the planned cervical margin of the restoration, clearing periodontal fibers and root cementum to allocate the junctional epithelium and a free sulcular space. Root planing was performed without any ostectomy when the bone was at a distance ≥ 2 mm, while bone resection was performed when bone was closer, to reach the 2.0-mm distance from

© 2021 BY QUINTESSENCE PUBLISHING CO, INC. PRINTING OF THIS DOCUMENT IS RESTRICTED TO PERSONAL USE ONLY.
NO PART MAY BE REPRODUCED OR TRANSMITTED IN ANY FORM WITHOUT WRITTEN PERMISSION FROM THE PUBLISHER.

the cervical margin. From a biologic standpoint, about 0.5 mm crestal bone resorption, resulting in fiber exposure, is expected after surgery, in particular when root planing is performed to bone.[10,16] In other words, when bone is 2 mm apical to the cervical margin or resected to reach the 2-mm distance and root planing is performed, a physiologic supracrestal connective tissue attachment apparatus will form apical to the 2 mm of exposed dentin occupied by junctional epithelium and free sulcular space. Careful root planing is mandatory to clear 2 mm of the root surface apical to the cervical margin. Should fibers be left on this area of the root surface, a coronal reattachment and migration of the supracrestal complex has to be expected with the consequent failure of the crown-lengthening procedure.[9] The radiographic measurements reported in the present study confirm the clinical approach. In fact, in the subgroup with a presurgical CM–BC < 2 mm, a significantly greater RBR was measured (1.2 ± 0.7 mm) with respect to the other group (CM–BC ≥ 2 mm; 0.7 ± 0.5 mm). As expected, a greater amount of bone resection was necessary in cases restored with a full crown to allow for the ferrule effect.

Overall, radiographic bone resection was limited to an average of 1 ± 0.6 mm. This minimally invasive approach resulted with most of the cervical margins allocated just within the gingival sulcus but at a safe distance from the junctional epithelium. The 1-year periodontal outcomes show a condition of periodontal health with shallow sulcus at all treated sites and very few BOP-positive results in both the healthy/gingivitis and periodontitis patient groups. It is important to remember that crown lengthening and reconstruction were done after treatment of periodontal diseases, all patients were motivated to home care, and patients were monitored in a supportive periodontal/dental care program that was scheduled according to individual needs.

Conclusions

The use of a minimally invasive crown-lengthening surgery with minimal or no ostectomy followed by high-quality restorations resulted in healthy periodontal and dental conditions of all treated units at the 1-year follow-up. An analysis of cost and time for treatment, an evaluation of patient outcomes, and a long-term re-evaluation of this population will provide further relevant information for clinicians.

Acknowledgments

This study was self-supported by the authors. The authors declare no conflicts of interest.

References

1. Padbury A Jr, Eber R, Wang HL. Interactions between the gingiva and the margin of restorations. J Clin Periodontol 2003;30:379–385.
2. Schmidt JC, Sahrmann P, Weiger R, Schmidlin PR, Walter C. Biologic width dimensions—A systematic review. J Clin Periodontol 2013;40:493–504.
3. Pilalas I, Tsalikis L, Tatakis DN. Prerestorative crown lengthening surgery outcomes: A systematic review. J Clin Periodontol 2016;43:1094–1108.
4. Schätzle M, Land NP, Anerud A, Boysen H, Bürgin W, Löe H. The influence of margins of restorations on the periodontal tissues over 26 years. J Clin Periodontol 2000;27:57–64.
5. Jepsen S, Caton JG, Albandar JM, et al. Periodontal manifestations of systemic diseases and developmental and acquired conditions: Consensus report of workgroup 3 of the 2017 World Workshop on the Classification of Periodontal and Peri-Implant Diseases and Conditions. J Clin Periodontol 2018;89(suppl):s237–s248.
6. Nevins M, Skurow HM. The intracrevicular restorative margin, the biological width, and maintenance of the gingival margin. Int J Periodontics Restorative Dent 1984;4:30–49.
7. Wagenberg BD, Eskow RN, Langer B. Exposing adequate tooth structure for restorative dentistry. Int J Periodontics Restorative Dent 1989;9:322–331.
8. Ingber JS, Rose LF, Coslet JG. The "biological width," a concept in periodontics and restorative dentistry. Alpha Omegan 1997;70:62–65.
9. Pontoriero R, Carnevale G. Surgical crown lengthening: A 12-month clinical wound healing study. J Periodontol 2001;72:841–848.
10. Lanning SK, Waldrop TC, Gunsolley JC, Maynard JG. Surgical crown lengthening: Evaluation of the biological width. J Periodontol 2003;74:468–474.
11. Deas DE, Mackey SA, Sagun RS Jr, Hancock RH, Gruwell SF, Campbell CM. Crown lengthening in the maxillary anterior region: A 6-month prospective clinical study. Int J Periodontics Restorative Dent 2014;34:365–373.
12. Gargiulo AW, Wentz FM, Orban B. Dimensions and relations of the dentogingival junction in humans. J Periodontol 1961;32:261–267.
13. Perez JR, Smukler H, Nunn ME. Clinical evaluation of the supraosseous gingivae before and after crown lengthening. J Periodontol 2007;78:1023–1030.
14. Cortellini P, Tonetti MS. Clinical concepts for regenerative therapy in intrabony defects. Periodontol 2000 2015;68:282–307.

© 2021 BY QUINTESSENCE PUBLISHING CO, INC. PRINTING OF THIS DOCUMENT IS RESTRICTED TO PERSONAL USE ONLY.
NO PART MAY BE REPRODUCED OR TRANSMITTED IN ANY FORM WITHOUT WRITTEN PERMISSION FROM THE PUBLISHER.

15. Cortellini P, Buti J, Pini Prato G, Tonetti MS. Periodontal regeneration compared with access flap surgery in human intra-bony defects 20-year follow-up of a randomized clinical trial: Tooth retention, periodontitis recurrence and costs. J Clin Periodontol 2017;44:58–66.
16. Oakley E, Rhyu IC, Karatzas S, Gandini-Santiago L, Nevins M, Caton J. Formation of the biologic width following crown lengthening in nonhuman primates. Int J Periodontics Restorative Dent 1999;19:529–541.
17. Lang NP, Kiel RA, Anderhalden K. Clinical and microbiological effects of subgingival restorations with overhanging or clinically perfect margins. J Clin Periodontol 1983;10:563–578.
18. Bertoldi C, Zaffe D, Generali L, Lucchi A, Cortellini P, Monari E. Gingival tissue reaction to direct adhesive restoration: A preliminary study. Oral Dis 2018;24:1326–1335.
19. Bertoldi C, Monari E, Cortellini P, et al. Clinical and histological reaction of periodontal tissues to subgingival resin composite restorations. Clin Oral Investig 2020;24:1001–1011.
20. Pini Prato GP, Agudio G, Toffenetti F, Cortellini P, Clauser C. Periodontal treatment associated with conservative therapy of Class V caries: Biological basis and indications [in Italian]. Dent Cadmos 1984;52:9,11–20.
21. Hempton TJ, Dominici JT. Contemporary crown-lengthening therapy: A review. J Am Dent Assoc 2010;141:647–655.
22. Bottacchiari S, De Paoli S, Bottacchiari PA. Biologic restoration: The effects of composite inlays on patient treatment plans. Int J Periodontics Restorative Dent 2011;31:115–123.

© 2021 BY QUINTESSENCE PUBLISHING CO, INC. PRINTING OF THIS DOCUMENT IS RESTRICTED TO PERSONAL USE ONLY.
NO PART MAY BE REPRODUCED OR TRANSMITTED IN ANY FORM WITHOUT WRITTEN PERMISSION FROM THE PUBLISHER.