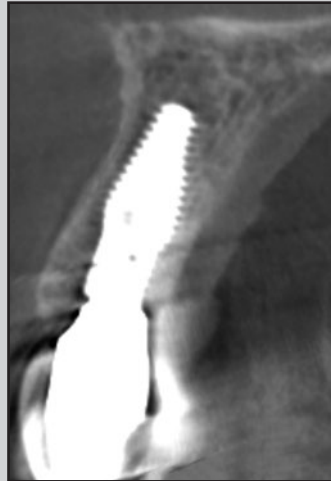
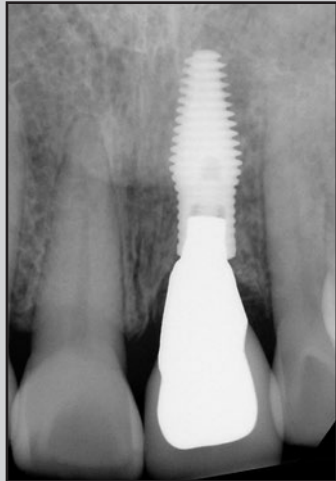
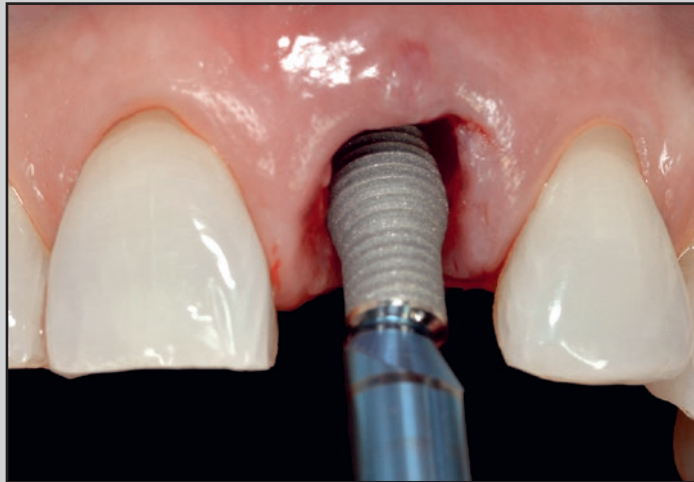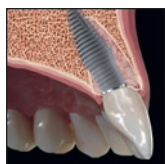Use of a Novel Implant with an Inverted Body-Shift and Prosthetic Angle Correction Design for Immediate Tooth Replacement in the Esthetic Zone: A Clinical Case Series



Stephen J. Chu, DMD, MSD, CDT¹

Barry P. Levin, DMD²

Nicholas Egbert, DDS, MDS³

Hanae Saito, DDS, MS⁴

Myron Nevins, DDS⁵

A clinical case series of three patients is presented using a novel implant design to not only address primary stability but also to prevent damage to the labial bone plate and improve the interdental space for papillae preservation with immediate tooth replacement therapy. This unique implant design features an apicocoronal inverted body-shift in diameter (wide to narrow), shape (tapered to cylindrical), thread depth (deep to shallow), and thread pattern (V-shaped to square) to achieve uncompromised primary stability and esthetics, particularly in extraction sockets, in a singular body form. In addition, the implant possesses a prosthetic angle correction within the implant body to facilitate screw-retention of the restoration and avoid the risk of apical socket perforation. Int J Periodontics Restorative Dent 2021;41:195–204. doi: 10.11607/prd.5401

Although immediate tooth replacement therapy (ITRT) has become a viable treatment, esthetic outcomes remain a challenge in the maxillary anterior region. What is now biologically evident is the need for protection of the facial plate surrounding the implant for long-term maintenance and sustainability.^{1–4} Notwithstanding, achieving primary implant stability in extraction sockets that frequently are compromised with limited bone is critical for initial implant survival and, subsequently, its success. Tapered, wide-diameter implants are commonly used to achieve high levels of stability in immediate extraction sites. This design inherently minimizes the distance between, and the facial proximity to, the implant platform and the extraction socket's thin bony wall (Fig 1). Narrow-diameter implants provide greater space for crestal bone augmentation but lack the level of primary stability needed to support an immediate provisional restoration or final restoration.^{5,6}

A macro-hybrid implant design was created to provide common ground between wider, tapered implants, which increase primary stability, and narrower implants, which provide greater coronal gap space.^{7–12} In a preclinical study, the inverted implant with a body-shift design (INV) with a narrow cylindrical coronal portion 40% of the

¹Ashman Department of Periodontology and Implant Dentistry, Department of Prosthodontics, New York University College of Dentistry, New York, New York; Private Practice, New York, New York, USA.

²Department of Periodontology, University of Pennsylvania School of Dental Medicine, Philadelphia, Pennsylvania; Private Practice, Jenkintown, Pennsylvania, USA.

³Roseman University Dental School, South Jordan, Utah, USA; Private Practice, Salt Lake City, Utah, USA.

⁴Division of Periodontics, University of Maryland School of Dentistry, Baltimore, Maryland, USA.

⁵Department of Oral Medicine, Infection, and Immunity, Division of Periodontology, Harvard School of Dental Medicine, Boston, Massachusetts, USA.

Correspondence to: Dr Stephen J. Chu, 150 East 58th St, New York, NY 10155, USA.
Email: schudmd@gmail.com

Submitted August 25, 2020; accepted August 28, 2020.

©2021 by Quintessence Publishing Co Inc.

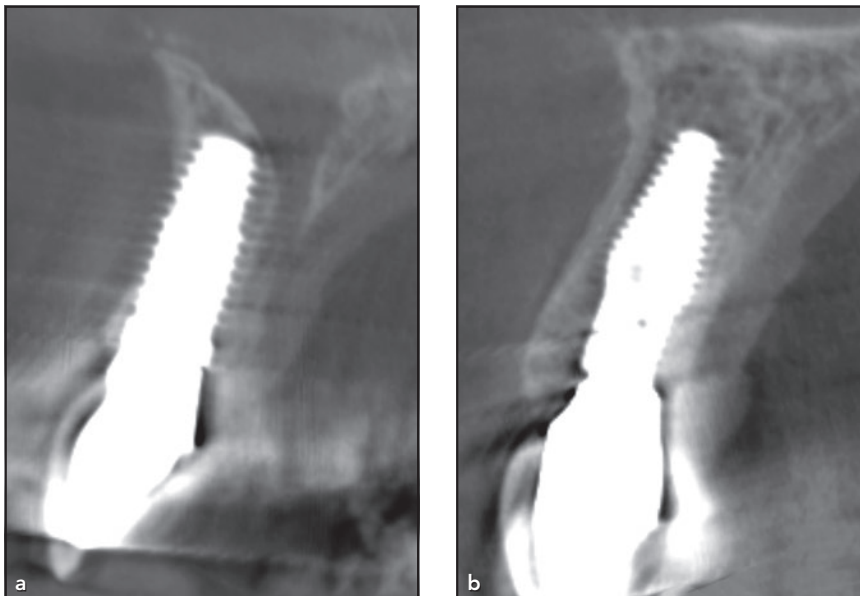


Fig 1 CBCT scans of (a) a tapered conventional implant and (b) an inverted body-shift (INV) implant placed into extraction sockets at 1 year of healing. The reformed labial plate dimension on the tapered implant is less than that of the INV implant.

length of the implant body allowed for extremely high primary stability (mean: 90 Ncm) but also a significant crestal gap distance from the surrounding socket walls, which predictably achieved osseointegration without internal grafting.⁷ Clinically, this gap space allows the addition of hard tissue biomaterial to augment the labial plate at the time of ITRT. Further, the reduced coronal diameter and cylindrical shape provides unobstructed seating of provisional restorative components. This implant has a subcrestal (prosthetic) angle correction (SAC) feature that permits implant placement along the long axis of the adjacent teeth coincident with the incisal edge position. This enables the implant to engage with an optimal amount of apicopalatal bone for stability while consistently delivering palatal access for screw-retained restorations,

without compromising esthetics.^{13,14} An added benefit of SAC is that the implant-abutment interface or platform is variable in dimension, with the greatest amount at the direct facial aspect. This design is known as variable platform switching (VPS). Strategically, combining properties of different implant concepts into a singular body—thus creating a hybrid implant with a wider, tapered apical aspect and a narrower, cylindrical coronal aspect—with SAC and VPS affords clinicians both short and potentially long-term advantages that have not been seen with other implant designs.

The present clinical case reports demonstrate multiple benefits of this INV design in ITRT, including high levels of primary stability, enhancement of the thin facial bone plate demonstrated on CBCT radiographs, and increased tooth-to-

implant distance for papillae maintenance while facilitating prosthetic screw-retention of provisional and definitive restorations.

Clinical Case Reports

Case 1

A 62-year-old Asian woman presented with vertical crown and root fracture of the maxillary left central incisor (Fig 2). Prior dental history of the incisor included progressive pulp atrophy due to a mild traumatic injury, treated with endodontic therapy and nonvital internal bleaching. The patient was given pretreatment antibiotics (2 g amoxicillin) 1 hour before treatment. The tooth was removed atraumatically without flap elevation, and thorough socket debridement was performed. The incisal-edge position was used as a point of reference when creating a precise osteotomy at the apicopalatal aspect of the socket. The osteotomy was sized to receive an INV implant that was 13.0 mm long and 4.5 mm in diameter at the apical portion (which comprised roughly 50% of the total implant length), with a 3.5-mm coronal cylindrical portion (comprising about 40% of the total implant length), as well as SAC and VPS features (INVERTA Co-Axis, Southern Implants) to ensure a screw-retained restoration. This co-axial design allows the surgeon to make the osteotomy behind the apex of the tooth root, thus engaging the maximum amount of available apicopalatal bone and avoiding apical perfora-

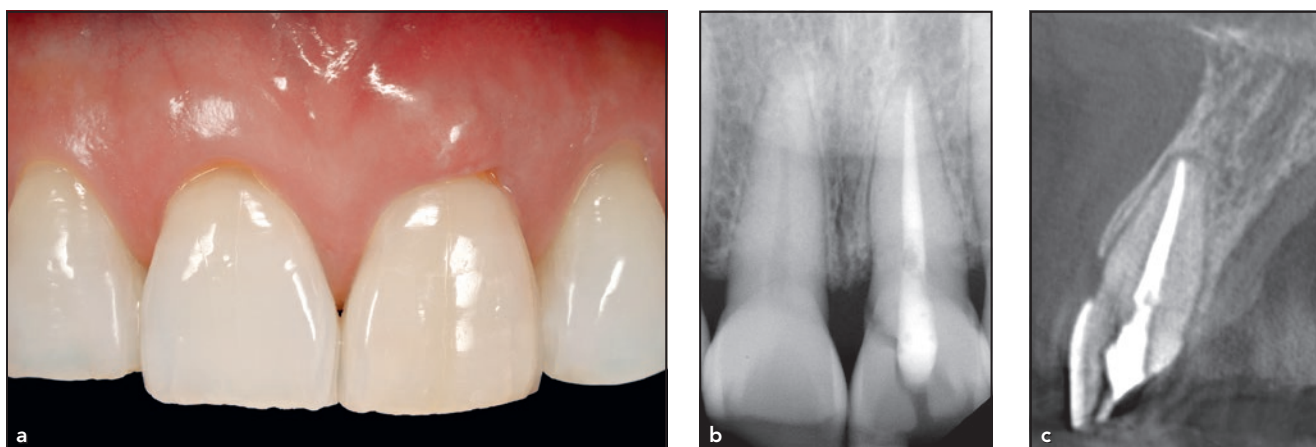


Fig 2 Case 1. (a) Facial view of the maxillary left central incisor with a vertical crown, root fracture, and a periodontal abscess at the free gingival margin. The sounding depth was 4.5 mm to the bone crest, indicative of 1.5 mm of bone loss. (b) Periapical and (c) CBCT radiographs show a subosseous root fracture on both the facial and palatal aspects.

tion of the labial bone plate (Fig 3).¹⁵ Because the bone quality was soft (D3¹⁶), the osteotomy site was underprepared by 0.75 mm, and an insertion torque value of 80 Ncm was achieved at placement. Prior to grafting the gap, a preformed gingival former (iShell, Vulcan Custom Dental) was used to help fabricate a screw-retained acrylic provisional restoration attached to polyether ether keytone (PEEK) with a full labial restorative contour to support the peri-implant soft tissues. A healing abutment was used to protect the screw access hole and to allow a small-particle mineralized cancellous allograft (MinerOss, BioHorizons) to be placed in the bone and in soft tissue zones (dual-zone therapeutic concept; Fig 4).¹⁷

Excess biomaterial was removed following reinsertion of the provisional restoration to contain and protect the graft material during the initial healing phase. The restoration was reevaluated for nonocclusal contact in the maximum intercuspal

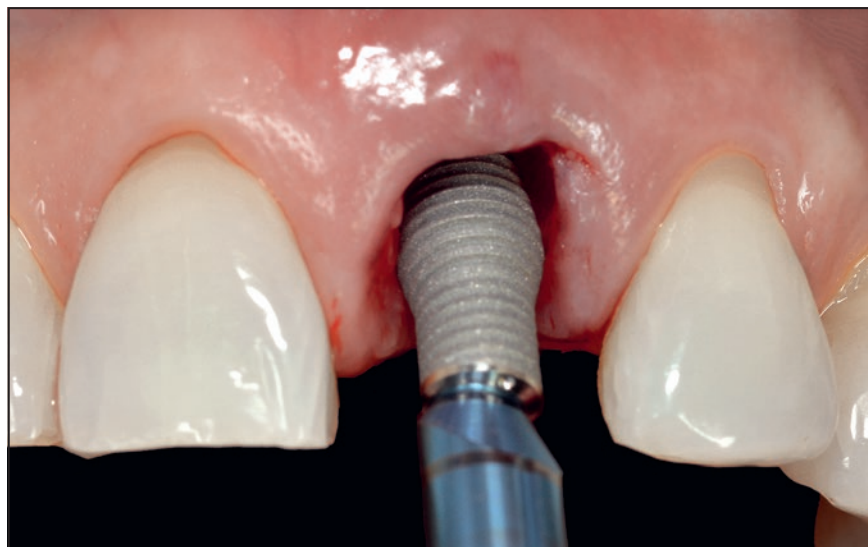


Fig 3 Case 1. After flapless tooth removal, thorough socket debridement, and the osteotomy, the implant mount's depth marker denotes 3.0 mm from the free gingival margin and an orientation groove that should be position facially once the implant is correctly seated. This co-axial design allows the surgeon to make the osteotomy behind the apex of the tooth root, thus avoiding perforation of the labial bone plate. The prosthetic screw access should face the direct palatal aspect of the carrier, then the mount can be unscrewed and removed. The implant was delivered with an insertion torque value of 80 Ncm.

position and during lateral excursion movements. The patient continued the antibiotic regiment for 1 week posttreatment and was instructed to not brush the surgical site for 5 to 7 days. The implant was allowed

to heal for a full 5 months prior to first removal of the provisional restoration and final impression-making (Figs 5 and 6). A metal-ceramic screw-retained implant crown was fabricated and delivered

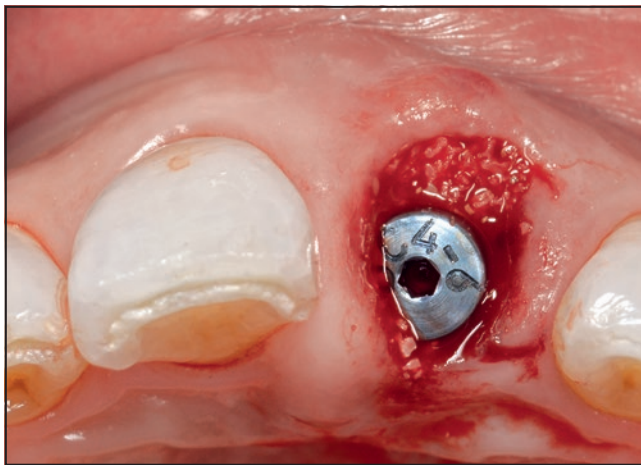


Fig 4 Case 1. After the provisional restoration is made, a healing abutment is placed on the implant to allow grafting and to prevent biomaterial from blocking the screw access channel. Graft material is placed circumferentially around the healing abutment.

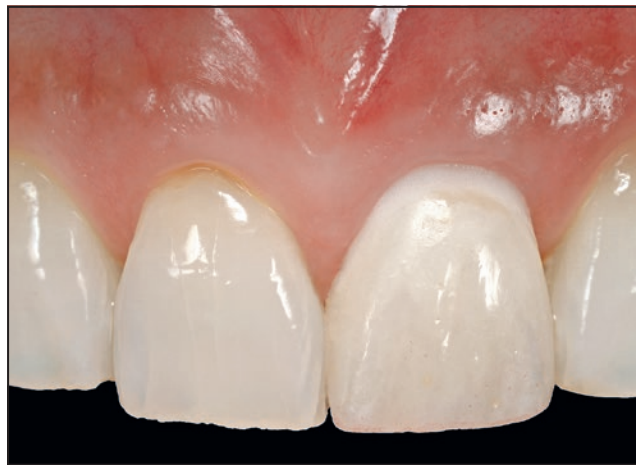

Fig 5 Case 1. The provisional restoration was allowed to heal for 5 months prior to first disconnection and impression-making. Note the resolved periodontal abscess and the preservation of the ridge contour, shape, and papillae.

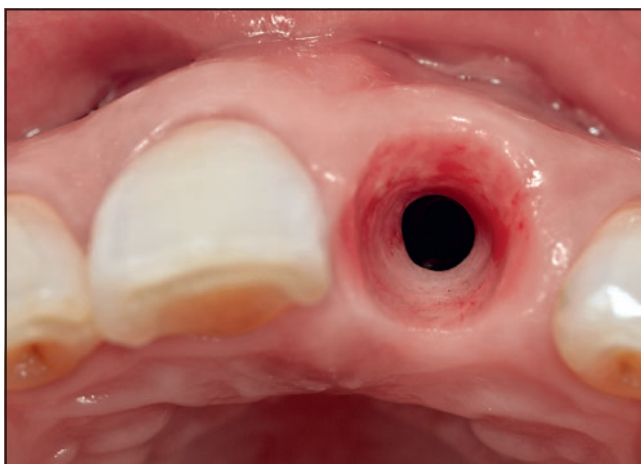


Fig 6 Case 1. Healthy peri-implant soft tissues can be seen at crown delivery. The ridge dimension was preserved, and the peri-implant soft tissues were enhanced using the dual-zone grafting technique.

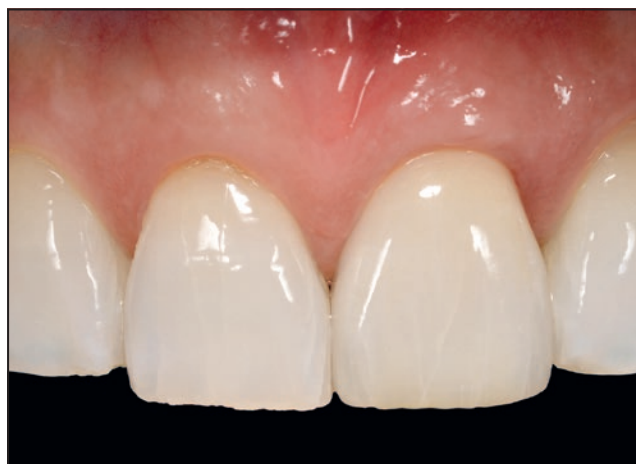

Fig 7 Case 1. The final metal-ceramic screw-retained restoration intraorally with satisfactory esthetic integration. The Pink Esthetic Score was 13, as there was a slight change in ridge shape due to the preoperative infection, as seen in Fig 6.

2 to 3 months after impression-making (Fig 7). At the 1-year follow-up, postsurgical periapical and CBCT radiographs were taken, showing a 1.0-mm gain in crestal bone height above the implant platform, a bone plate thickness of 3.1 mm at the implant-abutment interface, and a tooth-to-implant distance of 2.0 mm (Fig 8). Even though the patient has

an average midfacial smile line, the preservation of the interdental papillae, utilization of the dual-zone technique in combination with the hybrid implant design, and shade integration with the adjacent natural teeth resulted in a pleasing esthetic outcome (Fig 9). The Pink Esthetic Score¹⁸ was evaluated, with the final outcome scoring 13 out of 14.

Case 2

The patient was a 51-year-old woman with a history of prior endodontic treatment on the maxillary left central incisor. Other than slight discoloration (Fig 10a), the patient had been asymptomatic for over 10 years before a complaint of recent discomfort arose. The mesiobuccal location

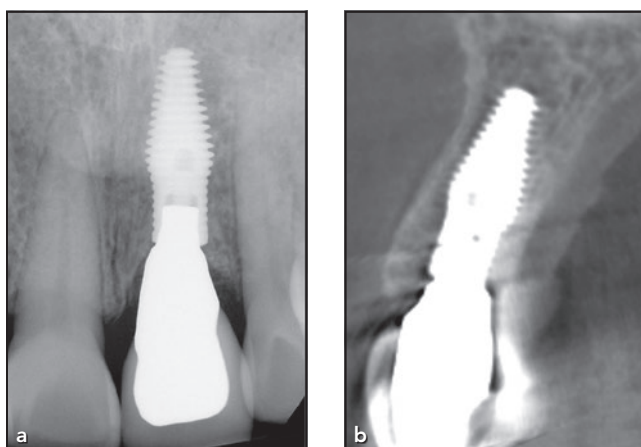


Fig 8 Case 1. (a) Periapical and (b) CBCT scans at 1 year show a labial bone plate thickness averaging > 2.0 mm (range: 2.3 to 3.1 mm), as well as a 2.0-mm tooth-to-implant distance.

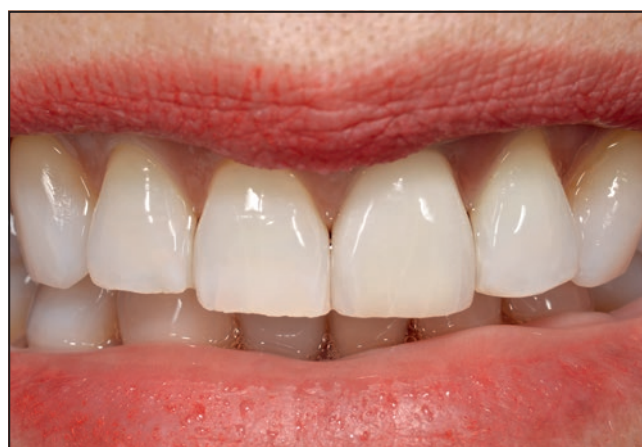

Fig 9 Case 1. The patient's smile at 1 year posttreatment demonstrates papillae maintenance and pleasing shade-blending with the patient's natural dentition.

had recently developed a 7.0-mm probing depth. A root fracture was suspected on CBCT scans, and immediate implant placement with a provisional restoration was recommended (Fig 10b).

Following flapless tooth extraction and debridement of the residual socket, a 5.0/4.0 \times 15.0-mm INV implant with a 12-degree SAC was placed, securing the apico-palatal bone, with the long axis emerging through the incisal edge of the surgical guide. The insertion torque required to fully seat the implant was 70 Ncm, and implant stability quotient (ISQ) values were 70 (buccal) and 74 (palatal), confirming high primary stability. Dual-zone bone grafting with a corticocancellous mixture of mineralized bone allograft (Symbios, Dentsply Sirona; particle size 250 to 750 microns) was performed prior to placing a screw-retained temporary crown without occlusal contact. After 3 months of healing, the provisional crown was disconnected for the

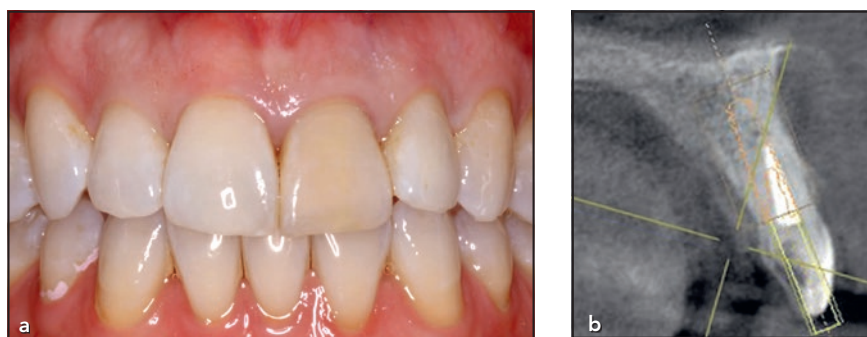


Fig 10 Case 2. (a) Pretreatment condition of the maxillary left central incisor that had previous endodontic therapy and tooth discoloration. A 7.0 mm mesiobuccal probing depth was measured. (b) A cross-section of a CBCT scan taken before treatment shows root fracture and the facial root position with minimal labial plate dimension.

first time for impression-making, and the follow-up ISQ values were 74 for both facial and palatal aspects, confirming secondary stability or osseointegration. The patient was then referred back to her restorative dentist for definitive restorative treatment where she received a screw-retained crown (Fig 11a). CBCT scans at 1 year post-treatment revealed a range in labial plate thickness of 2.2 to 2.75 mm (Fig 11b).

Case 3

A 64-year-old woman presented with chronic gingival inflammation in her maxillary anterior sextant with recent discomfort and severe swelling on the facial aspect of the left central incisor (Fig 12a). A root fracture was strongly suspected on periapical and CBCT radiographs (Fig 12b). Prior to ITRT, laser-assisted, nonsurgical debridement was performed with an erbium:YAG laser to reduce

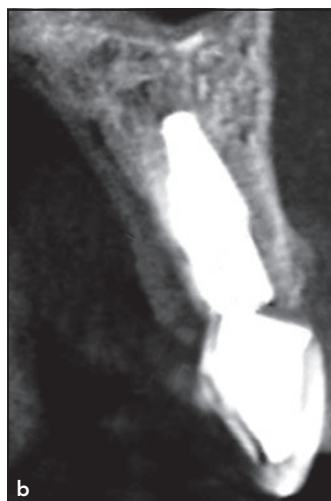
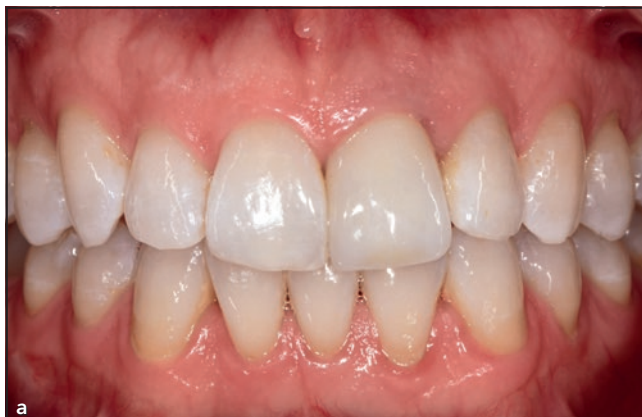
Fig 11 Case 2. (a) The final restoration was an all-ceramic screw-retained crown delivered about 6 months following implant placement. (b) A cross-sectional CBCT scan taken 16 months after surgery shows adequate reconstruction (range: 2.2 to 2.8 mm) of the labial bone plate.

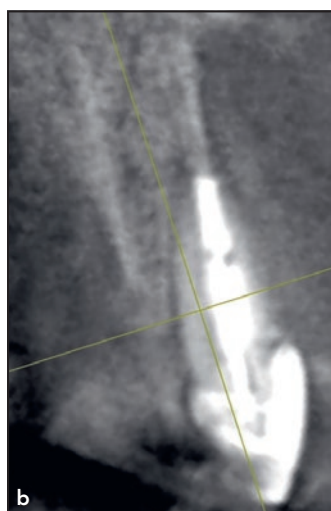
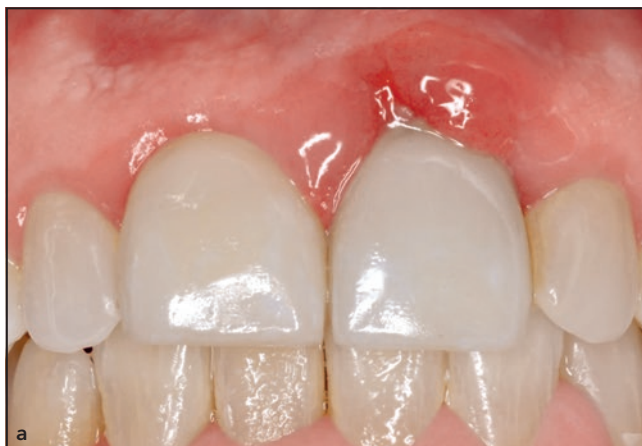
Fig 12 Case 3. (a) Facial view of a patient who presented with significant marginal gingival inflammation around the facial aspect of the maxillary left central incisor. The 9.0-mm probing depth indicated a vertical root fracture and a dentoalveolar dehiscence defect. (b) Cross-sectional view of a pretreatment CBCT scan shows the absence of facial bone.

inflammation and bacterial load at the site, and the patient returned 1 week later for immediate tooth replacement. Following atraumatic extraction and thorough debridement, a sterile gauze square saturated with a mixture of doxycycline and sterile saline was placed for 3 minutes, followed by irrigation with sterile saline. The facial socket wall possessed a dentoalveolar dehiscence defect of 9.0 mm. A 4.5/3.5 × 15.0 mm INV implant with a 12-degree co-axis prosthetic connection was placed

with an insertion torque of 75 Ncm and ISQ values of 72 both facially and palatally. Dual-zone bone grafting was performed using a composite graft consisting of a 4:1 ratio of cortical, mineralized bone allograft (Symbios, Dentsply Sirona) and xenograft (ZenGro, Southern Implants). A screw-retained provisional crown was fabricated on a PEEK temporary abutment and a dermal allograft (thickness: 0.4 to 0.8 mm) and was adapted around the provisional crown (Fig 13).^{3,19} At about 3 months

posttreatment, the provisional crown was disconnected for the first time, and the ISQ values were taken; they increased slightly to 74 facially and 75 palatally. The patient returned to the general dentist for definitive restorative treatment, and a screw-retained metal-ceramic crown was delivered 5 to 6 months after ITRT. Five weeks after delivery of the final crown and 6 to 7 months postsurgery, a CBCT scan revealed a facial bone thickness over 2.0 mm and crestal height coronal to the facial implant platform

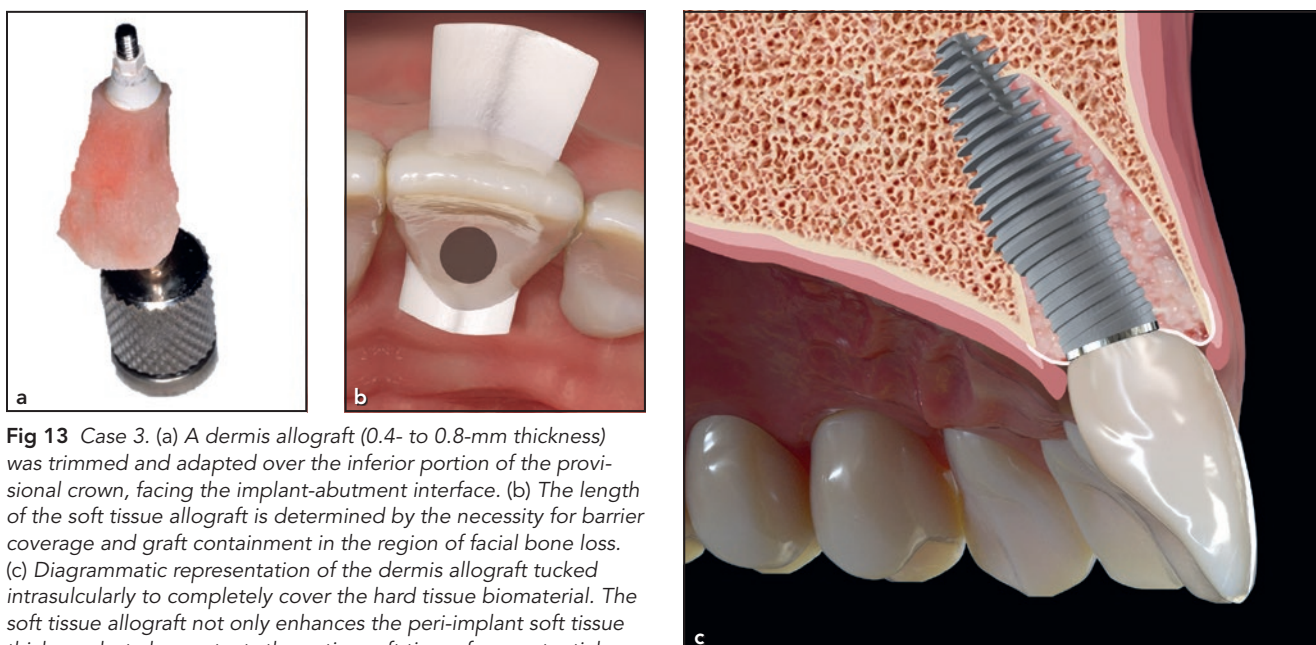
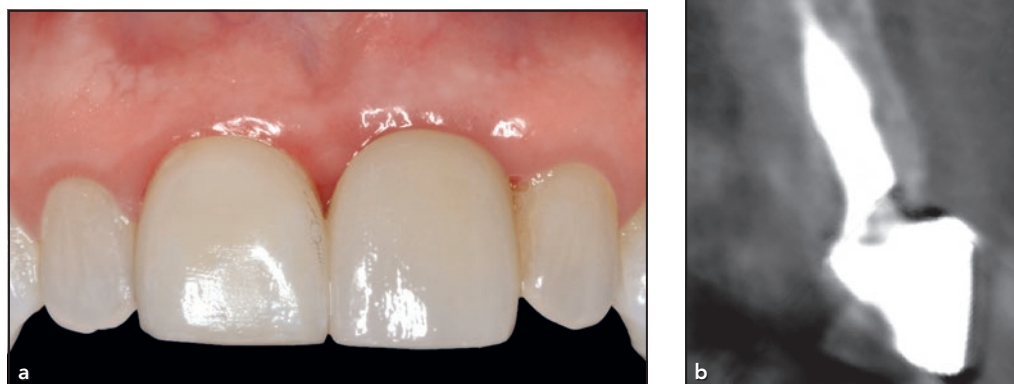

Fig 13 Case 3. (a) A dermis allograft (0.4- to 0.8-mm thickness) was trimmed and adapted over the inferior portion of the provisional crown, facing the implant-abutment interface. (b) The length of the soft tissue allograft is determined by the necessity for barrier coverage and graft containment in the region of facial bone loss. (c) Diagrammatic representation of the dermis allograft tucked intrasulcularly to completely cover the hard tissue biomaterial. The soft tissue allograft not only enhances the peri-implant soft tissue thickness but also protects the native soft tissue from potential irritation from the cortical bone graft particles.

Fig 14 Case 3. (a) The patient received a screw-retained crown, with soft tissue topography harmonious with the adjacent central incisor, 6.5 months after surgery. (b) Five weeks after delivery of the final crown and 6 to 7 months postsurgery, a facial bone thickness > 2.0 mm (range: 2.3 to 2.7 mm) and height coronal to the implant platform were present where no bone had previously existed.



where there had not been any at the time of surgery (Fig 14).

Discussion

Table 1 demonstrates 10 critical steps associated with the surgical

and prosthetic procedures to optimize the unique characteristics of this hybrid implant and its applications in ITRT. With a novel hybrid-designed implant, conventional parameters regarding placement for prosthetic screw retention, primary stability, and coronal gap distance, especially

in compromised extraction sockets, are redefined.

Respecting the biology of bone, peri-implant tissues, and the impact of their violation(s) is critical for long-term stability.^{20,21} The traditional tapered implant used for ITRT can compromise outcomes in several

Table 1 Clinical Keys in Immediate Tooth Replacement

Flapless minimally invasive tooth extraction
Site preparation with incisal edge orientation and prosthetic angle correction
Osteotomy extended 1.0 mm beyond the intended implant length
Underprepared implant diameter in soft bone
Implant placement 3.0–4.0 mm from the midfacial free gingival margin
Facial gap distance > 2.0 mm
Maintained tooth-to-implant distance > 1.5 mm between the implant and the adjacent teeth
Grafting with a slowly resorbing biomaterial adjacent to the labial bone plate and a faster resorbing material in the soft tissue zone
Tighten implant mount carrier screw before manual complete seating
Absolutely no disconnecting the provisional restoration for at least 3–4 mo postsurgery

ways, as those implants are wider in the coronal region where the bone dimension is the most minimal and can be damaged. A narrow coronal portion provides space for enhancement of the buccal plate.²² Proximity of the implant platform to the facial bone can result in excessive horizontal and vertical bone loss as extraction socket modeling and remodeling occur.^{23–26} If the implant-tooth distance is smaller when tapered implants are placed, it can affect the level of papilla height.^{12,27,28} Allowing more space for augmentation of hard and soft tissues requires a narrower implant diameter at the socket's crest and apex. In edentulous sites, this is frequently an acceptable solution; however, in immediate extraction situations where primary stability is attributed to apical and palatal bone, narrow implants are often insufficient to establish satisfactory primary stability for provisional restoration, which is important for

ridge preservation and minimizing long-term recession.²⁹ For this reason and the shortcomings already mentioned, wider, tapered implants are used for ITRT. A hybrid implant design with a wider, tapered apical portion that is 50% of the implant body's length can achieve the desired levels of primary stability for immediate temporization, with the narrower cylindrical coronal half providing the above-mentioned advantages, including a larger socket gap. Maintaining greater distance to proximal root surfaces and the thin facial plate provides a better opportunity for bone preservation, augmentation, and soft tissue thickness. By facilitating a 2.0-mm facial bone thickness, a stable, more vascular support is created longitudinally for hard and soft tissue.⁹ Avoiding mucosal recession post-treatment is a parameter for long-term esthetic success but requires a thicker labial plate to secure the blood supply.³⁰ From a biologic

perspective, this novel implant design features clear advantages over traditional implants and circumvents potential damage to the labial plate and its associated long-term consequences. The preservation of circumferential bone at least 1.5 to 2.0 mm thick at the crestal level validates its use in challenging esthetic zones for immediate tooth replacement therapy.²¹

The added feature of a 12-degree SAC facilitates a facial insertion angle that engages optimal apicopalatal bone, thereby eluding perforation of the facial wall at the root apex and allowing screw-retention of the restorations.^{15,31–34}

These three clinical case series demonstrate the successful use of a hybrid implant, exploiting its wider, tapered apical half to achieve increased primary stability and using its narrower cylindrical coronal half to favor the biologic factors of postextraction socket modeling and remodeling.

Conclusions

ITRT has become a practical treatment option for patients, and improvements in implant design can now allow for more consistent esthetic outcomes. By changing the macrogeometry of the implant body, various treatment needs can be strategically addressed. The three cases presented herein embody the versatile clinical applications of a novel hybrid design, even in challenging scenarios, to achieve adequate primary stability for immediate provisional restorations, labial plate dimension, tooth-to-implant distance, and ultimately consistent Pink Esthetic Scores¹² for patient and clinician success.

Acknowledgments

Special thanks to Dr Guido O. Sarnachiaro (New York, NY) for the surgical treatment of case 1, Dr Hal Rosenthaler (Philadelphia, PA) for the restorative dentistry of case 2, and Dr Brian Wilk (Chalfont, PA) for the restorative treatment shown in case 3. No financial support was received for this manuscript. Dr Chu is a consultant for Southern Implants. The remaining authors declare no conflicts of interest.

References

1. Tarnow DP, Chu SJ, Salama MA, et al. Flapless postextraction socket implant placement in the esthetic zone: Part 1. The effect of bone grafting and/or provisional restoration on facial-palatal ridge dimensional change—A retrospective cohort study. *Int J Periodontics Restorative Dent* 2014;34:323–331.
2. Chu SJ, Salama MA, Garber DA, et al. Flapless postextraction socket implant placement, part 2: The effects of bone grafting and provisional restoration on peri-implant soft tissue height and thickness—A retrospective study. *Int J Periodontics Restorative Dent* 2015;35:803–809.
3. Levin BP. The dermal apron technique for immediate implant socket management: A novel technique. *J Esthet Restor Dent* 2016;28:18–28.
4. Levin BP, Chu SJ. Changes in peri-implant soft tissue thickness with bone grafting and dermis allograft: A case series of 15 consecutive patients. *Int J Periodontics Restorative Dent* 2018;38:719–727.
5. Bilhan H, Geckili O, Mumcu E, et al. Influence of surgical technique, implant shape and diameter on the primary stability in cancellous bone. *J Oral Rehabil* 2010;37:900–907.
6. Gamborena I, Blatz M, et al. The all-at-once concept: Immediate implant placement into fresh extraction sockets with final crown delivery. In: Duarte S Jr (ed). *Quintessence Dent Technol* 2019;42:2–15.
7. Nevins M, Chu SJ, Jang W, Kim DM. Evaluation of an innovative hybrid macrogeometry dental implant in immediate extraction sockets: A histomorphometric pilot study in foxhound dog. *Int J Periodontics Restorative Dent* 2019;39:29–37.
8. Chu SJ, Östman PO, Saito H, et al. Prospective multicenter clinical cohort study of a novel macro hybrid implant in maxillary anterior postextraction sockets: 1-year results. *Int J Periodontics Restorative Dent* 2018;38(suppl):s17–s27.
9. Östman PO, Chu SJ, Drago C, Saito H, Nevins M. Clinical outcomes of maxillary anterior postextraction socket implants with immediate provisional restorations using a novel macro-hybrid implant design: An 18- to 24-month single-cohort prospective study. *Int J Periodontics Restorative Dent* 2020;40:355–363.
10. Chu SJ, Tan-Chu JHP, Levin BP, Sarnachiaro GO, Lyssova V, Tarnow DP. A paradigm change in macro implant concept: Inverted body-shift design for extraction sockets in the esthetic zone. *Compend Contin Educ Dent* 2019;40:444–452.
11. Christiaens V, Pitman J, Glibert M, Hommez G, Atashkadeh M, De Bruyn H. Rationale for a reverse tapered body-shift implant for immediate placement. *Int J Oral Maxillofac Surg* 2020;S0901-5027(20)30136-3.
12. Chu SJ, Tan-Chu JHP, Saito H, Östman PO, Levin BP, Tarnow DP. Tapered versus inverted body-shift implants placed into anterior postextraction sockets: A retrospective comparative study. *Compend Contin Educ Dent* 2020;41:e1–e10.
13. Howes D. Angled implant design to accommodate screw-retained implant-supported prostheses. *Compend Contin Educ Dent* 2017;38:458–463.
14. Boyes-Varley JG, Howes DG, Davidge-Pitts KD, Brånemark I, McAlpine JA. A protocol for maxillary reconstruction following oncology resection using zygomatic implants. *Int J Prosthodont* 2007;20:521–531.
15. Sung CE, Cochran DL, Cheng WC, et al. Preoperative assessment of labial bone perforation for virtual immediate implant surgery in the maxillary esthetic zone. A computer simulation study. *J Am Dent Assoc* 2015;146:808–819.
16. Lekholm U, Zarb GA. Patient selection and preparation. In: Brånemark PI, Zarb GA, Albrektsson T (eds). *Tissue-Integrated Prostheses: Osseointegration in Clinical Dentistry*. Chicago: Quintessence, 1985:199–209.
17. Chu SJ, Salama MA, Salama H, et al. The dual-zone therapeutic concept of managing immediate implant placement and provisional restoration in anterior extraction sockets. *Compend Contin Educ Dent* 2012;33:524–532.
18. Fürhauser R, Florescu D, Benesch T, Haas R, Mailath G, Watzek G. Evaluation of soft tissue around single-tooth implant crowns: The Pink Esthetic Score. *Clin Oral Implants Res* 2005;16:639–644.
19. Levin BP, Saito H, Reynolds MA, Chu SJ. Changes in peri-implant soft tissue thickness with bone grafting and dermis allograft. Part II: A comparative retrospective case series using a subcrestal angle correction implant design. *Int J Periodontics Restorative Dent* 2020;40:539–547.
20. Spray JR, Black CG, Morris HF, Ochi S. The influence of bone thickness on facial marginal bone response: Stage 1 placement through stage 2 uncovering. *Ann Periodontol* 2000;5:119–128.
21. Chappuis V, Rahman L, Buser R, Janner SFM, Belser UC, Buser D. Long-term effectiveness of contour augmentation with guided bone regeneration: 10-year results. *J Dent Res* 2018;97:266–274.

22. Pluemsakunthai W, Le B, Kasugai S. Effect of buccal gap distance on alveolar ridge alteration after immediate implant placement: A microcomputed tomographic and morphometric analysis in dogs. *Implant Dent* 2015;24:70–76.
23. Schropp L, Wenzel A, Kostopoulos L, Karring T. Bone healing and soft tissue contour changes following single-tooth extraction: A clinical and radiographic 12-month prospective study. *Int J Periodontics Restorative Dent* 2003;23:313–323.
24. Nevins M, Camelo M, De Paoli S, et al. A study of the fate of the buccal wall of extraction sockets of teeth with prominent roots. *Int J Periodontics Restorative Dent* 2006;26:19–29.
25. Ferrus J, Cecchinato D, Pjetursson EB, Lang NP, Sanz M, Lindhe J. Factors influencing ridge alterations following immediate implant placement into extraction sockets. *Clin Oral Implants Res* 2010;21:22–29.
26. Choquet V, Hermans M, Adriaenssens P, Daelemans P, Tarnow DP, Malevez C. Clinical and radiographic evaluation of the papilla level adjacent to single-tooth dental implants. A retrospective study in the maxillary anterior region. *J Periodontol* 2001;72:1364–1371.
27. Ducommun J, Bornstein MM, Wong MCM, von Arx T. Distances of root apices to adjacent anatomical structures in the anterior maxilla: An analysis using cone beam computed tomography. *Clin Oral Investig* 2019;23:2253–2263.
28. Esposito M, Ekstrubbe A, Gröndahl K. Radiological evaluation of marginal bone loss at tooth sites facing single Brånemark implants. *Clin Oral Implants Res* 1993;4:151–157.
29. Crespi R, Capparé P, Crespi G, Gastaldi G, Romanos GE, Gherlone E. Tissue remodeling in immediate versus delayed prosthetic restoration in fresh socket implants in the esthetic zone. *Int J Periodontics Restorative Dent* 2018;38(suppl):s97–s103.
30. Januário AL, Duarte WR, Barriviera M, Mesti JC, Araújo MG, Lindhe J. Dimension of the facial bone wall in the anterior maxilla: A cone-beam computed tomography study. *Clin Oral Implants Res* 2011;22:1168–1171.
31. Ganz SD. Using interactive technology: In the zone with the triangle of bone. *Dent Implantol Update* 2008;19:33–38.
32. Kan JY, Roe P, Rungcharassaeng K, et al. Classification of sagittal root position in relation to the maxillary anterior osseous housing for immediate implant placement: A cone beam computed tomography study. *Int J Oral Maxillofac Implants* 2011;26:873–876.
33. Lau SL, Chow J, Li W, Chow LK. Classification of maxillary central incisors—Implications for immediate implant in the esthetic zone. *J Oral Maxillofac Surg* 2011;69:142–153.
34. Gluckman H, Pontes CC, Du Toit J. Radial plane tooth position and bone wall dimensions in the anterior maxilla: A CBCT classification for immediate implant placement. *J Prosthet Dent* 2018;120:50–56.