



# Full-Arch Implant-Supported Rehabilitation Guided by a Predicted Lateral Profile of Soft Tissue

Jingjing Shao, MDS <sup>1,2</sup>, Chaoran Xue, DDS, PhD, MDS,<sup>1,3</sup> Hai Zhang, DMD, PhD, FACP,<sup>4</sup> & Lei Li, PhD, MDS <sup>1,2</sup>

<sup>1</sup>State Key Laboratory of Oral Diseases, National Clinical Research Center for Oral Diseases, West China Hospital of Stomatology, Chengdu, China

<sup>2</sup>Department of Oral Prosthodontics, West China Hospital of Stomatology, Sichuan University, Chengdu, Sichuan, China

<sup>3</sup>Department of Oral Orthodontics, West China Hospital of Stomatology, Sichuan University, Chengdu, Sichuan, China

<sup>4</sup>Department of Restorative Dentistry, School of Dentistry, University of Washington, Seattle, WA

## Keywords

Full-arch rehabilitation; implant-supported prosthesis; predicted soft tissue.

## Correspondence

Lei Li, Department of Oral Prosthodontics, West China Hospital of Stomatology, Sichuan University, No 14, Sec.3, Renminnan Road, Chengdu 610041, PR of China.  
E-mail: leelei@scu.edu.cn

Report supported in part by National Natural Science Fund, grant #81300857.

*The authors deny any conflicts of interest in regards to the current study.*

Authors Jingjing Shao and Chaoran Xue contributed equally to this article.

Accepted June 7, 2019

doi: 10.1111/jopr.13094

## Abstract

In full-arch implant-supported rehabilitation of patients with severe periodontitis, prediction of lateral facial profile with modified dental position remains a challenge, especially for patients with protruded anterior teeth. This clinical report describes a digital workflow to predict lateral profiles and then guide the implant placement and restoration fabrication.

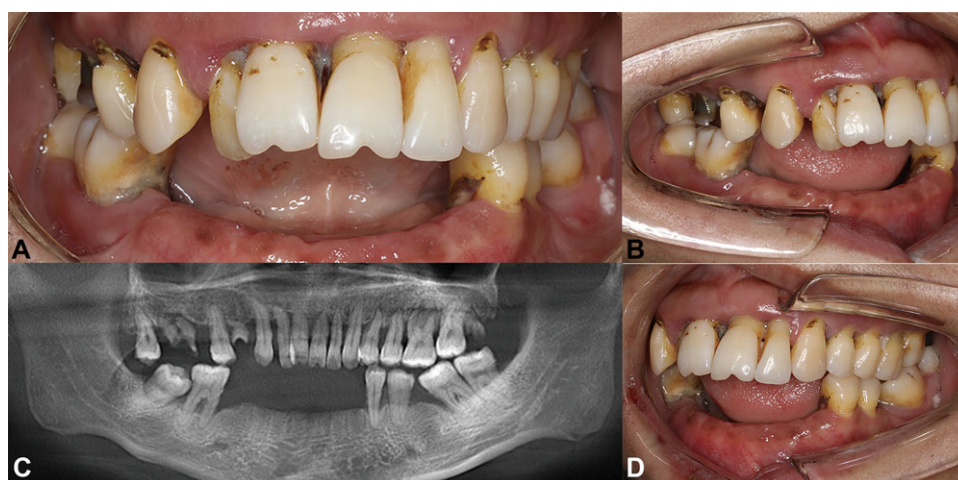
Implant-supported fixed dental prostheses (FDPs) have been used for full-mouth rehabilitation for decades. Virtual planning and performing treatments using computer-aided design and computer-aided manufacture (CAD/CAM) have been reported in full-arch implant-supported rehabilitation.<sup>1</sup> Digital smile design technologies are popular in designing the smile from facial references and communication between the interdisciplinary team and patient.<sup>2</sup> In the anterior part of full-arch restorations, treatment plans can be designed using digital smile design to obtain esthetic results; however, the 3D lip profile cannot be changed accordingly in current digital design methods with modifications of tooth shape and arrangement.<sup>3</sup> For patients with edentulous arches, the complete denture serves as a diagnostic treatment plan tool, which helps to evaluate soft tissue profile.<sup>4</sup> In full-arch implant-supported rehabilitation of patients with severe periodontitis, communication with patients about lateral facial profile with modified dental position remains a challenge, especially for patients with protruded anterior teeth. Dolphin Imaging offers patient education modules including an orthodontic, dental, and surgical preview, so

patients can see the results of treatments. In this clinical report, lateral profiles were predicted using the Dolphin software, and then implant placement and restoration fabrication were guided by predicted and planned dental positions.

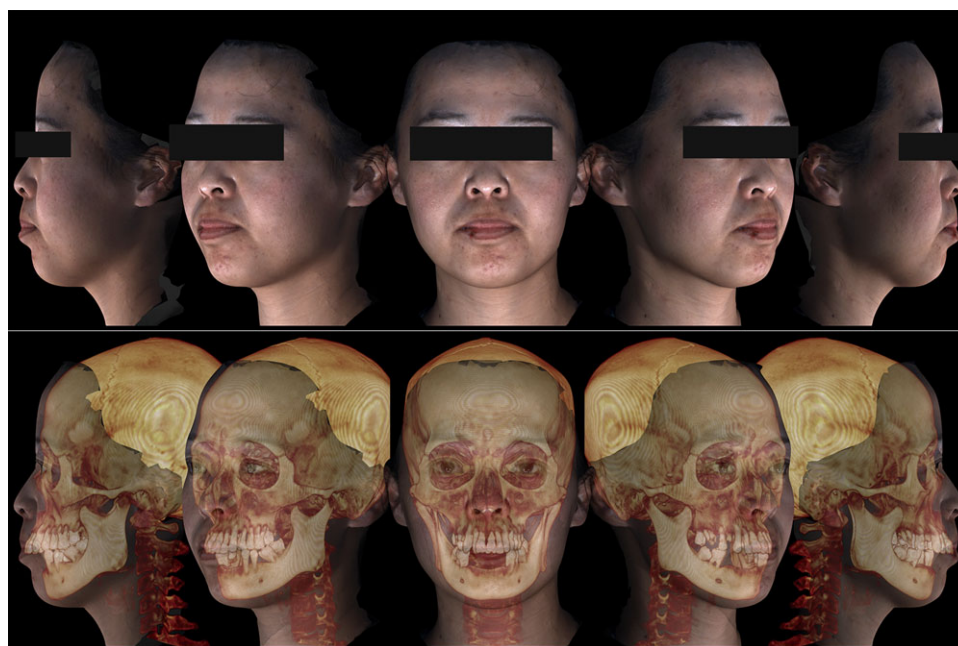## Clinical report

A 36-year-old woman was referred to the prosthodontics department complaining of mobile teeth and poor masticatory function. In addition, she complained that the lateral profile of her lower face was protruded, and she asked for improvement. She also wanted immediate restorations for function and esthetics.

The patient was systemically healthy with no relevant medical history. There was no family history of similar complaints or early tooth loss. Routine blood test results were within normal limits. Extraoral examination did not indicate any abnormalities. Intraoral examination showed poor oral hygiene. On periodontal probing, there were deep periodontal pockets ranging from 5.0 to 12.0 mm in the majority



**Figure 1** Pretreatment views and panoramic radiograph.




**Figure 2** Fusion of CT and facial 3D images.

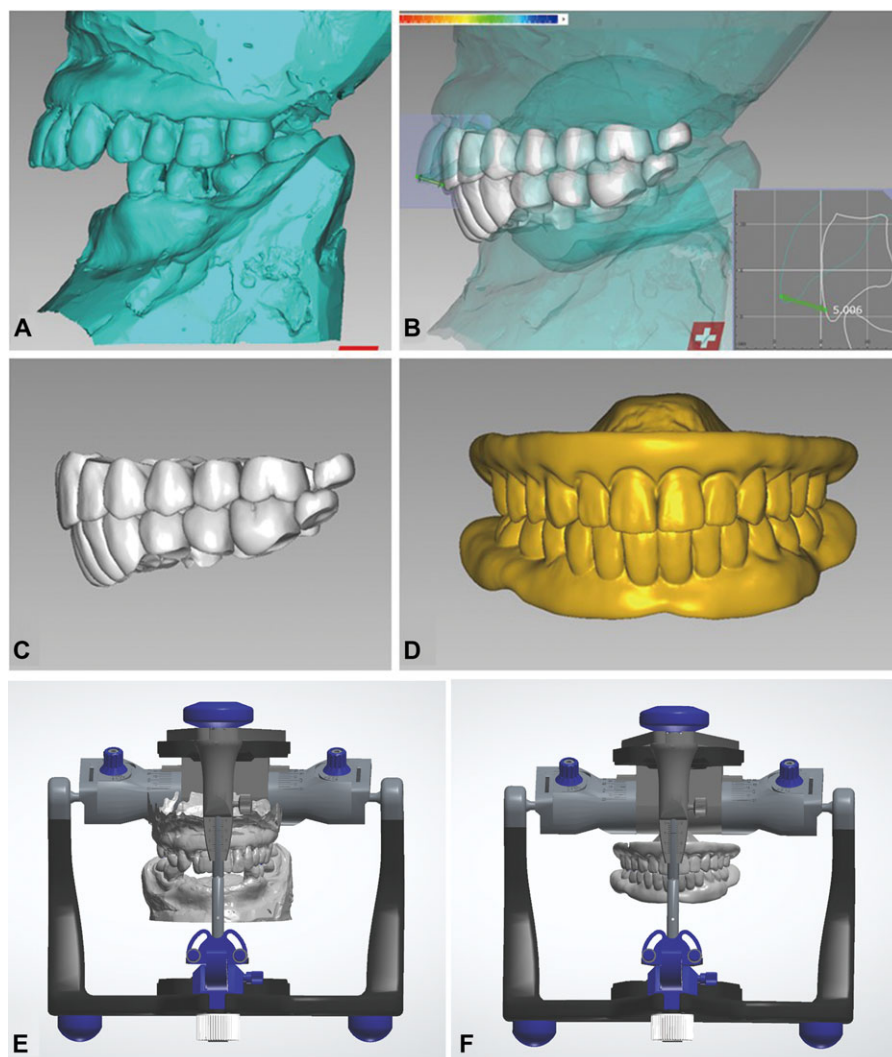
of the sites involving all sextants. Miller Grade II mobility was observed in all the remaining teeth except teeth #1, 15, 17, and 32 (Figs 1A, B, D). The panoramic radiograph showed severely resorbed alveolar bone due to periodontitis (Fig 1C).

Partial edentulism Class IV was diagnosed according to the Prosthodontic Diagnostic Index (PDI).<sup>5</sup> Then a number of prosthodontic treatment plans were presented to the patient, including conventional dentures, implant-retained overdentures, and implant-supported FDPs. After all treatment options were discussed with disadvantages and advantages, the patient chose to receive implant-supported FDPs on both arches with immediate interim restorations.

With the data from multi-slice spiral CT (Philips MX16 EVO CT; Koninklijke Philips N.V., Amsterdam, The Netherlands) and 3D facial photograph in the intercuspal position (3dMD-face System; 3dMD, Atlanta, GA), a virtual face with bone information and colored soft tissue were reconstructed in real time using Dolphin 3D Imaging (Dolphin Imaging & Management Solutions; Patterson Dental, Chatsworth, CA). The head position was then reoriented to natural head posture. Seventy-nine points (42 bony, 37 soft tissue) were plotted onto the virtual face (CT/3D photograph) as prompted by the Dolphin software, and curves connecting these points were generated automatically (Fig 2). To analyze the influence of retrusion of maxillary anterior teeth on the lateral facial profile, the



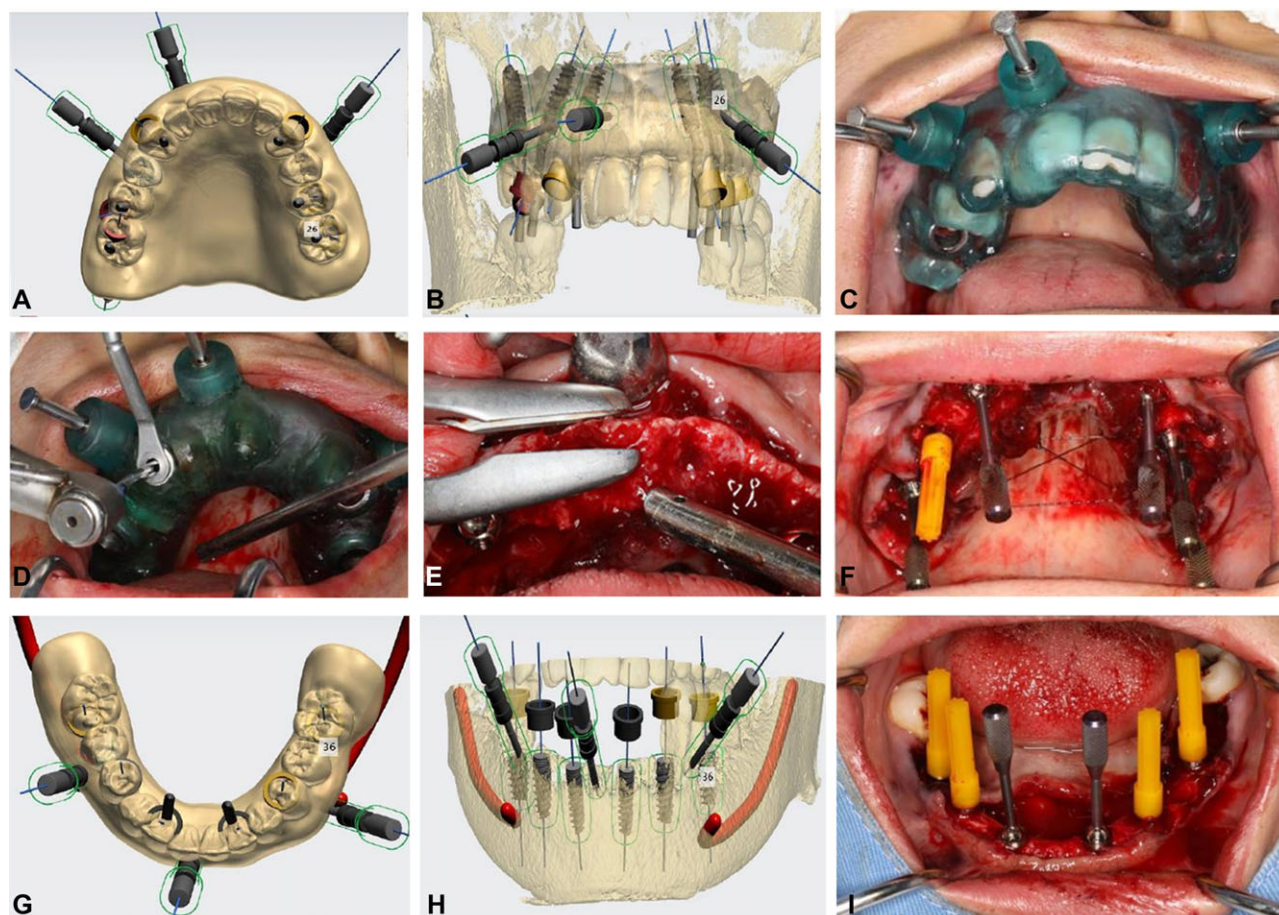
**Figure 3** Prediction of lateral profile with 1.0 to 6.0 mm retrusion of maxillary anterior teeth.



**Figure 4** (A) Original dentition. (B) Virtual retrusion of anterior teeth. (C) Modified dentition. (D) Virtual interim prostheses. (E) Preoperative dentition on virtual articulator. (F) Modified dentition on virtual articulator.

maxillary segment, which included the incisors (central and lateral incisors on both sides), was retruded for distances from 1.0 to 6.0 mm. Simultaneously, the facial soft tissue was simulated according to tooth movement. Without mandibular ante-

rior teeth, the lower lip was adjusted according to the movement of the upper lip. The patient compared the lateral profiles (1.0 to 6.0 mm) from the simulation under the direction of the first author (Fig 3). The plan of retruding the incisors for 5.0 mm



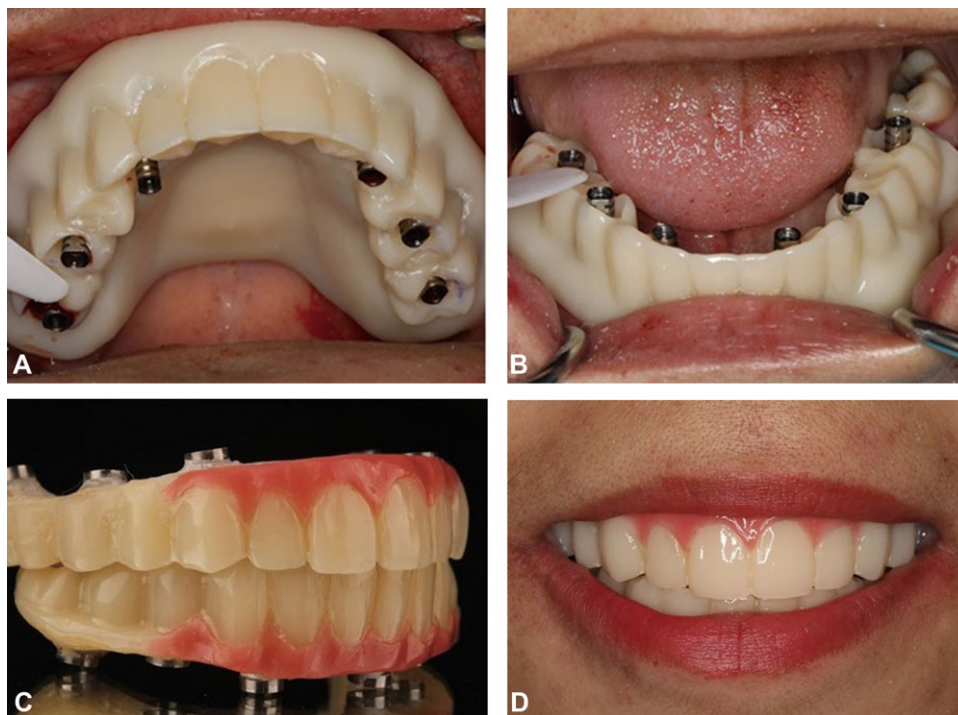
**Figure 5** (A-F) Guided implant placement on the maxilla. (G-I) Guided implant placement on the mandible.

was selected. The patient was notified of possible differences between the prediction and the final outcome due to various factors.

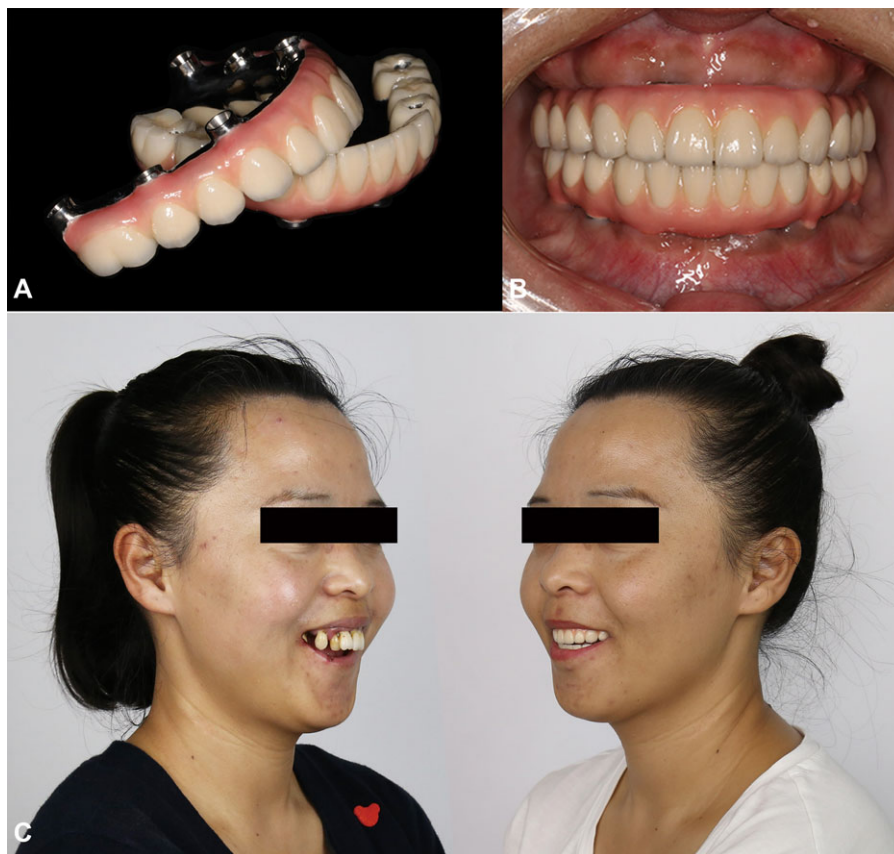After scanning the casts with 3Shape lab scanner (3Shape A/S, Copenhagen, Denmark) preserving their articulator-mounted relationship, the interim restorations were designed based on the original occlusal plane and occlusal vertical dimension with Exocad software (Exocad GmbH, Darmstadt, Germany). Incisal edges of maxillary anterior teeth were retruded for 5.0 mm, and the midline was adjusted according to the preoperative analysis. Bases were added to the virtual dentition for correct seating after the extraction of remaining teeth (Fig 4A to D). After the design of the modified dentition, the surgical steps were planned. In 3Shape software, a superimposition of the cast with virtual dentition and the cone beam CT (CBCT) data was performed for prosthetically driven planning of the position of implants. From this planning, 2 surgical guides for each arch were fabricated using a 3D printer (Formlabs Form 2; Formlabs, Boston, MA) with biocompatible photopolymer resin (Formlabs), and CAD/CAM interim dentures were milled from polymethyl methacrylate for the maxilla and mandible (Figs 5A, B, G, H).

The patient received local anesthesia, and the first tooth-supported guide was used only to determine the position of the anchor guide pins allowing accurate seating of the second guide for implant placement without tooth support. Twelve implants were inserted with 35 to 70 Ncm torque immediately after the extractions in the maxilla and mandible. With fully comprehensive consideration of the bone mass and position of the designed prosthesis, labial bone plates of maxillary anterior teeth were removed according to virtual simulation of root rotation (Figs 5C, D, E, F, I). The interim dental prostheses were positioned in the mouth. Multi-unit abutments were tightened to the implants, and interim titanium cylinders were connected to the prostheses with autopolymerizing acrylic resin. The occlusion was evaluated and clinically adjusted (Fig 6). Three weeks after the surgery, a layer of pink composite resin was added to simulate the color of gingival tissues (Fig 7). Hybrid prostheses with copy-milled titanium framework and acrylic veneering out of the scanned fixed interim dentures were delivered after 3 months.

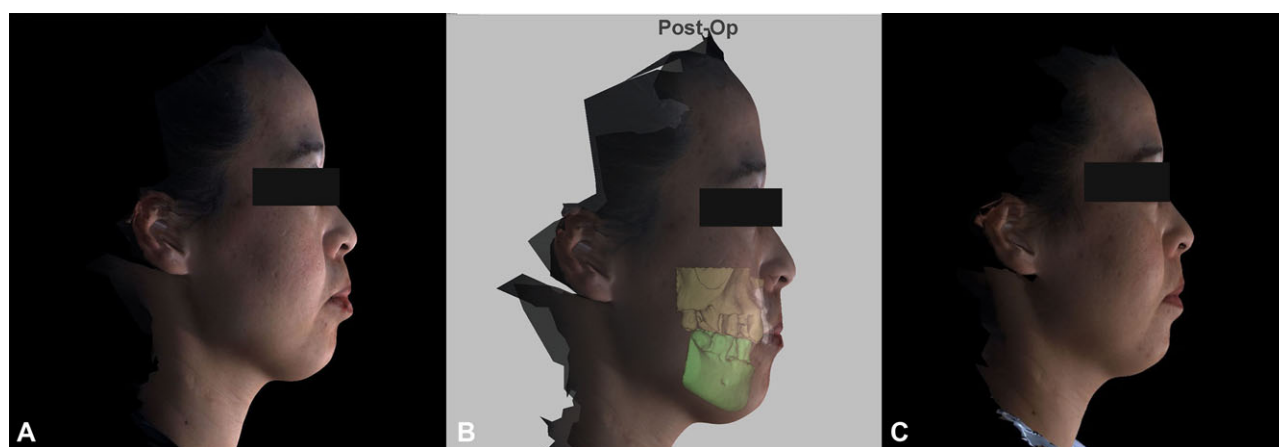
Apart from inconvenience of speaking in the first several days, the patient adapted to the interim prosthesis very well in the following 3 months. A postoperative 3D image



**Figure 6** (A-B) Seating of interim prostheses. (C) Interim prostheses with artificial gingiva. (D) Frontal view after restoration of interim prostheses.



**Figure 7** (A) Definitive prostheses. (B) Postoperative frontal view. (C) 45°-angled views of the patient before and after the treatment.



**Figure 8** (A) Preoperative lateral facial profile. (B) Prediction of lateral facial profile using Dolphin software. (C) Postoperative lateral facial profile.

demonstrated a nasolabial angle identical to the preoperative prediction (Fig 8).

## Discussion

The relationship between incisors and lip movements has been studied by several authors.<sup>6-9</sup> The amount of soft tissue profile change during orthodontic treatment is strongly associated with the horizontal movement of the maxillary incisors. More specifically, the incisal edge and the cervical point of the maxillary incisors show strong correlations to soft tissue profile changes. Studies have reported correlation factors between 0.47 and 0.66 for horizontal upper lip response to incisor retraction.<sup>10</sup> Accurate soft tissue predictions can be achieved using Dolphin software.<sup>11</sup> For this patient, lateral profile was analyzed based on the fact that her amount of tooth retraction was limited by the position of the basal bone. Finally, 2.0 to 3.0 mm of lip retraction was realized through 5.0 mm retrusion of maxillary anterior teeth.

Lip response is influenced not only by the amount of incisor retraction but also by the lip structure itself. Patients with thin lips or a high lip strain display a significant correlation between incisor retraction and lip retraction, whereas those with thick lips or low lip strain displayed no such correlation.<sup>12</sup> This patient with bimaxillary protrusion has thin and strained lips, and strong relationship was demonstrated.

The digital workflow presented allows the surgical position of implants to be guided by the design of the future prosthesis. Superimposition of photographs, casts, CBCT, and extraoral scanning have been determined to be reliable procedures.<sup>13,14</sup> Meanwhile, 3D digital smile design based on the face scan helps to achieve excitement and approval from patients when proposing treatment options, but the current software with a fixed smile line cannot simulate lateral profiles after retraction or protrusion of anterior teeth. In the future, it will be more desirable if a single software program can combine all functions like virtual planning, guided implant placement design, and facial profile design.

## References

1. D'haese J, Ackhurst J, Wismeijer D, et al: Current state of the art of computer-guided implant surgery. *Periodontol* 2000 2017;73:121-133
2. Coachman C, Calamita MA, Sesma N: Dynamic documentation of the smile and the 2D/3D digital smile design process. *Int J Periodontics Restorative Dent* 2017;37:183-193
3. Zimmermann M, Mehl A: Virtual smile design systems: a current review. *Int J Comput Dent* 2015;18:303-317
4. Lago L, Rilo B, Fernández-Formoso N, et al: Implant rehabilitation planning protocol for the edentulous patient according to denture space, lip support, and smile line. *J Prosthodont* 2017;26:545-548
5. McGarry TJ, Nimmo A, Skiba JF, et al: Classification system for partial edentulism. *J Prosthodont* 2002;11:181-193
6. Bourzgui F, Alami S, Sebbar M, et al: Effect of orthodontic treatment on lip position. *Int Orthod* 2013;11:303-313
7. Yogosawa F: Predicting soft tissue profile changes concurrent with orthodontic treatment. *Angle Orthod* 1990;60:199-206
8. Attarzadeh F, Adenwalla ST: Soft-tissue profile changes concurrent with the orthodontic treatment. *Int J Orthod* 1990;28:9-16
9. Garner LD: Soft-tissue changes concurrent with orthodontic tooth movement. *Am J Orthod* 1974;66:367-377
10. Kuhn M, Markic G, Doulis I, et al: Effect of different incisor movements on the soft tissue profile measured in reference to a rough-surfaced palatal implant. *Am J Orthod Dentofacial Orthop* 2016;149:349-357
11. Peterman RJ, Jiang S, Johe R, et al: Accuracy of Dolphin visual treatment objective (VTO) prediction software on class III patients treated with maxillary advancement and mandibular setback. *Prog Orthod* 2016;17:19
12. Mirjam Kuhn GM, Doulis I: Effect of different incisor movements on the soft tissue profile measured in reference to a rough-surfaced palatal implant. *Am J Orthod Dentofacial Orthop* 2016;149:349-357
13. Xu LW, You J, Zhang JX, et al: Impact of surgical template on the accuracy of implant placement. *J Prosthodont* 2016;25:641-646
14. Kim DI, Lagravère MO: Assessing the correlation between skeletal and corresponding soft-tissue equivalents to determine the relationship between CBCT skeletal/dental dimensions and 3D radiographic soft-tissue equivalents. *Int J Dent* 2018;2018:8926314