

CLINICAL REPORT

Prosthetic rehabilitation for a patient treated for embryonal rhabdomyosarcoma



Korbinian Benz, DDS,^a Carla Kozmacs, DMD,^b Andree Piwowarczyk, DMD,^c and Jochen Jackowski, DDS^d

Rhabdomyosarcoma (RMS) is a malignant soft-tissue tumor that develops from striated muscle cells. The 1-year incidence for those under 15 years of age is estimated at 1:224 000 and is responsible for 5% to 8% of all childhood malignancies.^{1,2} RMS can originate anywhere in the body, including regions without striated muscle.³ The head and neck are affected at a rate of 40%, with the orbital cavities and paranasal sinus most frequently affected.^{4,5}

The cause and mechanism of RMS are still largely unknown. Radiotherapy, used in the majority of treatments, often affects facial growth, vision, and hearing.^{6,7} After chemotherapy and radiotherapy, patients may experience oligodontia, microdontia, hypodontia, microstomia, xerostomia, and trismus.⁸⁻¹³ These conditions often lead to impaired ingestion, distorted speech, and poor esthetics.¹⁴

Successful dental implant treatment for patients undergoing the sequelae of irradiation has been reported, even in infancy.^{13,15-17} Nevertheless, the incidence of osteoradionecrosis remains unclear, with reports ranging between 0 and 73%, and consensus on the risks of tooth extraction after irradiation is lacking.¹⁸⁻²⁰ In addition, evidence concerning prosthetic restoration of teeth

ABSTRACT

A female patient, now aged 17 years, was diagnosed with rhabdomyosarcoma (RMS) in the right pterygopalatine fossa when she was 3 years old. The RMS was successfully treated by excision, but the subsequent radiation and polychemotherapy resulted in the complete anesthesia of the distribution area of the right trigeminal nerve and loss of vision in the right eye. The patient also experienced pain in the mandibular joints and masticatory muscles. Panoramic radiographs displayed a multiple agenesis of the permanent teeth and underdeveloped apices. Treatment involved the fabrication of a complete maxillary denture. A removable device was fabricated to evaluate her response to an occlusal vertical dimension increase of 6 mm and provide a stable intercuspal position. After wearing the prosthesis for 6 months, the patient reported that she was completely free of symptoms. (*J Prosthet Dent* 2018;120:299-302)

damaged by radiation, aside from their removal and replacement by implant-supported prostheses, is sparse.

CLINICAL REPORT

A young woman, now 17 years old, was diagnosed with a RMS in the right pterygopalatine fossa when she was 3 years old. This was successfully treated with excision and subsequent radiation (overall dose, 45 Gy for 1 month) and polychemotherapy following the CWS 96 protocol.²¹ The treatment resulted in complete anesthesia affecting the distribution area of the right trigeminal nerve and loss of vision in the right eye.

Her maxilla and mandible were micrognathic (*Fig. 1A*) with an Angle class III relationship. Closure in maximum intercuspation was nearly impossible and painful as a result of lack of support in the posterior region. All her teeth exhibited Class II or III mobility, and all except her

^aConsultant, Department of Oral Surgery and Dental Emergency Care, Faculty of Health, School of Dentistry Witten/Herdecke University, Witten, Germany; and Center for Rare Diseases Ruhr, Competence Center of the Ruhr-University Bochum and Witten/Herdecke University, North Rhine-Westphalia, Germany.

^bDoctor and Research Assistant, Department of Prosthodontics and Dental Technologies, Faculty of Health, School of Dentistry Witten/Herdecke University, North Rhine-Westphalia, Germany.

^cProfessor and Chairman, Department of Prosthodontics and Dental Technologies, Faculty of Health, School of Dentistry Witten/Herdecke University, Witten, Germany; and Center for Rare Diseases Ruhr, Competence Center of the Ruhr-University Bochum and Witten/Herdecke University, North Rhine-Westphalia, Germany.

^dProfessor and Chairman, Department of Oral Surgery and Dental Emergency Care, Faculty of Health, School of Dentistry Witten/Herdecke University, North Rhine-Westphalia, Germany; and Center for Rare Diseases Ruhr, Competence Center of the Ruhr-University Bochum and Witten/Herdecke University, Bochum, Germany.

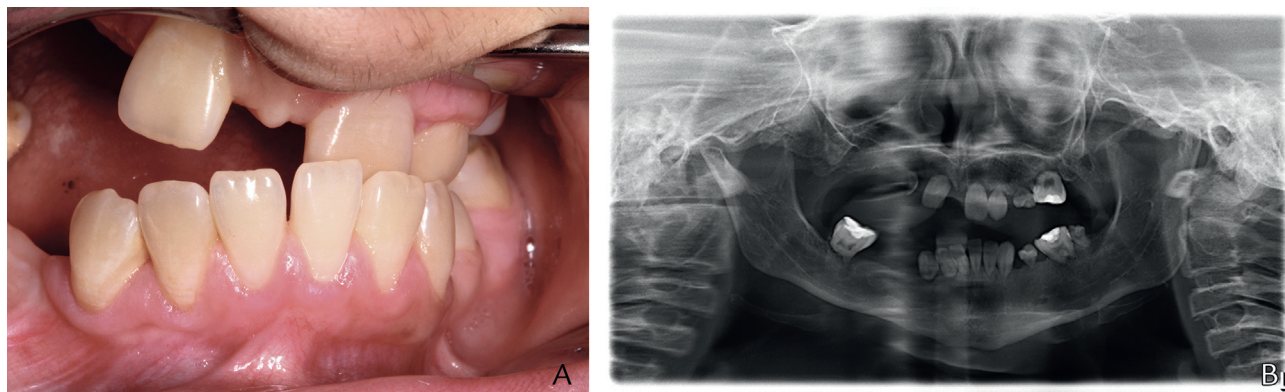


Figure 1. Before treatment. A, Patient in maximum intercuspal position, B, Panoramic radiograph.

left first maxillary molar and left mandibular incisors and canine tested negative to CO₂ cold spray. The patient reported a long history of complaints about her intraoral condition, and her nutritional intake was restricted to strained food.

The patient also experienced pain in the mandibular joints and masticatory muscles. A panoramic radiograph (Fig. 1B) revealed multiple missing permanent teeth and rudimentary developed roots. Her mandibular movement was severely restricted.

After consultation, an orthodontist and an oral and maxillofacial surgeon proposed corrective osteotomy and implant-supported prostheses. However, after lengthy discussion with the patient and her parents, implant therapy was declined and a treatment plan with removable prostheses was formulated, as the authors were unaware of reports of the successful fixed restoration of teeth with retarded root growth or root damage.

Treatment was initiated with a removable mandibular occlusal device that increased her occlusal vertical dimension (OVD) by 6 mm, measured in the molar region. The goals were to provide a stable intercuspal position and to evaluate her tolerance to the increased OVD (Fig. 2).

Impressions were made using a pediatric stock tray and alginate (Alginoplast; Kulzer GmbH). Her condition made a facebow recording impossible, so the maxillomandibular relation records were made with the casts mounted on an articulator. Increasing the OVD has been reported to facilitate treatment in patients with generalized and complex dental abnormalities and should be determined by the need to accomplish satisfactory and esthetically pleasing restorations.^{22,23} The patient immediately reported relief and comfort with the new occlusal relationship, and the 6 mm OVD increase was retained.

The complete maxillary overdenture was fabricated on the basis of a template (Erkodur; Erkodent) created from her tooth alignment (Fig. 3A), which, despite divergent teeth, incorporated the occlusal device into the prosthesis

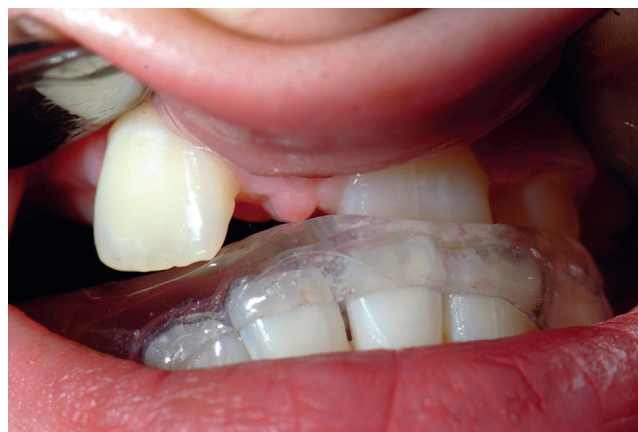

Figure 2. Mandibular occlusal device at increased occlusal vertical dimension.

(Palapress; Kulzer GmbH) (Fig. 3B) and avoided tooth preparations. Maxillary and mandibular impressions were made in a custom tray with a polyvinyl siloxane impression material (Honigum; DMG) (Fig. 4). By extending the maxillary denture base over the palate and vestibule, the prosthesis was also supported by soft tissue.

The mandibular prosthesis restored missing posterior teeth (Vita VM CC; Vita Zahnfabrik) and increased the length of anterior teeth with resin. The occlusal device was supported by both hard and soft tissue to provide load distribution and positional stability. Because the teeth were malpositioned and could not be properly evaluated intraorally, the midline and lip lines were assessed intraorally and transferred to the casts. The device was supported by all the teeth. To increase the retention, both devices were extended apically to the survey line of each tooth. The OVD determined during the 6-month trial period was transferred to the articulator (Fig. 5).

After the wax tooth arrangement and clinical evaluation, in which artificial teeth were arranged and evaluated to verify lip support and horizontal and vertical jaw relations, both occlusal devices were incorporated into

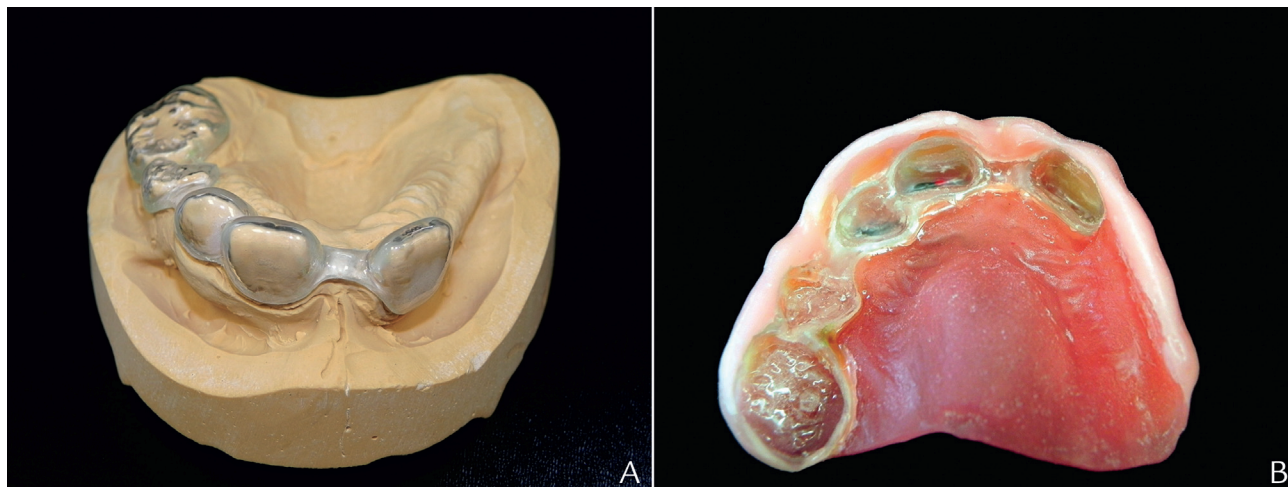


Figure 3. A, Maxillary occlusal device for maxilla. B, Device polymerized into maxillary denture.

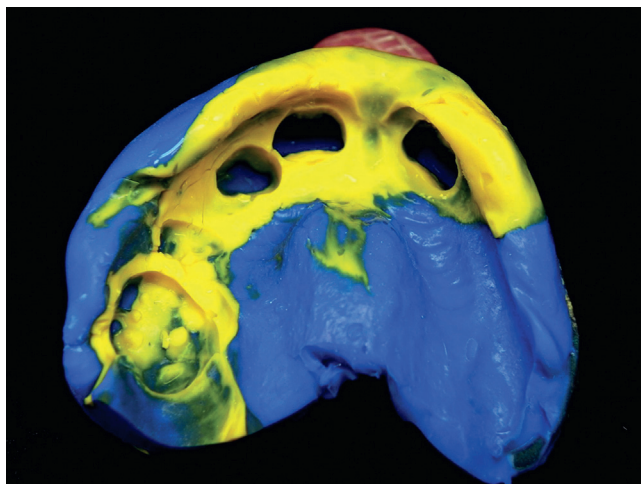


Figure 4. Definitive maxillary impression.

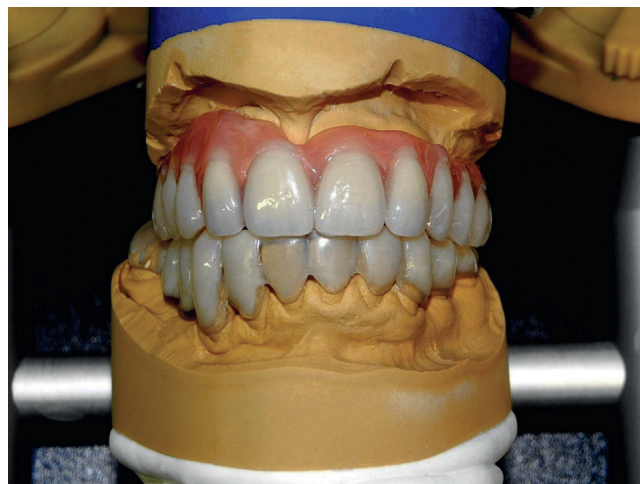

Figure 5. New occlusal dimension with stable intercusp position.

the prostheses. The existing teeth subsequently served as a guide for prosthesis insertion and provided retention and stability. The potential for trauma to the periodontium and surrounding soft tissue was minimal. Initially the patient's speech was poor, but it improved with speech therapy.

After 6 months of wear, the patient reported being completely free of symptoms. She did not report any difficulties with the dentition or with the cranio-mandibular or muscular structures during this time (Fig. 6).

DISCUSSION

In this treatment, every tooth was retained to conserve the supporting bone and provide better retention than a conventional complete denture. Conventional tooth preparation for cast restorations was also avoided because this would have limited prognosis. A cement-retained fixed partial denture also posed a risk of

additional trauma to the teeth, which were already significantly mobile. The aim was to attain maximum positional stability and splint the existing teeth.

The factors evaluated for increasing the OVD were remaining tooth structure, anterior teeth, space available for restoration, and esthetics. Nevertheless, changes in masticatory system function should be monitored during follow-up. Implant-supported restorations remain a future option.

SUMMARY

Direct loading to teeth adversely affected by radiotherapy or chemotherapy with a removable device is a new therapeutic concept, and to our knowledge, it has not been previously described. Prospective clinical studies will be challenging, but research is warranted to characterize nonsurgical prosthetic restoration in patients experiencing radiation sequelae, particularly regarding the long-term effects on orofacial structures.

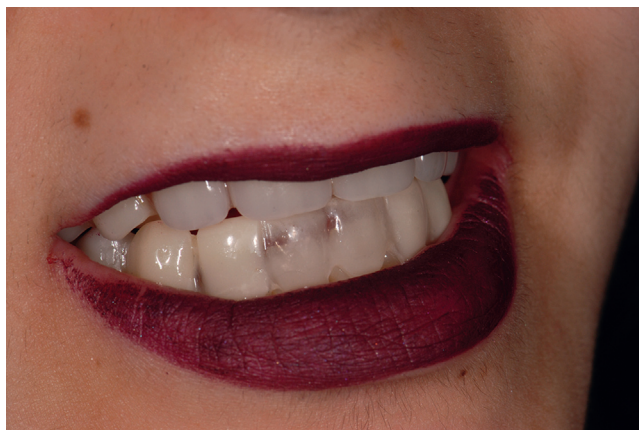

Figure 6. Prostheses delivered.

REFERENCES

- Gurney JG, Severson RK, Davis S, Robison LL. Incidence of cancer in children in the United States. Sex-, race-, and 1-year age-specific rates by histologic type. *Cancer* 1995;75:2186-95.
- Iatrou I, Theologie-Lygidakis N, Schoinohoriti O, Tzermpos F, Vessala AM. Rhabdomyosarcoma of the maxillofacial region in children and adolescents: report of 9 cases and literature review. *J Craniomaxillofac Surg* 2017;45:831-8.
- Zhu J, Zhang J, Tang G, Hu S, Zhou G, Liu Y, et al. Computed tomography and magnetic resonance imaging observations of rhabdomyosarcoma in the head and neck. *Oncol Lett* 2014;8:155-60.
- Pappo AS, Shapiro DN, Crist WM, Maurer HM. Biology and therapy of pediatric rhabdomyosarcoma. *J Clin Oncol* 1995;13:2123-39.
- Hicks J, Flaitz C. Rhabdomyosarcoma of the head and neck in children. *Oral Oncol* 2002;38:450-9.
- Paulino AC, Simon JH, Zhen W, Wen BC. Long-term effects in children treated with radiotherapy for head and neck rhabdomyosarcoma. *Int J Radiat Oncol Biol Phys* 2000;48:1489-95.
- Healy JN, Borg MF. Paediatric nasopharyngeal rhabdomyosarcoma: a case series and literature review. *J Med Imaging Radiat Oncol* 2010;54:388-94.
- Kaste SC, Hopkins KP, Bowman LC. Dental abnormalities in long-term survivors of head and neck rhabdomyosarcoma. *Med Pediatr Oncol* 1995;25:96-101.
- Schoen PJ, Raghoobar GM, Bouma J, Reintsema H, Burlage FR, Roodenburg JL, et al. Prosthodontic rehabilitation of oral function in head-neck cancer patients with dental implants placed simultaneously during ablative tumour surgery: an assessment of treatment outcomes and quality of life. *Int J Oral Maxillofac Surg* 2008;37:8-16.
- Estilo CL, Huryn JM, Kraus DH, Sklar CA, Wexler LH, Wolden SL, et al. Effects of therapy on dentofacial development in long-term survivors of head and neck rhabdomyosarcoma: the memorial sloan-kettering cancer center experience. *J Pediatr Hematol Oncol* 2003;25:215-22.
- Dury DC, Roberts MW, Miser JS, Folio J. Dental root agenesis secondary to irradiation therapy in a case of rhabdomyosarcoma of the middle ear. *Oral Surg Oral Med Oral Pathol* 1984;57:595-9.
- Kupeli S, Varan A, Ozyar E, Atahan IL, Yalcin B, Kutluk T, et al. Treatment results of 84 patients with nasopharyngeal carcinoma in childhood. *Pediatr Blood Cancer* 2006;46:454-8.
- Zwetchkenbaum SR, Oh WS. Prosthodontic management of abnormal tooth development secondary to chemoradiotherapy: a clinical report. *J Prosthet Dent* 2007;98:429-35.
- Kaste SC, Goodman P, Leisenring W, Stovall M, Hayashi RJ, Yeazel M, et al. Impact of radiation and chemotherapy on risk of dental abnormalities: a report from the Childhood Cancer Survivor Study. *Cancer* 2009;115:5817-27.
- Korfage A, Stellingsma K, Jansma J, Vissink A, Raghoobar GM. Oral rehabilitation with implant-based prostheses of two adult patients treated for childhood rhabdomyosarcoma. *Support Care Cancer* 2011;19:1477-80.
- Bektas-Kayhan K, Karagoz G, Bayrak O, Kurklu E, Ozbek CD, Ak G, et al. Implant-assisted dental rehabilitation of a patient with maxillary rhabdomyosarcoma. *J Craniofac Surg* 2012;23:e384-6.
- Bilhan H, Geckili O, Atalay B, Arat S. Oral rehabilitation following removal of a rhabdomyosarcoma and subsequent microstomia: a case report. *J Oral Implantol* 2011;37:353-60.
- Ben-David MA, Diamante M, Radawski JD, Vineberg KA, Stroup C, Murdoch-Kinch CA, et al. Lack of osteoradionecrosis of the mandible after intensity-modulated radiotherapy for head and neck cancer: likely contributions of both dental care and improved dose distributions. *Int J Radiat Oncol Biol Phys* 2007;68:396-402.
- Thorn JJ, Hansen HS, Specht L, Bastholt L. Osteoradionecrosis of the jaws: clinical characteristics and relation to the field of irradiation. *J Oral Maxillofac Surg* 2000;58:1088-93.
- Kojima Y, Yanamoto S, Umeda M, Kawashita Y, Saito I, Hasegawa T, et al. Relationship between dental status and development of osteoradionecrosis of the jaw: a multicenter retrospective study. *Oral Surg Oral Med Oral Pathol Oral Radiol* 2017;124:139-45.
- Dantonello TM, Int-Veen C, Winkler P, Leuschner I, Schuck A, Schmidt BF, et al. Initial patient characteristics can predict pattern and risk of relapse in localized rhabdomyosarcoma. *J Clin Oncol* 2008;26:406-13.
- Keough B. Occlusion-based treatment planning for complex dental restorations: part 1. *Int J Periodontics Restorative Dent* 2003;23:237-47.
- Abduo J, Lyons K. Clinical considerations for increasing occlusal vertical dimension: a review. *Aust Dent J* 2012;57:2-10.

Corresponding author:

Dr Korbinian Benz
Department of Oral Surgery and Dental Emergency Care
Faculty of Health
School of Dentistry Witten/Herdecke University
Alfred-Herrhausen-Strasse 50, 58448 Witten
GERMANY
Email: Korbinian.Benz@uni-wh.de

Copyright © 2017 by the Editorial Council for *The Journal of Prosthetic Dentistry*.