

## DENTAL TECHNIQUE

# Digital intraoral scanning technique for edentulous jaws



Jing-Huan Fang, DDS,<sup>a</sup> Xueyin An, DDS,<sup>b</sup> Seung-Mi Jeong, DDS, PhD,<sup>c</sup> and Byung-Ho Choi, DDS, PhD<sup>d</sup>

Making dental impressions is a common first step for most dental procedures.<sup>1</sup> However, studies have shown that many of the conventional dental impressions that are sent to dental laboratories are unsatisfactory because of flaws such as voids or bubbles in critical locations.<sup>2,3</sup> Moreover, distortion and expansion of the gypsum casts can further reduce the accuracy of this conventional dental restoration fabrication process.<sup>4</sup> The introduction of intraoral systems for intraoral digital scanning has allowed clinicians to directly acquire data from the mouth without the need to make a conventional impression and pour a cast.<sup>5,6</sup> Therefore, the time needed for digitalization and fabrication is reduced, and potential errors are minimized or eliminated.<sup>4</sup>

Several reports have focused on the feasibility and accuracy of intraoral digital scans for complete arches.<sup>7-13</sup> However, few published studies have evaluated direct digital scans of edentulous jaws using intraoral scanners because it is difficult to scan edentulous sites that are smooth and devoid of features.<sup>14,15</sup> The stitching process can be faulty, especially in the palatal area.<sup>14</sup> The greatest deviations in the palatal areas were reported in digitizing edentulous jaws with intraoral scanners.<sup>14</sup> Lee<sup>16</sup> reported that when drawing lines on the palate with a mixture of pressure-indicating paste and interim zinc oxide-eugenol cement, the palate could be scanned with an intraoral scanner. However, scanning edentulous areas with this technique was found to be difficult for patients with a broad palatal vault (Fig. 1). In this paper, a new scanning technique for direct digital scans of

## ABSTRACT

Few studies have evaluated direct digital scans of edentulous jaws using intraoral scanners because it is difficult to scan edentulous sites that are smooth and devoid of features. A scanning technique is introduced for making direct digital scans of edentulous jaws with intraoral scanners in patients with a broad palate. (J Prosthet Dent 2018;119:733-5)

edentulous jaws using intraoral scanners in patients with broad palates is introduced.

## TECHNIQUE

1. Before scanning, clean and dry the hard palate with cotton rolls and air syringe.
2. Inject flowable composite resin (Charmfil Flow; Dentist Inc) to 6 different sites on the hard palate in a half-sphere shape with a diameter of 1 or 2 mm and light-polymerize the resin.
3. After polymerizing, apply histoacryl glue (B. Braun; Aesculap AG) to the resin marker areas to secure the markers, either as minute drops or as a thin film along the borders of the markers. After applying the glue, wait 30 seconds to allow the adhesive to dry completely.
4. Scan the edentulous area with an intraoral scanner (TRIOS3; 3Shape A/S) (Fig. 2). After scanning, remove the markers with cotton pliers.
5. Delete the marker image in the scanned edentulous ridge image (Fig. 3).

## DISCUSSION

Acquiring a precise digital scan with an intraoral scanner is difficult, especially for patients with a broad

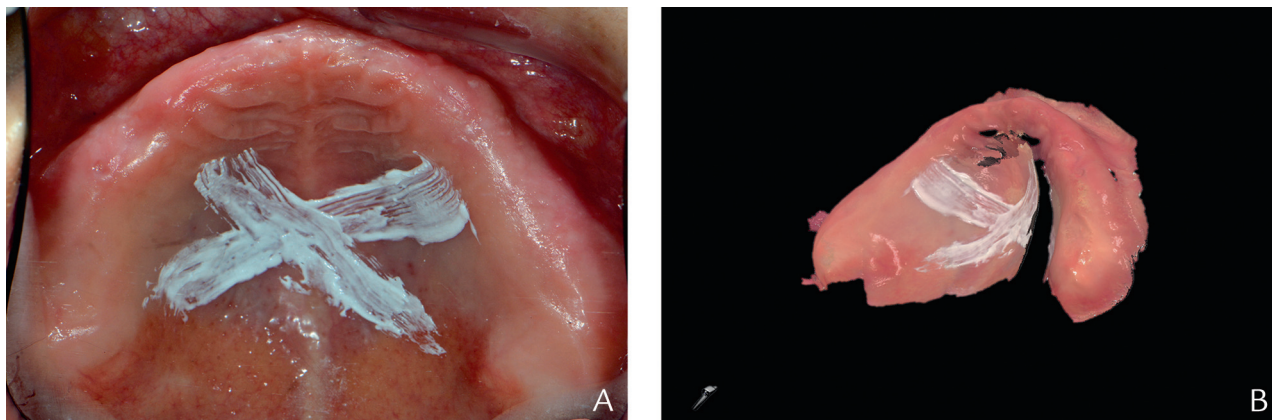
Supported by the Ministry of Trade, Industry & Energy (MOTIE, Korea) under Industrial Technology Innovation Program (grant no. 10060000).

<sup>a</sup>Graduate student, Department of Dentistry, Yonsei University Wonju College of Medicine, Wonju, Republic of Korea.

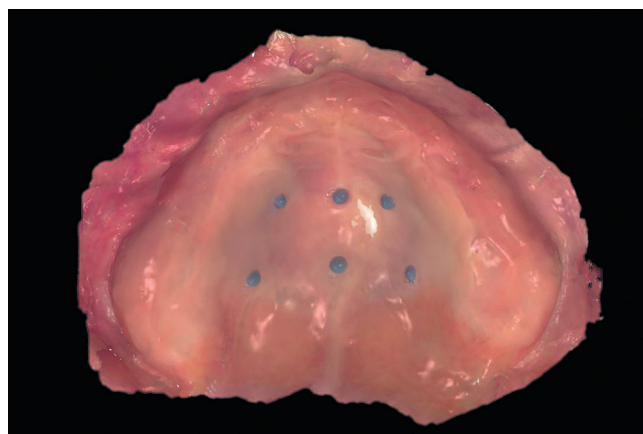
<sup>b</sup>Graduate student, Department of Dentistry, Yonsei University Wonju College of Medicine, Wonju, Republic of Korea.

<sup>c</sup>Professor, Department of Dentistry, Yonsei University Wonju College of Medicine, Wonju, Republic of Korea.

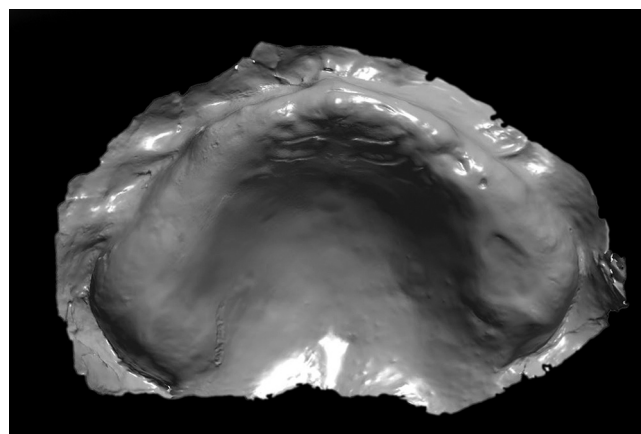
<sup>d</sup>Professor, Department of Dentistry, Yonsei University Wonju College of Medicine, Wonju, Republic of Korea.



**Figure 1.** Scanning maxillary edentulous jaw with broad palatal vault. A, Lines drawn on palate with mixture of pressure-indicating paste and zinc oxide-eugenol cement. B, Scanned image produced with intraoral scanner (TRIOS3) showing image mismatches at palatal site caused by error resulting from incorrect stitching processes.



**Figure 2.** Scanned image produced with intraoral scanner (TRIOS3) using resin markers placed on hard palate.



**Figure 3.** Scanned image after deleting resin markers in scanned edentulous ridge image.

palate.<sup>14</sup> Difficulties arise in stitching the pictures acquired from intraoral scanners because of the lack of clear anatomic landmarks.<sup>17</sup> The smooth surface of palatal areas translates into poorly traceable structures.<sup>14</sup> Overlapping areas are essential for correct stitching of acquired images that result in a 3-dimensional (3D) data set.<sup>14</sup> Poorly differentiated structures (that is, edentulous spaces or palatal areas) will likely lead to faulty processing and the summation of matching errors for the entire data set.<sup>18,19</sup> Stitching errors can cause significant deviations in scanned images.<sup>14</sup> To overcome these limitations, clinicians have described the use of artificial landmarks.<sup>16,20</sup> Lee<sup>16</sup> drew lines on the palate with a mixture of pressure-indicating paste and interim zinc oxide-eugenol cement. However, the process of coating the palate did not solve stitching errors when broad palatal vaults were scanned. To improve the accuracy of the digital scans of edentulous areas made with an intraoral scanner, Kim et al<sup>20</sup> used a 4×3 mm alumina marker that was attached to the surfaces of the gingiva

with a light-polymerizing resin. A common problem with alumina markers is that they can come loose during the intraoral scan, especially when patients disturb them with their tongue.

This technique used flowable composite resin and glue to secure the resin markers. The strength of the bond between the resin markers and the gingiva does not solely depend on the adhesive properties of the resin; the surface coating glue, which leads to strong and durable bonding, is also important. The markers do not come loose, even when patients touch them with their tongue. After removing the markers from the palate, some tissue adhesive remains on patients' palatal gingiva but dissolves within an hour. The tissue adhesive used in this technique was N-butyl 2-cyanoacrylate and was approved for clinical use in 1996.<sup>21</sup> Since then, it has been widely used to close superficial lacerations and in a variety of surgeries.<sup>21</sup>

The markers are 1 or 2 mm in diameter and are easy to delete in the captured digital image. The resin

markers are radiopaque and can be used to merge intraoral scans and cone-beam computed tomography (CBCT) data for the virtual planning of computer-guided implant surgery.

Even though the accuracy of intraoral scanners has been evaluated,<sup>9–11</sup> the authors are unaware of studies on the accuracy of intraoral scanners when edentulous jaws are scanned. Studies on the use of intraoral scanners in direct digital scans of edentulous jaws are needed to determine whether the accuracy of digital scans for edentulous jaws is clinically acceptable.

## SUMMARY

This paper describes a scanning technique that facilitates using intraoral scanners to make digital scans of edentulous jaws with a broad palate. This technique uses 1- or 2-mm-diameter resin markers placed on the hard palate. Glue is also used to secure the resin markers, which serve as traceable structures for scanning a smooth palatal surface. By using the markers and an intraoral scanner, digital scans of maxillary edentulous jaws can be acquired directly.

## REFERENCES

1. Walmsley AD, Pinsent RH, Laird WR. Complete dentures: 1. Treatment planning and preliminary care. *Dent Update* 1991;18:257–60.
2. Carotte PV, Winstanley RB, Green JR. A study of the quality of impressions for anterior crowns received at a commercial laboratory. *Br Dent J* 1993;174:235–40.
3. Winstanley RB, Carotte PV, Johnson A. The quality of impressions for crowns and bridges received at commercial dental laboratories. *Br Dent J* 1997;183:209–13.
4. Millstein PL. Determining the accuracy of gypsum casts made from type IV dental stone. *J Oral Rehabil* 1992;19:239–43.
5. Quaas S, Rudolph H, Luthardt RG. Direct mechanical data acquisition of dental impressions for the manufacturing of CAD/CAM restorations. *J Dent* 2007;35:903–8.
6. Schoenbaum TR. Decoding CAD/CAM and digital impression units. *Dent Today* 2010;29:144–5.
7. Flügge TV, Schlager K, Nelson S, Nahles MC. Precision of intraoral digital dental impressions with iTero and extraoral digitization with the iTero and a model scanner. *Am J Orthod Dentofacial Orthop* 2013;144:471–8.
8. Grünheid SD, McCarthy BE. Clinical use of a direct chair side oral scanner: an assessment of accuracy, time, and patient acceptance. *Am J Orthod Dentofacial Orthop* 2014;146:673–82.
9. Mino T, Maekawa K, Ueda A, Higuchi S, Higuchi S, Sejima J, et al. In silico comparison of the reproducibility of full-arch implant provisional restorations to final restoration between a 3D Scan/CAD/CAM technique and the conventional method. *J Prosthodont Res* 2015;59:152–8.
10. Kuhr F, Schmidt A, Rehmann P, Wöstmann B. A new method for assessing the accuracy of full arch impressions in patients. *J Dent* 2016;55:68–74.
11. Gan N, Xiong Y, Jiao T. Accuracy of intraoral digital impressions for whole upper jaws, including full dentitions and palatal soft tissues. *PLoS One* 2016;11:e0158800.
12. Ender T, Attin A. In vivo precision of conventional and digital methods of obtaining complete-arch dental impressions. *J Prosthet Dent* 2016;115:313–20.
13. Güth JF, Edelhoff D, Schweiger J, Keul C. A new method for the evaluation of the accuracy of full-arch digital impressions in vitro. *Clin Oral Investig* 2016;20:1487–94.
14. Patzelt SB, Vonau S, Stampf S, Att W. Assessing the feasibility and accuracy of digitizing edentulous jaws. *J Am Dent Assoc* 2013;144:914–20.
15. Kattadiyil MT, Mursic Z, AlRumaih H, Goodacre CJ. Intraoral scanning of hard and soft tissues for partial removable dental prosthesis fabrication. *J Prosthet Dent* 2014;112:444–8.
16. Lee JH. Improved digital impressions of edentulous areas. *J Prosthet Dent* 2017;117:448–9.
17. Andriessen FS, Rijkens DR, van der Meer WJ, Wismeijer DW. Applicability and accuracy of an intraoral scanner for scanning multiple implants in edentulous mandibles: a pilot study. *J Prosthet Dent* 2014;111:186–94.
18. Besl PJ, McKay ND. A method for registration of 3-D shapes. *IEEE Trans Pattern Anal Mach Intell* 1992;14:239–56.
19. Chen Y, Medioni G. Object modelling by registration of multiple range images. *Image Vis Comput* 1992;10:145–55.
20. Kim JE, Amelya A, Shin Y, Shim JS. Accuracy of intraoral digital impressions using an artificial landmark. *J Prosthet Dent* 2017;117:755–61.
21. Inal S, Yilmaz N, Nisbet C, Guvenc T. Biochemical and histopathological findings of N-Butyl-2-Cyanoacrylate in oral surgery: an experimental study. *Oral Surg Oral Med Oral Pathol Oral Radiol* 2016;102:e14–7.

### Corresponding author:

Dr Byung-Ho Choi  
Department of Dentistry  
Yonsei University Wonju College of Medicine  
162 Ilsandong, Wonju  
REPUBLIC OF KOREA  
Email: choibh@yonsei.ac.kr

Copyright © 2017 by the Editorial Council for *The Journal of Prosthetic Dentistry*.