

CLINICAL REPORT

Integrating a facial scan, virtual smile design, and 3D virtual patient for treatment with CAD-CAM ceramic veneers: A clinical report



Wei-Shao Lin, DDS,^a Bryan T. Harris, DMD,^b Kamolpob Phasuk, DDS, MS,^c Daniel R. Llop, CDT,^d and Dean Morton, BDS, MS^e

Smile design has used the patient's diagnostic data, scientific principles, and artistic concepts of beauty to create an esthetically pleasing smile.¹ Both microesthetic elements²⁻⁵

and macroesthetic elements,⁶ such as facial esthetics,⁷ oral esthetics,⁸ and dentogingival esthetics,¹ are essential in the smile design process.^{9,10} The concept of virtual smile design was introduced initially by using commercially available computer presentation software (Keynote; Apple Inc or PowerPoint; Microsoft Corp) to edit the patient's digital dentofacial photographs and simulate the desired esthetic outcome with a customized 2-dimensional (2D) virtual smile design.^{11,12} The 2D virtual smile design in the presentation software could then be converted into either a conventional or a virtual diagnostic waxing to facilitate subsequent clinical treatments, such as computer-aided design and computer-aided manufacturing (CAD-CAM) restorations.¹³⁻¹⁷

Although virtual diagnostic technology and treatment planning workflows have been evolving, the creation of a 3D virtual patient remains complex. To create a 3D virtual patient, digital 3D diagnostic data, such as remaining dentition (including intraoral soft tissue), craniofacial hard tissue, and extraoral soft tissue must be accurately integrated into a single entity.¹⁸ Intraoral scanning can be used to acquire digital data of the remaining dentition

ABSTRACT

This clinical report describes a digital workflow using the virtual smile design approach augmented with a static 3-dimensional (3D) virtual patient with photorealistic appearance to restore maxillary central incisors by using computer-aided design and computer-aided manufacturing (CAD-CAM) monolithic lithium disilicate ceramic veneers. (J Prosthet Dent 2018;119:200-205)

and surround soft tissue in the standard tessellation language (STL) file format.¹⁹⁻²¹ Laser and optically based extraoral surface imaging technologies have been proposed to obtain digital data of extraoral soft tissue for the creation of a 3D virtual patient with photorealistic appearance.²²⁻³¹

Because of their minimal invasiveness,³²⁻³⁴ esthetic properties,³⁵ and favorable clinical outcomes,^{36,37} monolithic or layered lithium disilicate ceramic veneers have become a clinically acceptable option. This clinical report describes a digital treatment workflow for restoring maxillary central incisors with CAD-CAM monolithic lithium disilicate ceramic veneers.

CLINICAL REPORT

An endodontic specialist referred a 45-year-old white woman whose main esthetic concern was chipped maxillary central incisors due to an automobile accident. The patient wished to address the space between maxillary central incisors and consented to lithium disilicate ceramic veneers for both maxillary central incisors.

^aAssociate Professor and Director, Division of Prosthodontics, Department of Oral Health and Rehabilitation, University of Louisville School of Dentistry, Louisville, Ky.

^bAssociate Professor and Director, Advanced Education in Prosthodontics, Department of Oral Health and Rehabilitation, School of Dentistry, University of Louisville, Louisville, Ky.

^cAssistant Professor, Department of Prosthodontics, Indiana University School of Dentistry, Indianapolis, Ind.

^dConsultant, NDX nSequence, Reno, Nev.

^eProfessor and Chair, Department of Prosthodontics, Indiana University School of Dentistry, Indianapolis, Ind.

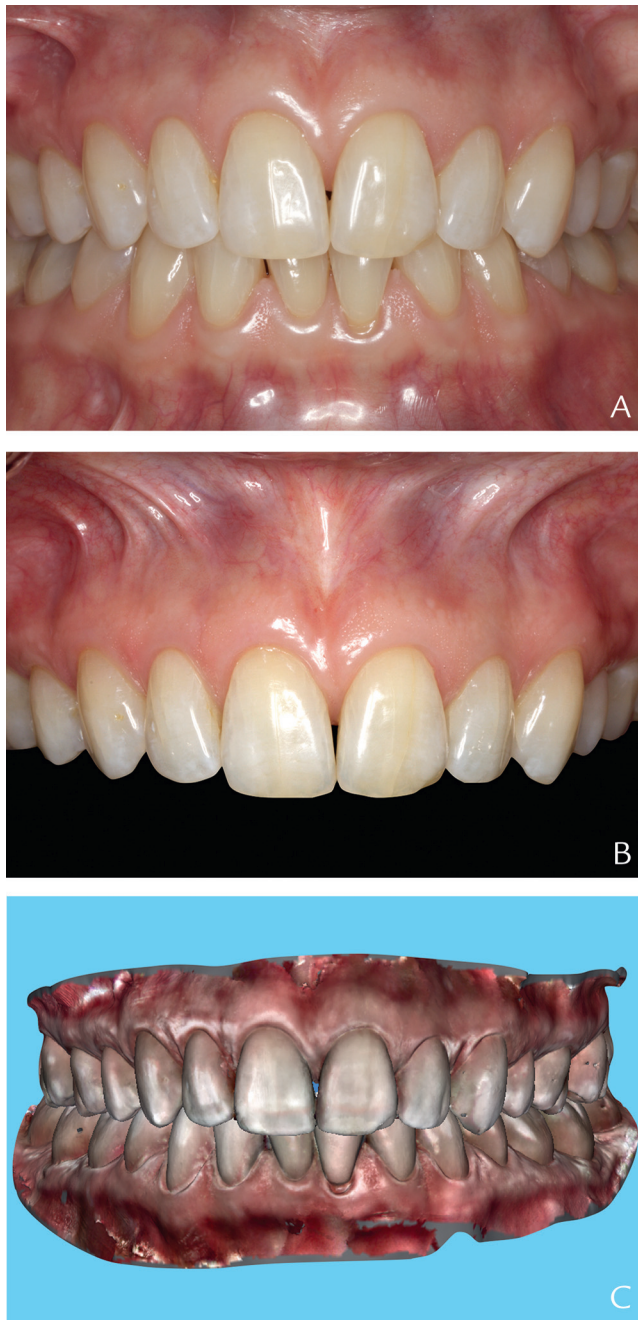


Figure 1. Intraoral pretreatment condition. A, Digital intraoral photograph from retracted frontal view at maximum incuspation position. B, Digital intraoral photograph made with black background. C, Digital intraoral scan.

Digital intraoral photographs were made from a retracted frontal view and against black backgrounds (Anterior Classic Contraster; PhotoMed Intl) (Fig. 1A, B). A diagnostic impression was made with an intraoral scanner (iTero; Align Technology Inc) (Fig. 1C) and exported in the STL file format. Digital extraoral photographs were made at a full smile from the mid-facial and right and left 45-degree views (Fig. 2A). In addition, the

patient's 3D facial soft tissue profile was captured at the full smile position with an inexpensive and portable extraoral 3D scanner (Sense; 3D Systems Inc) (Fig. 2B). All digital photographs were exported in the Joint Photographic Experts Group (JPEG) file format, and 3D facial scan data were exported in the STL file format. The digital intraoral and extraoral photographs were imported into presentation software (Keynote; Apple Inc), and a customized 2D virtual smile design was drawn and superimposed on the digital photographs (Fig. 3A, B). The customized 2D virtual smile design was shown to the patient for her initial approval of the esthetic outcome and exported in the Keynote (KEY) file format.^{12,13} All digital diagnostic data (JPEG, STL, and KEY files) were forwarded to a dental laboratory (NDX nSequence).

In the dental laboratory, the JPEG files of the extraoral digital photographs and the STL file of the extraoral facial scan were imported in CAD software (Geomagic Freeform; 3D Systems Inc). Constant soft tissue landmarks were used to merge the 2D and 3D digital data with the surface-based merging process.^{18,31} A virtual patient of photorealistic appearance of facial soft tissue at full smile was created (Fig. 4A). The STL file of 3D intraoral scan was then registered to the virtual patient using remaining teeth as merging landmarks (Fig. 4B). The customized 2D virtual smile design was used by the dental laboratory technician as a visual reference to create the virtual diagnostic waxing (Fig. 4C). This 3D virtual patient with desired virtual diagnostic waxing was demonstrated to the patient and was modified according to the patient's feedback. A CAD-CAM diagnostic cast with diagnostic waxing (which was approved by the patient, clinician, and dental laboratory technician) was additively manufactured (Fig. 4D).

A preparation guide was fabricated with a vacuum formed matrix (.020-inch Clear Tray Material; Buffalo Dental Mfg) from the CAD-CAM diagnostic cast. The abutment teeth were prepared, guided by the vacuum-formed matrix (Fig. 5A, B). The single-cord technique³⁸ was used for soft tissue management during the intraoral scanning procedure (iTero; Align Technology Inc) (Fig. 5C). Autopolymerizing composite resin (Integrity Temporary C&B Material; Dentsply Sirona) and the vacuum-formed matrix were used to fabricate the interim veneers (Fig. 5D). The intraoral scan was transferred to the dental laboratory (Roy Dental Laboratory), and the definitive veneers were fabricated with machinable lithium disilicate ceramic block (IPS e.max CAD; Ivoclar Vivadent AG) (Fig. 6A, B).

After the trial insertion to confirm marginal fit and optical properties, the abutment teeth were isolated with rubber dam (Non-Latex Dental Dam; Sanctuary Health), modified dental clamps (212 Satin Steel Rubber Dam Clamp; Hu-Friedy Mfg), and dental isolation tape (Iso-Tape; TDV Dental Ltda). The isolated abutment teeth




Figure 2. Extraoral pretreatment condition at full smile position from mid-facial, and right and left 45-degree views. A, Digital extraoral photographs. B, Digital extraoral facial scan.

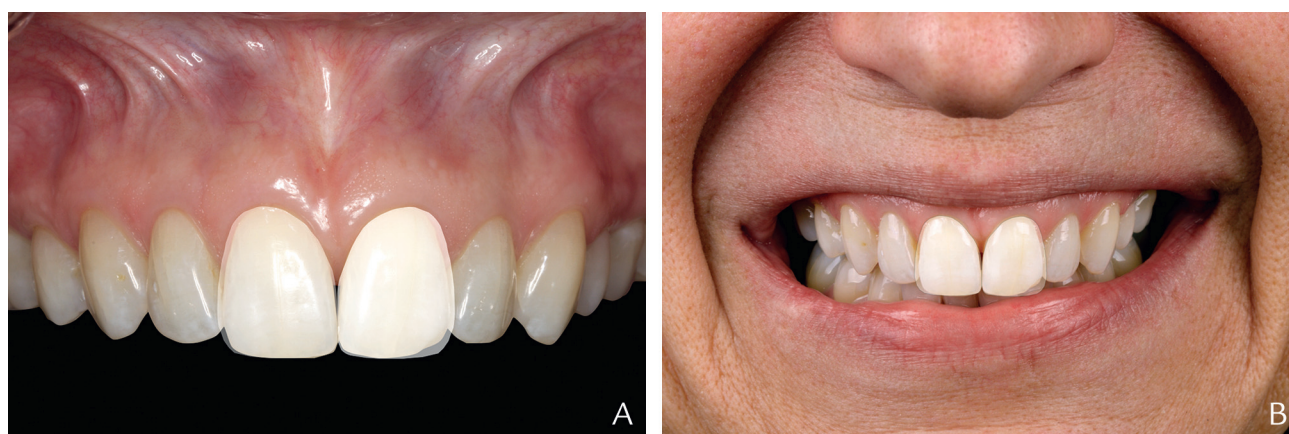

Figure 3. Customized 2D virtual smile design created and superimposed on digital photographs in presentation software. A, Intraoral view. B, Extraoral view.

and ceramic veneers were prepared by following the manufacturer's recommendation, and the veneers were adhesively luted to the abutments with light-polymerizing resin luting agent (RelyX Veneer Cement; 3M ESPE). Excess luting agent was removed, and no complications were observed during the 6 months after insertion (Fig. 7A, B).

DISCUSSION

This clinical report describes a digital treatment workflow using a virtual smile design principle in a 3D virtual patient during the diagnostic and treatment planning phases to facilitate treatment with CAD-CAM ceramic veneers. The 2D virtual smile design approach is gaining popularity as a conceptual tool to improve communication among clinicians, patients, and dental technicians and to enhance treatment predictability.¹²⁻¹⁵ However, with the existing 2D virtual smile design approach, perspective distortion may cause inaccuracy or errors in the conversion process from 2D design to 3D diagnostic waxing,^{13,17} and the use of a 3D virtual patient can

overcome this limitation. After the confirmation of simulated esthetic outcome in the 3D virtual patient, a CAD-CAM cast can be directly fabricated from an approved virtual diagnostic waxing without the need of further conversion. This CAD-CAM cast can be used to fabricate a vacuum-formed matrix to increase the predictability from the virtual smile design to the actual clinical esthetic outcome.

Creating a 3D virtual patient with the extraoral facial and intraoral scan has some limitations. Although many medical and dental 3D surface imaging scanners can be used to obtain the required extraoral facial scan, these scanners may be cost prohibitive for the dental clinicians. In this clinical report, an economic and portable extraoral 3D scanner (Sense; 3D Systems Inc) was used instead. However, the procedures for merging extraoral digital photographs, extraoral facial scans, and intraoral scans in creating a 3D virtual patient would require additional time, resources, and training for the dental laboratory technician and incur additional cost for the clinician and patient. The clinician should also verify that the patient's facial expression and head positioning are consistent

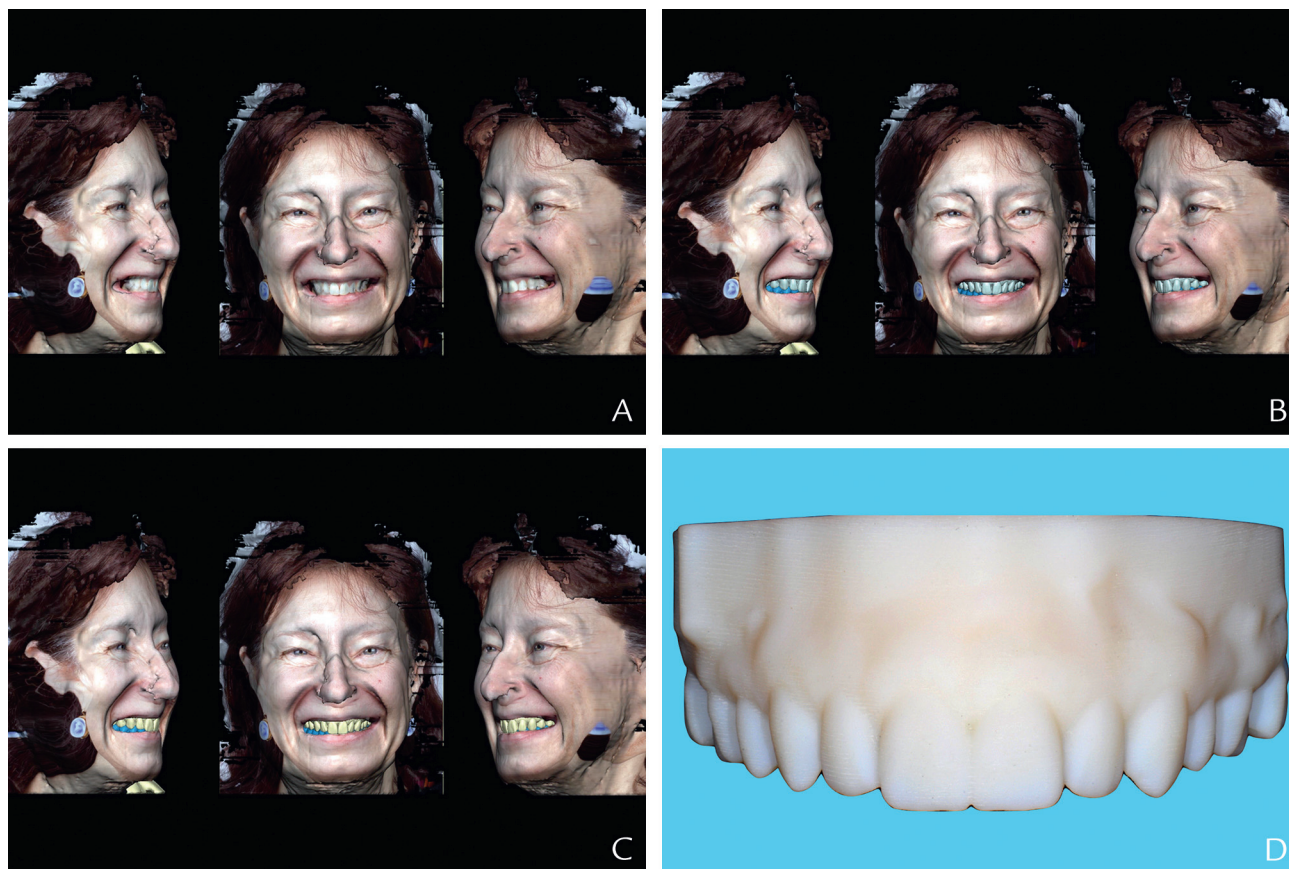


Figure 4. A, Three-dimensional virtual patient of photorealistic appearance at full smile, shown from mid-facial and right and left 45-degree views. B, Digital intraoral scan merged with 3D virtual patient. C, Virtual diagnostic waxing created in 3D virtual patient. D, CAD-CAM cast fabricated from approved virtual diagnostic waxing.

when collecting extraoral digital photographs and facial scans to improve the accuracy of the registration procedure for the virtual patient.^{30,31} Furthermore, since the intraoral scan needs to be merged with the virtual patient using the remaining teeth, the visibility of the labial surface of the remaining dentition at full smile is important.^{30,31}

SUMMARY

The clinical report describes a digital workflow using a static 3D virtual patient in conjunction with the virtual smile design approach to restore maxillary central incisors with CAD-CAM monolithic lithium disilicate ceramic veneers.

REFERENCES

1. Davis NC. Smile design. *Dent Clin North Am* 2007;51:299-318.
2. Lombardi RE. The principles of visual perception and their clinical application to denture esthetics. *J Prosthet Dent* 1973;29:358-82.
3. Levin EI. Dental esthetics and the golden proportion. *J Prosthet Dent* 1978;40:244-52.
4. Frese C, Staehle HJ, Wolff D. The assessment of dentofacial esthetics in restorative dentistry: a review of the literature. *J Am Dent Assoc* 2012;143:461-6.
5. Goodlin R. Photographic-assisted diagnosis and treatment planning. *Dent Clin North Am* 2011;55:211-27.
6. Morley J, Eubank J. Macroesthetic elements of smile design. *J Am Dent Assoc* 2001;132:39-45.
7. Bidra AS. Three-dimensional esthetic analysis in treatment planning for implant-supported fixed prosthesis in the edentulous maxilla: review of the esthetics literature. *J Esthet Restor Dent* 2011;23:219-36.
8. Tjan AH, Miller GD, The JG. Some esthetic factors in a smile. *J Prosthet Dent* 1984;51:24-8.
9. McLaren EA, Garber DA, Figueira J. The Photoshop Smile Design technique (part 1): digital dental photography. *Compend Contin Educ Dent* 2013;34:772-6.
10. Bhuvaneshwar M. Principles of smile design. *J Conserv Dent* 2010;13:225-32.
11. Ackerman MB, Ackerman JL. Smile analysis and design in the digital era. *J Clin Orthod* 2002;36:221-36.
12. Coachman C, Calamita MA. Digital smile design: a tool for treatment planning and communication in esthetic dentistry. *Quintessence Dent Technol* 2012;35:103-11.
13. Pimentel W, Teixeira ML, Costa PP, Jorge MZ, Tiossi R. Predictable outcomes with porcelain laminate veneers: a clinical report. *J Prosthodont* 2016;25:335-40.
14. Lin WS, Zandinejad A, Metz MJ, Harris BT, Morton D. Predictable restorative work flow for computer-aided design/computer-aided manufacture-fabricated ceramic veneers utilizing a virtual smile design principle. *Oper Dent* 2015;40:357-63.
15. Arias DM, Trushkowsky RD, Brea LM, David SB. Treatment of the patient with gummy smile in conjunction with digital smile approach. *Dent Clin North Am* 2015;59:703-16.
16. Coachman C, Calamita MA, Coachman FG, Coachman RG, Sesma N. Facially generated and cephalometric guided 3D digital design for complete mouth implant rehabilitation: a clinical report. *J Prosthet Dent* 2017;117:577-86.

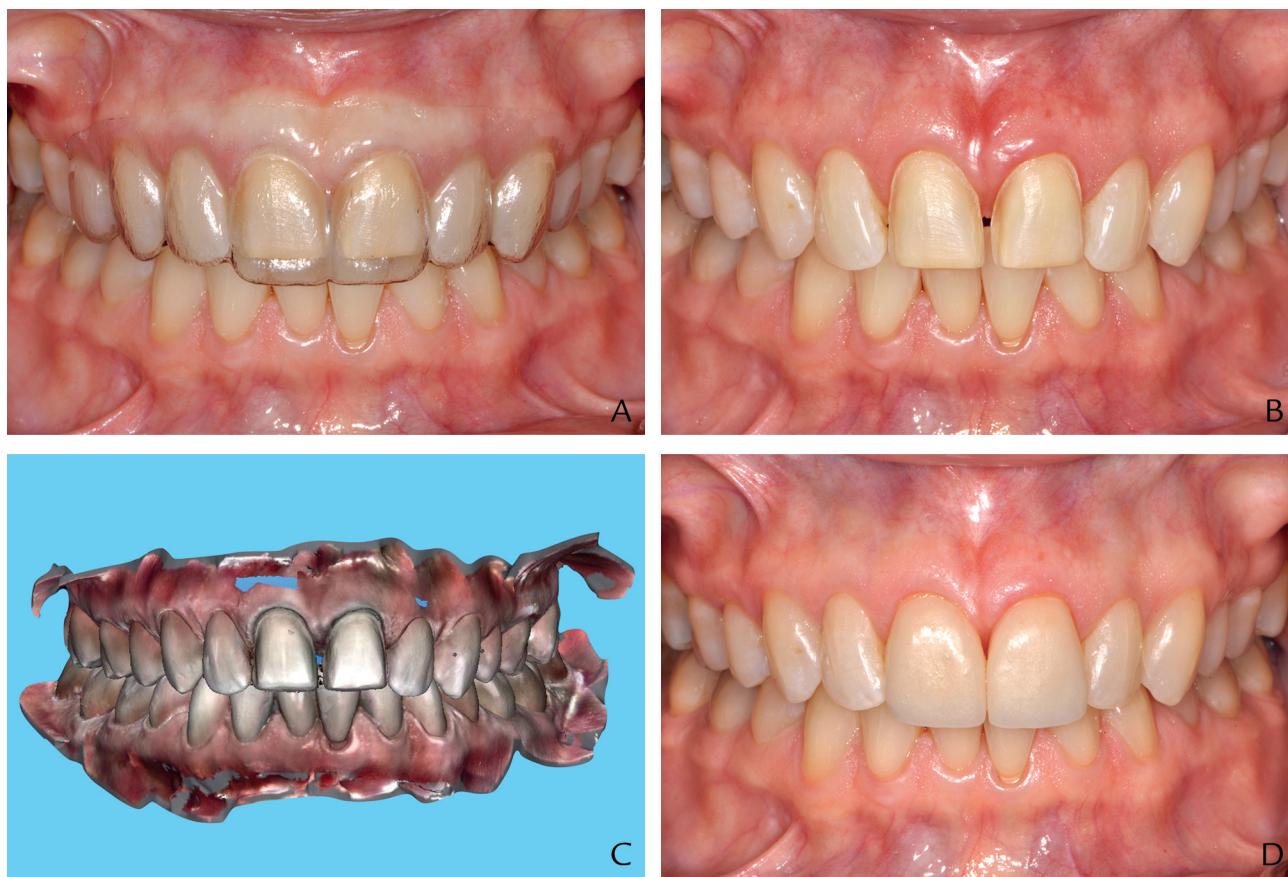

Figure 5. A, Teeth prepared with vacuum-formed matrix guidance. B, Completed tooth preparations. C, Definitive impression made with intraoral scanner. D, Interim veneers.

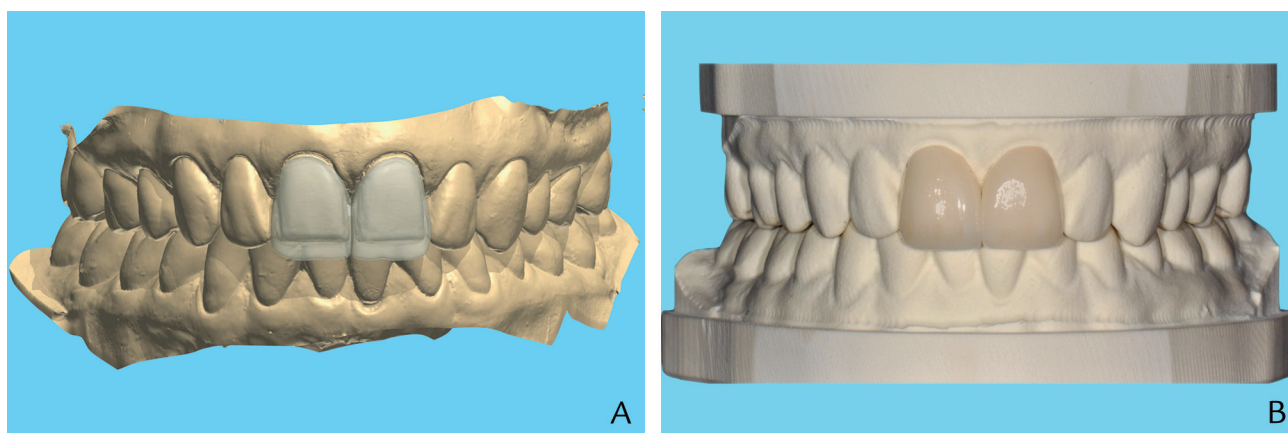


Figure 6. A, Design of CAD-CAM definitive lithium disilicate ceramic veneers. B, CAD-CAM definitive ceramic veneers after external characterization and glazing.

17. Zimmermann M, Mehl A. Virtual smile design systems: a current review. *Int J Comput Dent* 2015;18:303-17.
18. Joda T, Brägger U, Gallucci G. Systematic literature review of digital three-dimensional superimposition techniques to create virtual dental patients. *Int J Oral Maxillofac Implants* 2015;30:330-7.
19. Ting-Shu S, Jian S. Intraoral digital impression technique: a review. *J Prosthodont* 2015;24:313-21.
20. Ayoub AF, Xiao Y, Khambay B, Siebert JP, Hadley D. Towards building a photo-realistic virtual human face for craniomaxillofacial diagnosis and treatment planning. *Int J Oral Maxillofac Surg* 2007;36:423-8.
21. Kau CH. Creation of the virtual patient for the study of facial morphology. *Facial Plast Surg Clin North Am* 2011;19:615-22.
22. Tzou CH, Frey M. Evolution of 3D surface imaging systems in facial plastic surgery. *Facial Plast Surg Clin North Am* 2011;19:591-602.
23. Schendel SA, Duncan KS, Lane C. Image fusion in preoperative planning. *Facial Plast Surg Clin North Am* 2011;19:577-90.
24. Jayaratne YS, McGrath CP, Zwahlen RA. How accurate are the fusion of cone-beam CT and 3-D stereophotographic images? *PLoS One* 2012;7:e49585.
25. Maal TJ, Plooi JM, Rangel FA, Mollemans W, Schutyser FA, Bergé SJ. The accuracy of matching three-dimensional photographs with skin surfaces

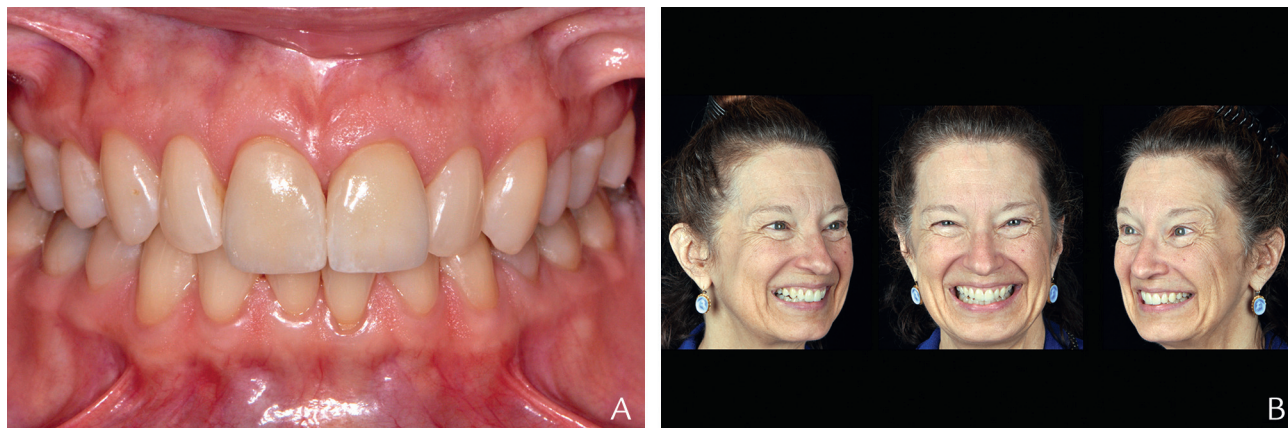


Figure 7. Post treatment. A, Intraoral view at maximum incusation position. B, Extraoral photographs at full smile from mid-facial and right and left 45-degree views.

- derived from cone-beam computed tomography. *Int J Oral Maxillofac Surg* 2008;37:641-6.
26. Naudi KB, Benramadan R, Brocklebank L, Ju X, Khambay B, Ayoub A. The virtual human face: superimposing the simultaneously captured 3D photo-realistic skin surface of the face on the untextured skin image of the CBCT scan. *Int J Oral Maxillofac Surg* 2013;42:393-400.
 27. Rosati R, De Menezes M, Rossetti A, Sforza C, Ferrario VF. Digital dental cast placement in 3-dimensional, full-face reconstruction: a technical evaluation. *Am J Orthod Dentofacial Orthop* 2010;138:84-8.
 28. Bechtold TE, Göz TG, Schaupp E, Koos B, Godt A, Reinert S, et al. Integration of a maxillary model into facial surface stereophotogrammetry. *J Orofac Orthop* 2012;73:126-37.
 29. Codari M, Pucciarelli V, Tommasi DG, Sforza C. Validation of a technique for integration of a digital dental model into stereophotogrammetric images of the face using cone-beam computed tomographic data. *Br J Oral Maxillofac Surg* 2016;54:584-6.
 30. Hassan B, Gimenez Gonzalez B, Tahmaseb A, Greven M, Wismeijer D. A digital approach integrating facial scanning in a CAD-CAM workflow for complete-mouth implant-supported rehabilitation of patients with edentulism: a pilot clinical study. *J Prosthet Dent* 2017;117:486-92.
 31. Harris BT, Montero D, Grant GT, Morton D, Llop DR, Lin WS. Creation of a 3-dimensional virtual dental patient for computer-guided surgery and CAD-CAM interim complete removable and fixed dental prostheses: a clinical report. *J Prosthet Dent* 2017;117:197-204.
 32. Edelhoff D, Liebermann A, Beuer F, Stimmelmayer M, Güth JF. Minimally invasive treatment options in fixed prosthodontics. *Quintessence Int* 2016;47:207-16.
 33. Culp L, McLaren EA. Lithium disilicate: the restorative material of multiple options. *Compend Contin Educ Dent* 2010;31:716-25.
 34. Zarone F, Ferrari M, Mangano FG, Leone R, Sorrentino R. Digitally oriented materials: focus on lithium disilicate ceramics. *Int J Dent* 2016;2016:9840594.
 35. Soares PV, Spini PH, Carvalho VF, Souza PG, Gonzaga RC, Tolentino AB, et al. Esthetic rehabilitation with laminated ceramic veneers reinforced by lithium disilicate. *Quintessence Int* 2014;45:129-33.
 36. Morimoto S, Albanesi RB, Sesma N, Agra CM, Braga MM. Main clinical outcomes of feldspathic porcelain and glass-ceramic laminate veneers: a systematic review and meta-analysis of survival and complication rates. *Int J Prosthodont* 2016;29:38-49.
 37. Sulaiman TA, Delgado AJ, Donovan TE. Survival rate of lithium disilicate restorations at 4 years: A retrospective study. *J Prosthet Dent* 2015;114:364-6.
 38. Baba NZ, Goodacre CJ, Jekki R, Won J. Gingival displacement for impression making in fixed prosthodontics: contemporary principles, materials, and techniques. *Dent Clin North Am* 2014;58:45-68.

Corresponding author:

Dr Wei-Shao Lin
University of Louisville
501 South Preston St
Louisville, KY 40292
Email: WeiShao.Lin@Louisville.edu

Copyright © 2017 by the Editorial Council for *The Journal of Prosthetic Dentistry*.