

CLINICAL REPORT

Oral rehabilitation with implant-supported fixed dental prostheses of a patient with cleidocranial dysplasia



Fethi Atil, DDS, PhD,^a Ahmet Culhaoglu, DDS, PhD,^b Ismail Doruk Kocyigit, DDS, PhD,^c Zahit Adisen, DDS, PhD,^d Melda Misirlioglu, DDS, PhD,^e and Burak Yilmaz, DDS, PhD^f

Cleidocranial dysplasia (CCD) is a genetic skeletal disorder characterized by skeletal alterations at numerous bone segments and typical hyperdontia. The presence of numerous supernumerary teeth can prevent the eruption of normal teeth.^{1,2} Accordingly, functional problems and undesirable orofacial appearance are common disorders of patients with CCD.³

The therapeutic approach for patients with CCD should focus on satisfying esthetic and masticatory function.^{3,4} Although patients commonly went without treatment in the past, new and successful treatment options for CCD have been reported.⁵ Various therapeutic approaches including surgery and orthodontic and prosthetic treatment are possible ways of restoring a correct architecture for the alveolar-dental arches.⁶

After extracting supernumerary and malformed teeth,^{2,7} the surgical exposure of well-developed unerupted teeth and their repositioning with successful orthodontic treatment has been reported.⁸⁻¹⁰ However, in some situations, orthodontic treatment may not be possible, and prosthetic treatment may remain the only option. Teeth that are ideal for retention can be used to support the prostheses.^{11,12} The successful use of dental implants to support a removable or fixed dental prosthesis (FDP) has also been reported in patients with CCD.^{7,13,14} Generally, surgical therapy is inevitable, whether the treatment is accomplished with orthodontic

ABSTRACT

This clinical report describes the oral rehabilitation with implant-supported fixed dental prostheses in the maxilla and mandible of a patient with cleidocranial dysplasia. Cone-beam computed tomography and a tilted implant protocol in the mandible helped to establish a conservative approach for bone preservation, prevent surgical complications, enable proper implant positioning to avoid anatomic structures, and support the fixed dental prostheses. (J Prosthet Dent 2018;119:12-16)

treatment, prosthetic treatment or both. Surgical extraction of supernumerary teeth may be complex and invasive.^{1,2,15} Therefore, locating the position of impacted supernumerary teeth is essential before surgery to avoid complications including bleeding, paresthesia, and fractures.¹⁶ Advanced imaging techniques have been advantageous in these situations, and cone beam computed tomography (CBCT) with dental software programs are recommended for detecting and evaluating the pathologies in the maxillofacial region.¹⁷⁻¹⁹

An interdisciplinary treatment approach for a patient with CCD is presented involving radiology, maxillofacial surgery, and prosthodontics. Three-dimensional (3D) CBCT guidance was used to detect the positions of impacted supernumerary teeth and to evaluate the bone volume, followed by template-guided implant placement and the delivery of an implant-supported FDP.

CLINICAL REPORT

A 48-year-old woman with CCD presented at the oral and maxillofacial surgery and prosthodontics departments for an examination. The patient had no history

^aAssistant Professor, Department of Oral & Maxillofacial Surgery, Faculty of Dentistry, Kirikkale University, Kirikkale, Turkey.

^bAssistant Professor, Department of Prosthodontics, Faculty of Dentistry, Kirikkale University, Kirikkale, Turkey.

^cAssociate Professor, Department of Oral & Maxillofacial Surgery, Faculty of Dentistry, Kirikkale University, Kirikkale, Turkey.

^dAssistant Professor, Department of Oral & Maxillofacial Radiology, Faculty of Dentistry, Kirikkale University, Kirikkale, Turkey.

^eAssistant Professor, Department of Oral & Maxillofacial Radiology, Faculty of Dentistry, Kirikkale University, Kirikkale, Turkey.

^fAssociate Professor, Division of Restorative Science and Prosthodontics, College of Dentistry, The Ohio University Dentistry, Columbus, Ohio.

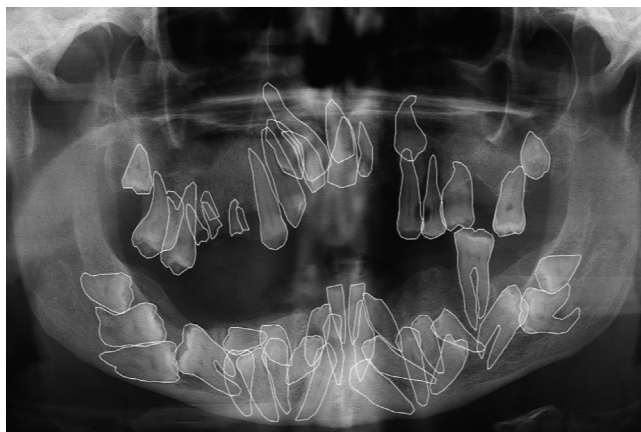


Figure 1. Panoramic radiograph before treatment revealing 46 teeth.

of systemic disease or drug allergies and was not receiving any medication. She had no contraindications for dental treatment. The patient's chief complaint was the lack of masticatory capability resulting from missing (impacted) teeth and poor esthetics. A panoramic radiograph (Fig. 1) and CBCT images were captured using digital imaging technology (PaxUni 3D, Vatech; CBCT settings: 50-90 kVp, 4-10 mA, 10-second exposure time). Files in Digital Imaging and Communications in Medicine (DICOM) format were transferred to a medical image-processing program (ITK-SNAP 2.4.0). Three views (coronal, sagittal, and axial) were used to define the boundaries of the structures. Manual segmentation was performed by an oral radiologist (Z.A.) with drawings of teeth, bone, and mandibular canal on each CBCT slice (Fig. 2). The 3D models for the bone volume and teeth were obtained to select the most favorable approach for surgical extraction of impacted teeth and were evaluated by an oral and maxillofacial surgeon (D.K.), radiologist (M.M.), and prosthodontist (A.C.). Possible treatment alternatives were explained to the patient in detail. The patient chose a treatment plan including implant-supported FDPs after extraction of the teeth.

Surgical extractions of impacted teeth at potential implant sites were performed under general anesthesia with the guidance of 3D CBCT images in 4 hours. A total of 32 teeth were extracted, and bone defects were repaired with bone grafts. Corticocancellous block grafts from iliac bone were fixed using screws, and the macrogaps were filled with cancellous bone particles from iliac bone. No membrane was used. The patient did not opt to have an interim prosthesis during the osseointegration period. Follow-up examination was uneventful. The patient was placed on periodic recall for further implant treatment (Figs. 3-5).

After 4 months of healing, maxillary and mandibular alginate impressions were made and the casts were poured in Type III dental stone (Microstone; Whip Mix

Corp). Acrylic resin base plates and wax rims were fabricated, and maxillomandibular relationship and facebow records were made. A diagnostic tooth arrangement was made for both the maxilla and mandible, and acrylic resin complete dental prostheses were processed from heat-polymerized acrylic resin. Conventional surgical guides/templates were fabricated duplicating the complete dental prostheses in an auto-polymerizing acrylic resin (Ortho-Jet; Lang Dental).

Minimally invasive, template-guided implant surgery was used for the maxilla and mandible. Six implants were placed in the maxilla and 4 implants in the mandible using the tilted implant protocol (T4; NucleOSS) (Fig. 6). Multiunit abutments (T4; NucleOSS) were screwed onto the implants to 35 Ncm, and interim copings were tightened onto the abutments. Holes were prepared corresponding to implant positions using acrylic resin rotary instruments. After the passive seating of complete dental prostheses was ensured, the interim copings were picked up in the prostheses by injecting acrylic resin between the copings and holes in the complete dentures. The flanges of the prostheses and the intaglio surface were adjusted to convert the prostheses to fixed implant-supported prostheses. Occlusal adjustments were performed, and the patient was advised to strictly follow a soft diet for 12 weeks. After 4 months of healing, multiunit abutment impression copings (T4; NucleOSS implants) were splinted with dental floss and an auto-polymerizing acrylic resin (Pattern Resin Ls; GC Corp) using the brush-bead technique. Open-tray abutment-level definitive impressions of the maxilla and mandible were made with a polyether impression material (Impregum; 3M ESPE).

Maxillary and mandibular base plates and wax rims were fabricated to record the maxillomandibular relationship. A semiadjustable articulator (Artex; Amann Girrbach AG) and a facebow were used to transfer interocclusal records. Maxillary and mandibular diagnostic tooth arrangements were prepared for a clinical evaluation to determine tooth positions, to evaluate phonetics and esthetics, and to establish the maxillomandibular relationship. FDP frameworks were designed according to the diagnostic tooth arrangement and cast from cobalt-chromium alloy (Robur 400; Eisenbacher Dentalwaren) for both the maxilla and mandible. The passive fit of the cast metal frameworks was determined using the 1-screw test and from radiographs.²⁰ Composite resin and acrylic resin denture teeth (Visiolog; Bredent GmbH) were used to veneer the cast metal frameworks. A canine-protected occlusal relation was established.²¹ The prostheses were processed in heat-polymerized acrylic resin after clinical evaluation. Occlusal adjustments were made, and the pontic-mucosa relationship was adjusted for proper contours to enable hygiene procedures using acrylic resin

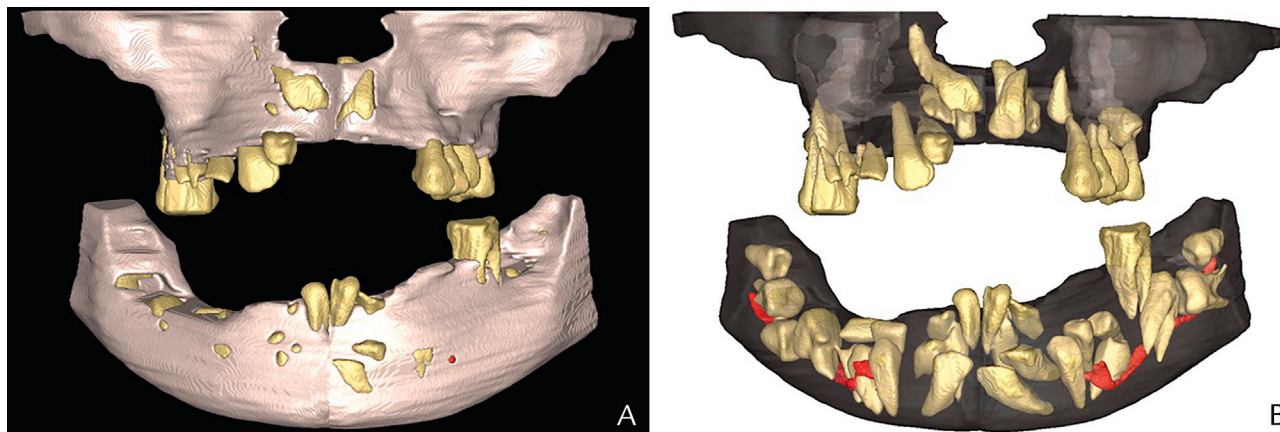


Figure 2. Segmented 3-dimensional images. A, Bone. B, Teeth and mandibular canal.

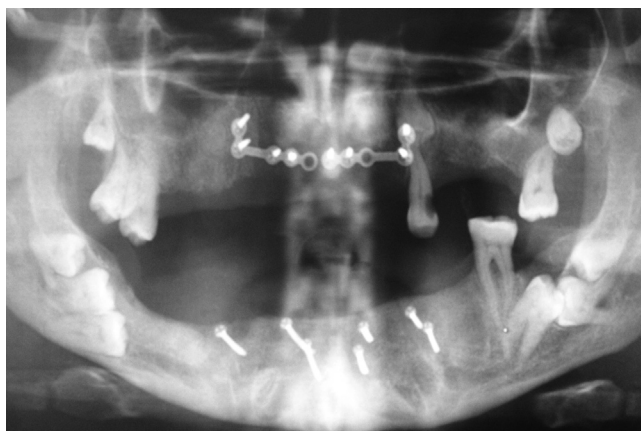


Figure 3. Panoramic radiograph after extractions and grafting.

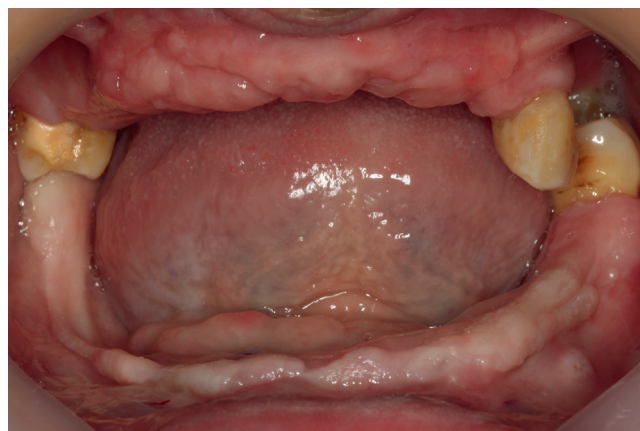

Figure 4. Intraoral view after extractions.

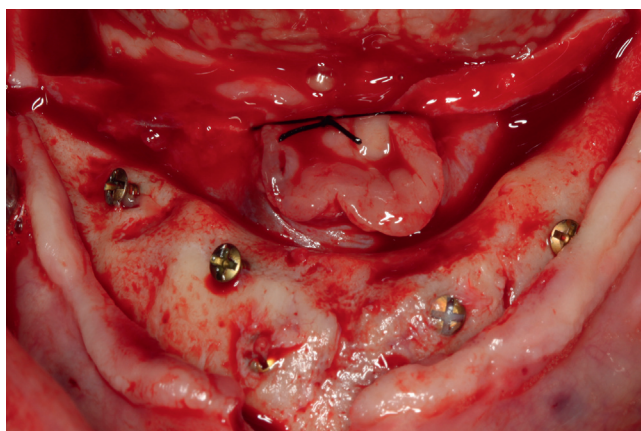


Figure 5. After extractions and bone grafting.

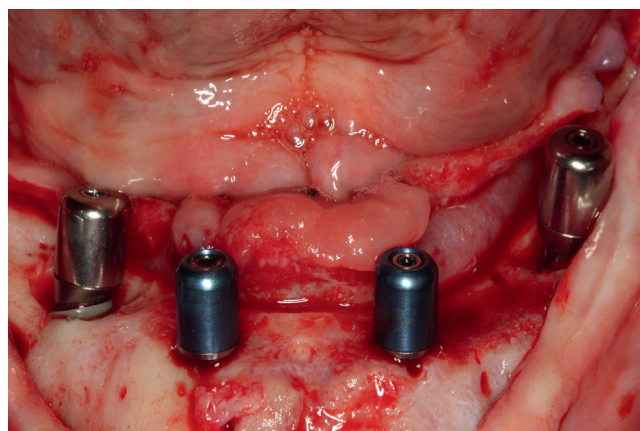


Figure 6. Mandibular implants placed using tilted implant protocol.

burs, and surfaces were polished with pumice. After the prosthesis adjustments had been completed, the prosthetic screws were tightened to 15 Ncm. A light-polymerizing composite resin was used to seal screw access channels. Oral hygiene instructions were given, and the patient was placed on recall visits for periodontal maintenance (Figs. 7-9).

DISCUSSION

Rehabilitation of an individual with CCD may be difficult and require an experienced surgical and prosthodontic team with proper collaboration.¹⁴ In the current situation, the patient did not choose orthodontic extrusion of impacted teeth. Also, complete extractions of impacted

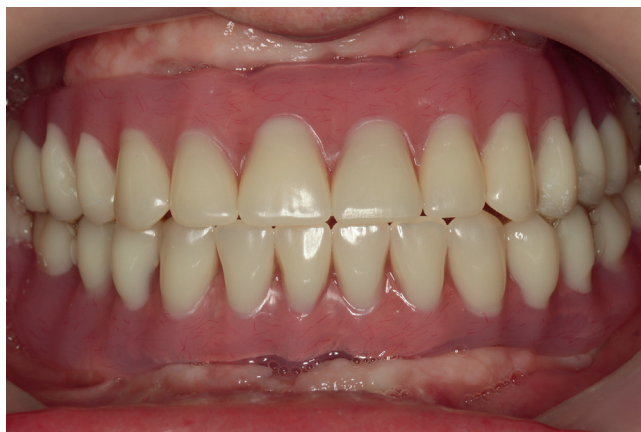

Figure 7. Definitive prostheses, intraoral view.

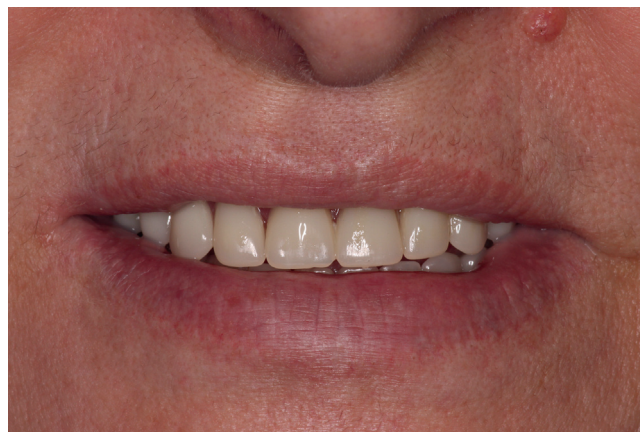

Figure 8. Definitive prostheses, extraoral view.

teeth was not done because of the fracture risk of the remaining bone after extractions.²² Considering these factors, only impacted teeth in the anterior and premolar region were extracted to allow space for implants, and these sites were grafted to avoid severe bone loss. In addition, both of the second molars were kept in the mouth until definitive prostheses were made to preserve proprioception and the occlusal relationship. These teeth were also used to support the interim removable dental prostheses.

Prosthetic treatment planning for patients with CCD can be complicated by several host factors. A limited number of situations have been reported about the rehabilitation with implants of patients with CCD, considering that a genetic defect may negatively affect the osteoblastic activity around implants.¹⁴ However, some reports document bone formation after orthodontically erupting teeth with patients with CCD, demonstrating that implant therapy can be an option.^{4,14} Implant-supported FDPs can be beneficial for the prevention of bone resorption and provision of comfort through stable prostheses.²³

The tilted implant protocol was an alternative for the mandible and enabled a fixed prosthesis for the edentulous arch. This protocol also offered rehabilitation in the presence of minimal bone volume.^{24,25} Two distally angled implants placed in the posterior premolar region and axially placed anterior implants provided the support for the FDPs. Positioning the implants as described helped avoid surgical interventions near the mandibular canal. Moreover, bone structure was preserved by not removing posterior impacted teeth to gain space for implants, which could have traumatized the neurovascular bundle and jaw continuity.

To the authors' knowledge, no published articles have reported the use and benefits of the tilted implant protocol with CCD patients. Unerupted teeth are a common threat to the maintenance and continuity of dental health in dental practice. Radiologic examination is a basic

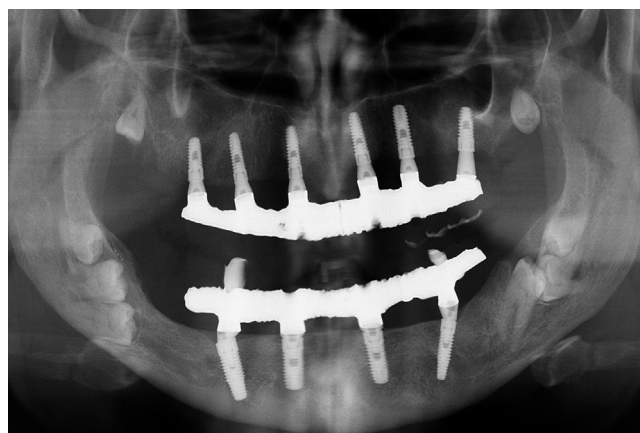


Figure 9. Posttreatment panoramic radiograph.

method for the diagnosis and location of impacted teeth.¹⁷ Although a combination of periapical and cross-sectional occlusal radiographs is adequate for necessary information for the buccolingual position of an impacted tooth, using CBCT may become essential for evaluating the 3D position of multiple impacted teeth.¹⁶⁻¹⁸ In the presented situation, CBCT images allowed the 3D views of the impacted supernumerary teeth in relation to other anatomic structures, enhancing accurate management of the treatment. Also, 3D information about the impacted teeth has played an important role during surgical procedures, reducing the time needed for operations. Overall, understanding the conditions and positions of impacted teeth before surgical extractions using 3D images from the CBCT scan was an important aid when treatment was planned in the current situation. The virtual treatment planning for extractions prevented risks related with anatomic structure damage. The impacted molars were not removed, and the patient did not experience any paresthesia after grafting or after implant placement.

In the current situation, surgical and prosthetic treatment planning met the expectations of the patient

despite the adverse conditions of CCD. Long-term studies and more clinical reports are needed to determine the ideal therapeutic approach for CCD patients.

SUMMARY

A patient with CCD and erupted and unerupted teeth was in need of an interdisciplinary dental approach to restore her function and esthetics. A surgical and prosthetic approach was used to deliver implant-supported FDPs in the maxilla and mandible. A CBCT-enabled 3D examination was used to detect the positions of multiple unerupted teeth and their relationship with anatomic structures, and to evaluate the bone volume. CBCT-guided extractions, iliac bone graft on the maxilla and mandible, and particularly the use of a tilted implant placement protocol enhanced the surgeon's and prosthodontist's ability to preserve the remaining bone and to plan and properly place the implants and deliver functional and esthetic prostheses.

REFERENCES

1. Mortellaro C, Greco LA, Prota E. Differing therapeutic approaches to cleidocranial dysplasia. *Minerva Stomatol* 2012;61:155-63.
2. Suba Z, Balaton G, Gyulai-Gaál S, Balaton P, Barabás J, Tarján I. Cleidocranial dysplasia: diagnostic criteria and combined treatment. *J Craniofac Surgery* 2005;16:1122-6.
3. Roberts T, Stephen L, Beighton P. Cleidocranial dysplasia: a review of the dental, historical, and practical implications with an overview of the South African experience. *Oral Surg Oral Med Oral Pathol Oral Radiol* 2013;115:46-55.
4. Becker A, Lustmann J, Shteyer A. Cleidocranial dysplasia. Part 1-general principles of the orthodontic and surgical treatment modality. *Am J Orthod Dentofac Orthop* 1997;111:28-33.
5. Becker A. Orthodontic treatment of impacted teeth. Hoboken: John Wiley & Sons; 2012. p. 370-405.
6. Kuroda S, Yanagita T, Kyung HM, Takano-Yamamoto T. Titanium screw anchorage for traction of many impacted teeth in a patient with cleidocranial dysplasia. *Am J Orthod Dentofac Orthop* 2007;131:666-9.
7. Angle AD, Rebello J. Dental team management for a patient with cleidocranial dysostosis. *Am J Orthod Dentofac Orthop* 2005;128:110-7.
8. Becker A, Shteyer A, Bimstein E, Lustmann J. Cleidocranial dysplasia. Part 2: treatment protocol for the orthodontic and surgical modality. *Am J Orthod Dentofac Orthop* 1997;111:173-83.
9. Nordenram A. Autotransplantation of teeth in cleidocranial dysostosis. *Odontol Revy* 1971;22:363.
10. Bishop R. Dental management of cleido-cranial dysostosis. Case report. *Aust Dent J* 1984;29:1-4.
11. Caminiti MF, Sandor GK, Giambattistini C, Tompson B. Outcomes of the surgical exposure, bonding and eruption of 82 impacted maxillary canines. *J Can Dent Assoc* 1998;64:572-9.
12. Kelly E, Nakamoto RY. Cleidocranial dysostosis-a prosthodontic problem. *J Prosthet Dent* 1974;31:518-26.
13. Lombardas P, Toothaker R. Bone grafting and osseointegrated implants in the treatment of cleidocranial dysplasia. *Compend Contin Educ Dent* 1997;18:509-14.
14. Petropoulos VC, Balshi TJ, Balshi SF, Wolfinger GJ. Treatment of a patient with cleidocranial dysplasia using osseointegrated implants: a patient report. *Int J Maxillofac Implants* 2003;19:282-7.
15. Brauer H. Non-syndromic multiple supernumerary teeth localized by cone beam computed tomography. *Eur Arch Paediatr Dent* 2010;11:41-3.
16. Sato K, Sugawara J, Mitani H, Kawamura H. Use of selectively colored stereolithography for diagnosis of impacted supernumerary teeth for a patient with cleidocranial dysplasia. *Int J Adult Orthodon Orthognath Surg* 1997;18:563-7.
17. Gopinath A, Reddy NA, Rohra MG. 3 Dimensional diagnosis unravelling prognosis of multiple impacted teeth-a case report. *J Int Oral Health* 2013;5:78-83.
18. Sutthiprapaporn P, Kongsomboon S, Pisek P. Use of cone-beam CT in a patient with cleidocranial dysplasia dramatically reduced the operation time. *Oral Radiol* 2010;26:52-5.
19. Nakagawa Y, Kobayashi K, Ishii H, Mishima A, Asada K, Ishibashi K. Pre-operative application of limited cone beam computerized tomography as an assessment tool before minor oral surgery. *Int J Oral Maxillofac Surg* 2002;31:322-7.
20. Abduo J, Bennani V, Waddell N, Lyons K, Swain M. Assessing the fit of implant fixed prostheses: a critical review. *Int J Oral Maxillofac Implants* 2010;25:506-15.
21. Hobkirk JA, Watson RM, Albrektsson T, Forman G, Zarb G. Color atlas and text of dental and maxillo-facial implantology. St Louis: Mosby-Wolfe; 1995. p. 32-5.
22. Scotti R, Melilli D, Pizzo G. Overdenture supported by natural teeth: analysis of clinical advantages. *Minerva Stomatol* 2003;52:201-10.
23. Schnutenhaus S, Luthardt RG, Rudolph H, Götz W. Histological examination and clinical evaluation of the jawbone of an adult patient with cleidocranial dysplasia: a case report. *Int J Clin Exp Pathol* 2015;8:8521-31.
24. Maló P, Rangert B, Nobre M. All-on-4 immediate-function concept with Brånemark System® implants for completely edentulous maxillae: a 1-year retrospective clinical study. *Clin Implant Dent Relat Res* 2005;7:88-94.
25. Patzelt S, Bahat O, Reynolds MA, Strub JR. The all-on-four treatment concept: a systematic review. *Clin Implant Dent Relat Res* 2014;16:836-55.

Corresponding author:

Dr Burak Yilmaz
The Ohio State University College of Dentistry
Division of Restorative Sciences and Prosthodontics
Postle Hall
305 W 12th Ave
Columbus, OH 43210
Email: yilmaz.16@osu.edu

Copyright © 2017 by the Editorial Council for *The Journal of Prosthetic Dentistry*.