

CLINICAL REPORT

CAD-CAM implant-supported fixed complete dental prosthesis with titanium milled molars: A clinical report



Abdulaziz AlHelal, BDS, MS,^a Bader AlBader, BDS,^b Mathew T. Kattadiyil, BDS, MDS, MS,^c
Antoanela Garbacea, DDS, MSD,^d and Periklis Proussaefs, DDS, MS^e

Dental implants were first introduced to treat patients with complete edentulism in order to stabilize their complete dentures.¹ Later, with the introduction of multiple implants, the implant-supported fixed complete dental prosthesis (ISFCDP) offered a prosthesis which had no contact with the underlying mucosa and was not removable by the patient.^{2,3} High survival rates have been associated with implant-supported ISFCDPs.²⁻⁴ For an ISFCDP, a framework is fabricated and secured onto implants with abutment screws, whereas the acrylic resin base and denture teeth are mechanically and chemically retained by the metal framework.⁵⁻⁷

Despite the high survival rates reported in several long-term studies,^{3,4,8-10} position papers,^{11,12} and systematic reviews,^{13,14} a high incidence of prosthetic or mechanical complications is associated with this type of prosthesis. Fracture of the metal framework^{3,4,11,12} and wear or fracture/chipping of the acrylic resin teeth^{8,9,11-15} have been reported as frequent complications associated with ISFCDPs.¹⁶⁻¹⁹

Purcell et al⁹ reported that the most frequent complications were fractures of the prosthetic acrylic resin teeth and wear. They stated that patients were 52.5 times more likely to need posterior replacement at 5 years than

ABSTRACT

Implant-supported fixed complete dental prostheses have been associated with a high implant success rate in long-term studies. However, they have also been associated with a high frequency of prosthetic complications. The most frequent and primary prosthetic complication has been the fracture or wear of the occlusal surface of acrylic resin teeth that are typically attached to a metal framework. The design of the framework in this clinical report involved the incorporation of metal occlusal surfaces for the posterior first molars to the framework. The titanium framework was fabricated with computer-aided design and computer-aided manufacturing (CAD-CAM) technology. The remaining teeth were restored in a conventional manner with acrylic resin denture teeth bonded to the titanium framework. This was expected to maintain the occlusal vertical dimension and also reduce the frequency of the primary complications associated with these prostheses. (*J Prosthet Dent* 2017;117:463-469)

at 2 years. Acrylic resin tooth wear with an ISFCDP becomes more evident when opposed by natural teeth, another ISFCDP, or with parafunctional activities.^{9,16,17} In their meta-analysis of ISFCDPs, Bozini et al¹³ reported a cumulative rate of material wear estimated at 17.3% after 5 years, 31.6% after 10 years, and 43.5% after 15 years.

Several options have been suggested to decrease the acrylic resin wear process, including altering the occlusal surfaces of the ISFCDP with gold or titanium⁸ onlays, amalgam alloy, or by using porcelain denture teeth,⁹ custom-milled zirconia teeth,²⁰⁻²² or individually cemented crowns on a metal framework.²³

Advances in computer-aided design and computer-aided manufacturing (CAD-CAM) technology have demonstrated superior accuracy of milled frameworks compared with conventionally fabricated frameworks.²⁴⁻²⁷

^aDepartment of Prosthetic Dental Sciences, College of Dentistry, King Saud University, Riyadh, Saudi Arabia.

^bCollege of Dentistry, University of Dammam, Dammam, Saudi Arabia.

^cProfessor and Director, Advanced Specialty Education Program in Prosthodontics, Loma Linda University School of Dentistry, Loma Linda, Calif.

^dAssistant Professor, Advanced Specialty Education Program in Prosthodontics and Implant Dentistry, Loma Linda University School of Dentistry, Loma Linda, Calif.

^eAssistant Professor, Advanced Specialty Education Program in Implant Dentistry, Loma Linda University School of Dentistry, Loma Linda, California, and private practice, Ventura, Calif.

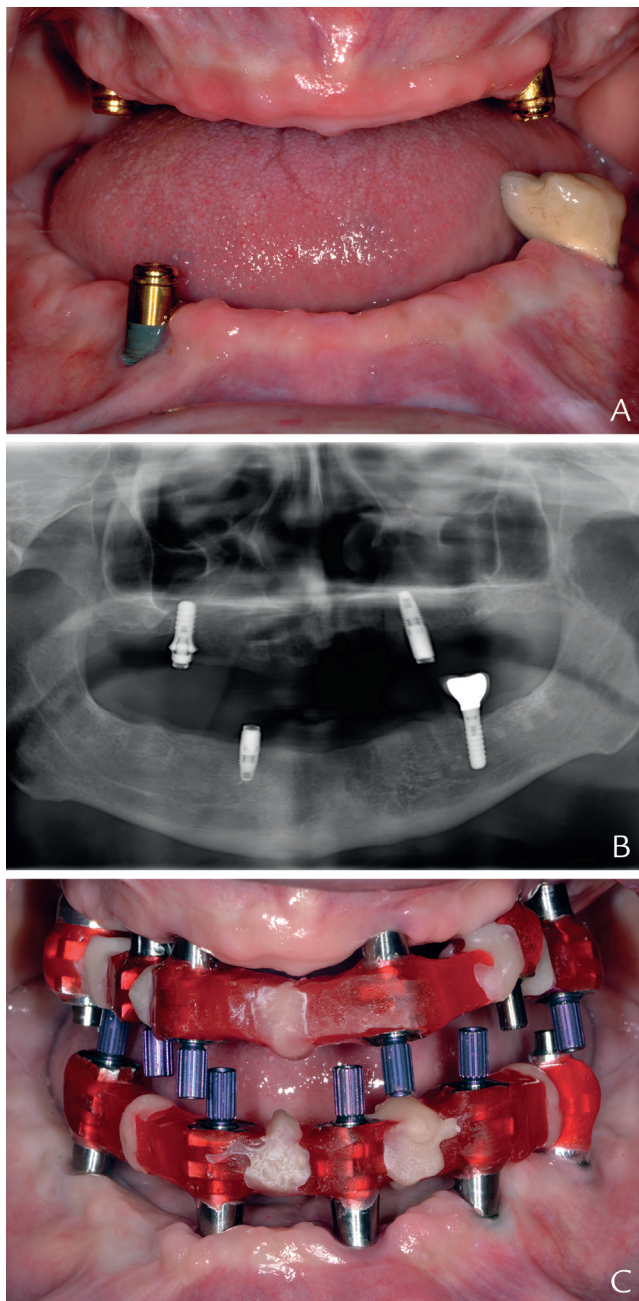


Figure 1. A, Intraoral frontal view of patient's preexisting condition. B, Preoperative panoramic radiograph of existing implants. C, Frontal view of splinted impression copings before impression making.

The purpose of this clinical report was to describe the fabrication of an ISFCDP with milled molar teeth as part of the CAD-CAM titanium framework. The molars were contoured so that their metal occlusal surface was in occlusion with the metal surface of the opposing teeth to resist occlusal wear and fracture, maintain occlusal vertical dimension, and reduce the rate of the remaining acrylic resin tooth wear.

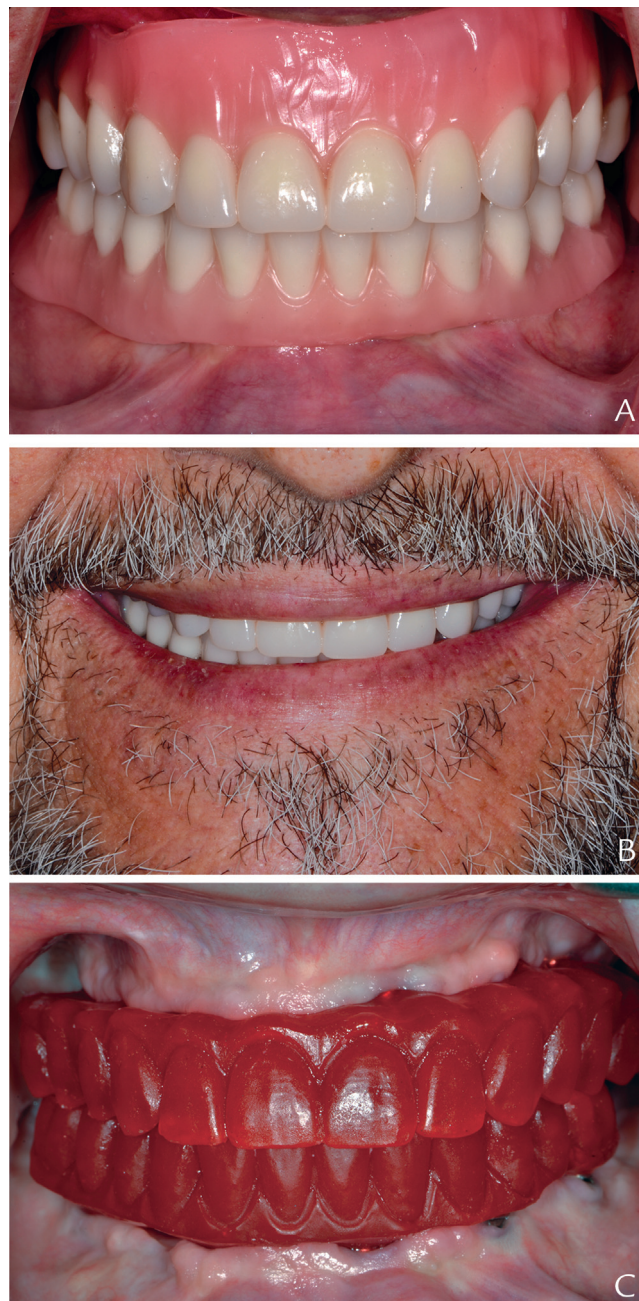

Figure 2. A, Intraoral frontal view of trial tooth placement before pattern resin duplication. B, Smile view of patient esthetics at trial placement. C, Intraoral view of pattern resin implant-supported fixed complete dental prostheses before cut back.

CLINICAL REPORT

A 60-year-old white man presented to Loma Linda University School of Dentistry for prosthodontic evaluation and treatment. The patient's chief complaint was "I am not satisfied with having to wear a removable denture." His medical history did not reveal any conditions. He was a smoker who consumed 2 packs of

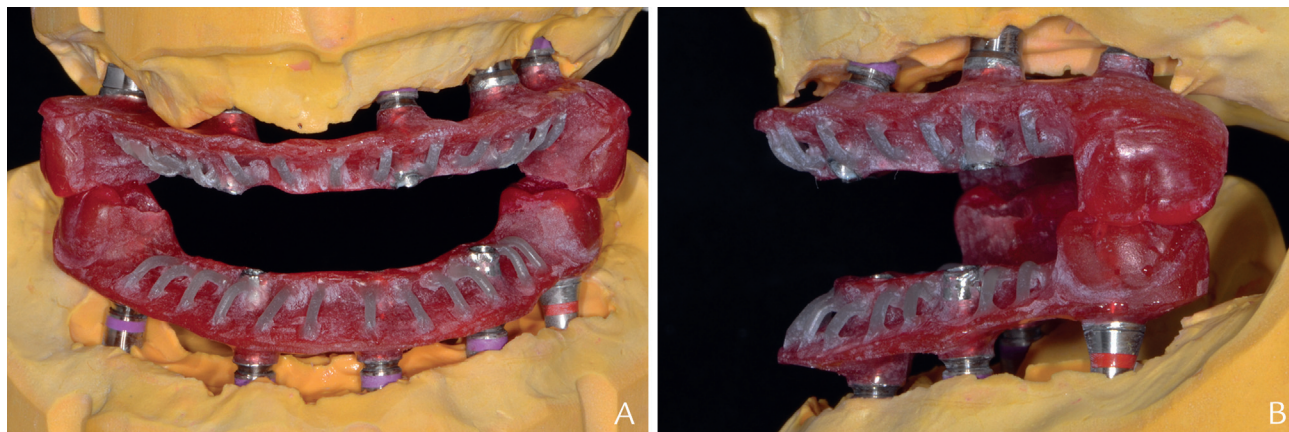


Figure 3. A, Frontal view of definitive framework design after cut back showing first molars in anatomic contour (at proposed occlusal vertical dimension). B, Lateral view of definitive framework design after cut back except for first molars.

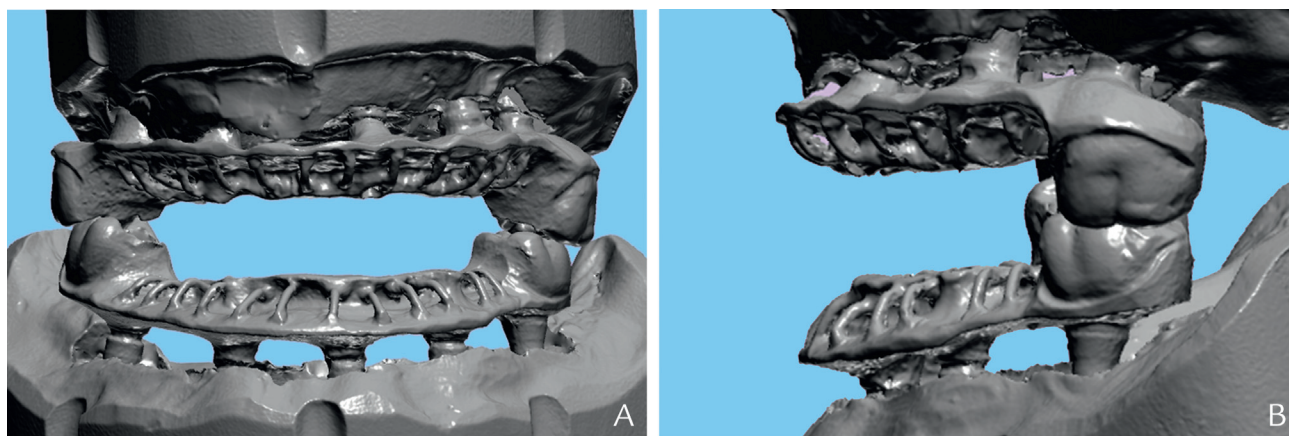


Figure 4. A, Virtual frontal view of proposed framework design after scanning. B, Virtual lateral view of proposed framework design after scanning.

cigarettes per week. He had been wearing implant-retained overdentures, which exhibited severe tooth wear after 3 years in function. A reduced occlusal vertical dimension was noticed with the existing maxillary and mandibular prosthesis in situ. Clinical and radiographic evaluation revealed dental implants in the area of the maxillary right first molar, maxillary left first premolar, mandibular left first molar, and mandibular right first premolar (Fig. 1A, B). After discussing various treatment options, the decision was made to fabricate ISFCDPs for both arches with the understanding that additional implants would be placed in both the maxillary and mandibular arches to provide adequate support for the proposed ISFCDPs.

Radiographic and intraoral examinations revealed excellent bone levels with good prognosis for the existing implants in the areas of the maxillary right first molar, maxillary left first premolar, and mandibular left first molar. However, an implant at the mandibular right first premolar had a poor prognosis because of periimplantitis.

New maxillary and mandibular complete dentures (CDs) were fabricated, and cone beam computed tomography imaging was done to analyze bone morphology, prosthetic space, and quantity of bone for implant placement.

Guided alveolar ridge reduction²⁸ was performed initially to remove the failing implant in the mandibular right first premolar area followed by placement of 4-root-form dental implants (Bone Level Roxolid SLActive; Straumann) in the mandibular arch at the area of the left first premolar, left lateral incisor, right lateral incisor, and right first molar. In the maxillary arch, 4 implants were placed in the areas of the right first premolar, right lateral incisor, left lateral incisor, and left first molar. The new maxillary and mandibular CDs were relieved, and the patient continued wearing them after implant surgery.

After 3 months of healing, definitive impressions were made with the direct splinting technique.^{29,30} Open-tray impression copings were used and intraorally splinted with light-polymerized composite resin (Filtek Supreme Ultra; 3M ESPE) (Fig. 1C).

Heavy-body polyvinyl siloxane impression material (Aquasil; Dentsply Sirona) was used with a custom-made tray made of light-polymerized acrylic resin (Tru Tray Sheet; Dentsply Sirona). The definitive cast was poured in Type IV dental stone (Resin Rock; Whip Mix Corp) with a simulated soft tissue material (GI-Mask; Coltène/Whaledent Inc). Record bases and occlusion rims were fabricated and retained with 2 implants in each arch (maxillary right incisor and left first molar, mandibular left lateral incisor, and right first molar). After adjustments were made to the occlusion rims for the appropriate occlusal vertical dimension (OVD), lip support, and visibility of teeth, facebow records and maxillomandibular relation records (centric relation and protrusive records) were made. The definitive casts were mounted on a semiadjustable articulator (Panadent Corp), and a trial denture tooth arrangement was made to achieve a bilateral, balanced occlusion. After assessing the trial dentures (Fig. 2A) and after patient approval of the esthetic outcome (Fig. 2B), a putty index was generated. A duplicate of the trial dentures was made with autopolymerizing acrylic resin (GC Pattern Resin; GC America Inc) with a previously generated putty index (Lab putty; Coltène/Whaledent Inc). Implant-supported, screw-retained maxillary and mandibular autopolymerizing acrylic resin prototypes of the fixed complete dental prostheses were placed intraorally to verify fit, adjust occlusion, and assess esthetics, phonetics, and accessibility for oral hygiene (Fig. 2C).

The acrylic resin prostheses were cut back, keeping just the first molars in complete contour at the planned OVD (Fig. 3). The modified and verified autopolymerizing acrylic resin prototypes were then scanned with an optical scanner (D900L; 3shape) (Fig. 4). A titanium framework was then milled (Procera; Nobel Biocare Inc) as an exact duplicate of the autopolymerizing acrylic resin prototypes (Fig. 5A, B). The metal framework at the trial placement was placed intraorally to verify and confirm fit³¹ and occlusion at the first molar area (Fig. 5C). A 1-screw test in conjunction with radiographs was used to confirm fit.³¹

Subsequently, the tooth arrangement was transferred using the previously generated putty index. At this stage, repositioning the canines occlusally to achieve a canine-protected occlusion modified the bilateral balanced occlusal scheme. Simultaneous occlusal contacts in centric occlusion between molars made from titanium alloy and acrylic resin teeth were confirmed. The wax trial prosthesis with the metal frameworks was evaluated intraorally, and patient approval for esthetics, phonetics, and function was obtained. The ISFCDPs were processed in a conventional manner with heat-polymerized acrylic resin (Lucitone 199; Dentsply Sirona) (Fig. 6).

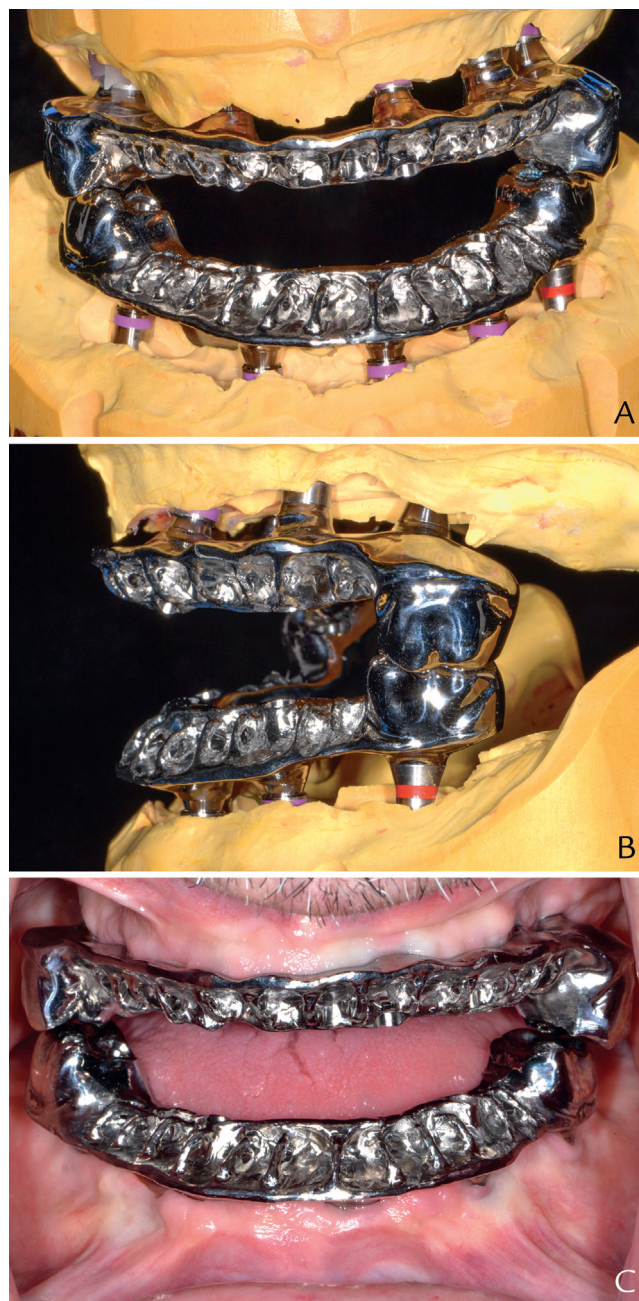


Figure 5. A, Frontal view of milled proposed framework design. B, Lateral view of milled proposed framework design with first molars in anatomic contours. C, Intraoral frontal view of proposed framework in place.

The definitive prostheses were inserted intraorally. The prostheses fit, occlusion, esthetics, and phonetics were reconfirmed, and occlusal screws were then tightened according to the manufacturer's instructions (Figs. 7, 8). The occlusal screw access holes were sealed with composite resin (Filtek Supreme Ultra; 3M ESPE) (Fig. 7B, C). Oral hygiene instructions were given, and a follow-up recall visit was scheduled at 2 weeks, 1 month, and 6 months (Fig. 8B).

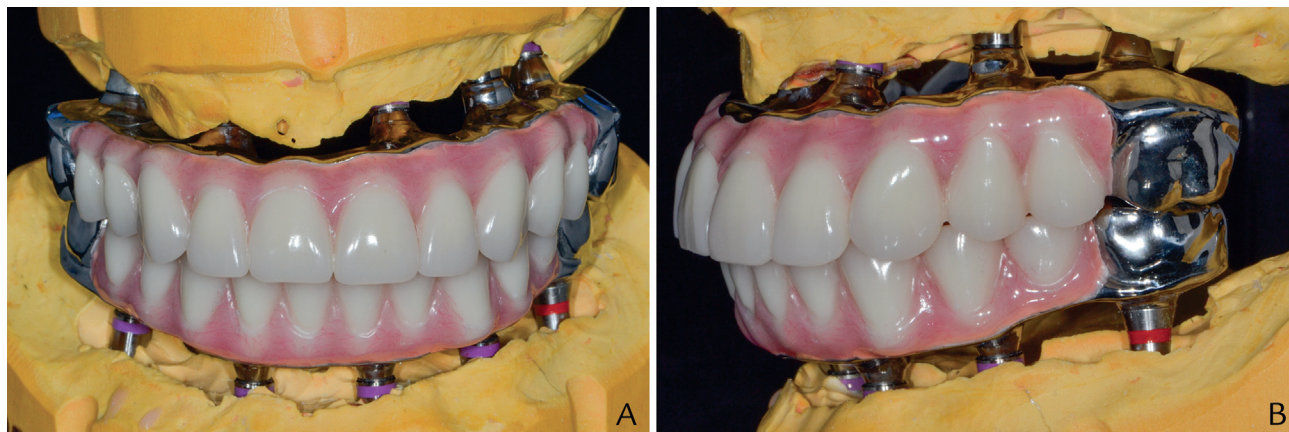


Figure 6. A, Frontal view of definitive processed ISFCDPs. B, Lateral view of definitive processed ISFCDPs. ISFCDP, implant-supported fixed complete dental prosthesis.

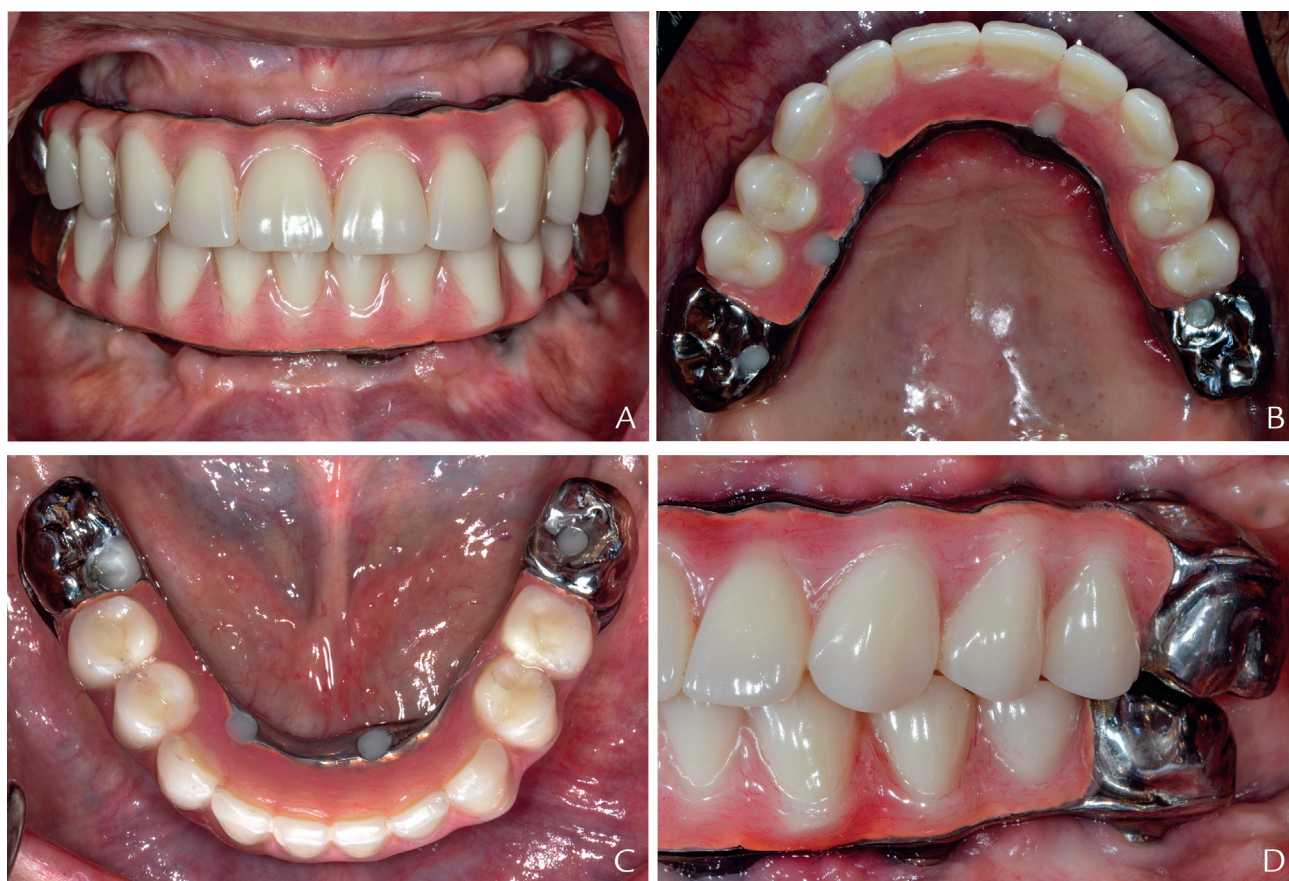

Figure 7. A, Intraoral frontal view of definitive ISFCDPs in place. B, Occlusal view of definitive maxillary ISFCDP in place. C, Occlusal view of definitive mandibular ISFCDP in place. D, Intraoral lateral view of definitive ISFCDPs in place. Showing both titanium molars and acrylic resin teeth in occlusion. ISFCDP, implant-supported fixed complete dental prosthesis.

DISCUSSION

The significance of the suggested technique is that it offered an alternative design concept for ISFCDPs to minimize tooth wear posteriorly, maintaining the OVD and strengthening the framework. The described technique involved an alteration in the design of the conventional

framework and did not incur additional laboratory fees. The presence of metal occlusal surfaces on the posterior teeth eliminated or reduced the frequently encountered prosthetic complication of occlusal tooth wear.

A limitation of the proposed design is the poor esthetics, although confined to the first molar area. An

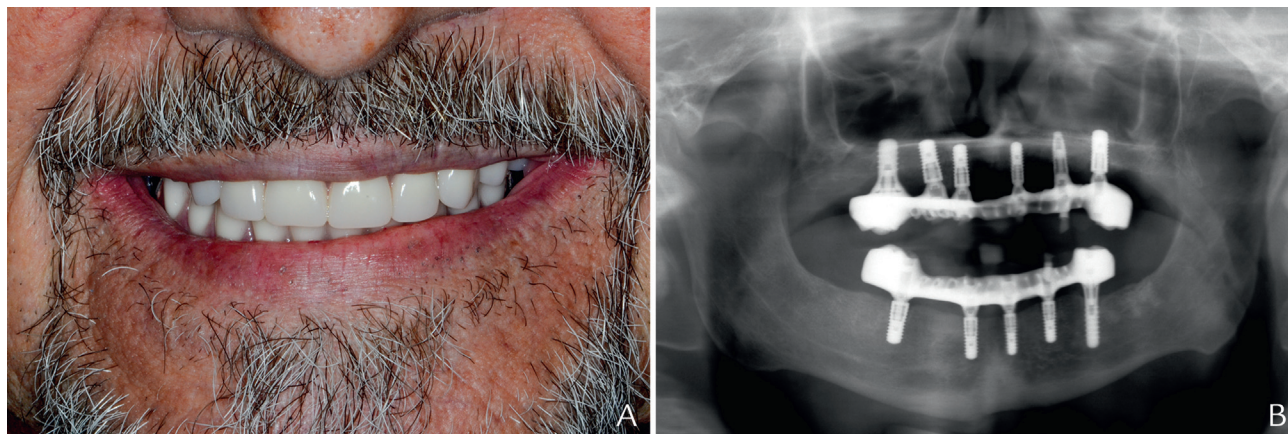


Figure 8. A, Smile view of definitive implant-supported fixed complete dental prostheses at 6-month follow-up. B, 6-month follow-up panoramic radiograph.

alternative would be to fabricate the maxillary framework according to the described protocol and then fabricate metal ceramic crowns for the molar areas for the mandibular prosthesis. This alternative approach would increase the laboratory cost for the prosthesis and the potential for debonding of the cemented crowns.

Another limitation of the proposed design is that it offers no wear protection for the anterior acrylic resin teeth from anterior guidance during functional and parafunctional movements. The fracture of anterior teeth can be caused by a variety of factors including a decrease in vertical dimension.⁹ While the presence of metal occlusal surfaces may enhance resistance to occlusal wear and help maintain occlusal vertical dimension, anterior maxillary and mandibular teeth are expected to continue to wear and will need periodic evaluation and maintenance.⁹

Accurate interocclusal records and CAD-CAM technology with a highly refined milling process of the framework also helps achieve a precise occlusion. This is achieved also by minimizing errors during the occlusal registration and transfer process before framework milling. If minor discrepancies are observed after milling and fabrication, a clinical remount procedure is needed to refine the occlusion.

Alternatively, gold, titanium alloy, or ceramic inlays/onlays can be used on the occlusal surfaces of the acrylic resin teeth.^{8,9,20} Although this technique may be used at any time after fabricating the prosthesis, it will incur additional laboratory fees. In addition, the long-term retention of these metal or ceramic additions on acrylic resin teeth is unknown, and debonding can occur.

The framework in the presented treatment was fabricated in a conventional manner, where pattern resin prototypes of the framework were created, assessed, scanned, and then milled. An alternative method of fabrication would be to scan the CDs at the initial wax trial placement stage, without the duplication in pattern

resin. With the obtained scans, a virtual cut-back procedure can be carried out to fabricate the frameworks, thereby achieving a completely digital work flow.

The proposed design lacks follow-up data. Long-term clinical data are needed to validate the hypothesis that the proposed framework design can effectively reduce the frequency of prosthetic complications involving either the acrylic resin teeth or the prosthesis framework.

SUMMARY

A design by which metal occlusion is incorporated into the framework itself for ISFCDPs may reduce costs and long-term prosthetic complications. Long-term clinical studies are needed to validate this new concept.

REFERENCES

1. Adell R, Lekholm U, Rockler B, Branemark PI. A 15 year study of osseointegrated implants in the treatment of the edentulous jaw. *Int J Oral Surg* 1981;10:387-416.
2. Astrand P, Ahlqvist J, Gunne J, Nilson H. Implant treatment of patients with edentulous jaws: a 20-year follow-up. *Clin Implant Dent Relat Res* 2008;10:207-17.
3. Davis DM, Packer ME, Watson RM. Maintenance requirements of implant-supported fixed prostheses opposed by implant supported fixed prostheses, natural teeth, or complete dentures: a 5-year retrospective study. *Int J Prosthodont* 2003;16:521-3.
4. Attard NJ, Zarb GA. Long-term treatment outcomes in edentulous patients with implant-fixed prostheses: the Toronto study. *Int J Prosthodont* 2004;17:417-24.
5. AlHelal A, Baba NZ, AlRumaih H. An alternative technique for the fabrication of a metal-reinforced interim implant-supported fixed prosthesis: a clinical report. *J Prosthodont* 2015 Aug 21. doi: 10.1111/jopr.12337.
6. Kalra S, Kharsan V, Kalra NM. Comparative evaluation of effect of metal primer and sandblasting on the shear bond strength between heat cured acrylic denture base resin and cobalt-chromium alloy: an in vitro study. *Contemp Clin Dent* 2015;3:386-91.
7. Imbery TA, Evans DB, Koeppen RG. A new method of attaching gold cast occlusal surfaces to acrylic resin denture teeth. *Quintessence Int* 1993;24:29-33.
8. Ortorp A, Jemt T. CNC milled titanium frameworks supported by implants in the edentulous jaw: a 10 year comparative clinical study. *Clin Implant Dent Relat Res* 2012;14:88-99.
9. Purcell BA, McGlumphy EA, Holloway JA, Beck FM. Prosthetic complications in mandibular metal-resin fixed complete denture prostheses: a 5 to 9 year analysis. *Int J Oral Maxillofac Implants* 2008;23:847-57.
10. Jemt T, Stenport V. Implant treatment with fixed prostheses in the edentulous maxilla. Part 2: prosthetic technique and clinical maintenance in two

- patient cohorts restored between 1986 and 1987 and 15 years later. *Int J Prosthodont* 2011;24:356-62.
11. Sadowsky SJ, Fitzpatrick B, Curtis DA. Evidence-based criteria for differential treatment planning of implant restorations for the maxillary edentulous patient. *J Prosthodont* 2015;24:433-46.
 12. Sadowsky SJ, Hansen PW. Evidence-based criteria for differential treatment planning of implant restorations for the mandibular edentulous patient. *J Prosthodont* 2014;23:104-11.
 13. Bozini T, Petridis H, Tzanas K, Garefis P. A meta-analysis of prosthodontic complication rates of implant-supported fixed dental prostheses in edentulous patients after an observation period of at least 5 years. *Int J Oral Maxillofac Implants* 2011;26:304-18.
 14. Papaspyridakos P, Chen CJ, Chuang SK, Weber HP, Galuci GO. A systematic review of biologic and technical complications with fixed implant rehabilitation for edentulous patients. *Int J Oral Maxillofac Implants* 2012;27:102-10.
 15. AlHelal A, Jekki R, Richardson PM, Kattadiyil MT. Application of digital technology in the prosthodontic management of a myasthenia gravis patient. *J Prosthet Dent* 2016;115:531-6.
 16. Jemt T, Book K, Karlsson S. Occlusal force and mandibular movements in patients with removable overdentures and fixed prostheses supported by implants in the maxilla. *Int J Oral Maxillofac Implants* 1993;8:301-8.
 17. Falk H, Laurell L, Lungren D. Occlusal force pattern in dentitions with mandibular implant-supported fixed cantilever prostheses occluded with complete dentures. *Int J Oral Maxillofac Implants* 1989;4:55-62.
 18. Stewart RB, Desjardins RP, Laney WR, Chao IYS. Fatigue strength of cantilevered metal frameworks for tissue integrated prostheses. *J Prosthet Dent* 1992;68:83-92.
 19. Von Gonten AS, Teojilo M, Woohy G. Modifications in the design and fabrication of mandibular osseointegrated fixed prostheses frameworks. *J Prosthodont* 1995;4:82-9.
 20. Drago C, Howell K. Concepts for designing and fabricating metal implant frameworks for hybrid implant prostheses. *J Prosthodont* 2012;21:413-24.
 21. Priest G, Smith J, Wilson MG. Implant survival and prosthetic complications of mandibular metal-acrylic resin implant complete fixed dental prostheses. *J Prosthet Dent* 2014;111:466-75.
 22. Al-Mazedi M, Razzoog EM, Yaman P. Fixed maxillary and mandibular zirconia implant frameworks milled with anatomically contoured molars: a clinical report. *J Prosthet Dent* 2014;112:1013-6.
 23. Venezia P, Torsello F, Cavalcanti R, D'Amato S. Retrospective analysis of 26 complete-arch implant-supported monolithic zirconia prostheses with feldspathic porcelain veneering limited to the facial surface. *J Prosthet Dent* 2015;114:506-12.
 24. Worni A, Kolgeci L, Rentsch-Kollar A, Katsoulis J, Mericske-Stern R. Zirconia-based screw-retained prostheses supported by implants: a retrospective study on technical complications and failures. *Clin Implant Dent Relat Res* 2015;17:1073-81.
 25. Moscovitch M. Consecutive case series of monolithic and minimally veneered zirconia restorations on teeth and implants: up to 68 months. *Int J Periodont Res Dent* 2015;35:314-23.
 26. Maló P, de Araújo Nobre M, Borges J, Almeida R. Retrievable metal ceramic implant-supported fixed prostheses with milled titanium frameworks and all-ceramic crowns: retrospective clinical study with up to 10 years of follow-up. *J Prosthodont* 2012;21:256-64.
 27. Paniz G, Stellini E, Meneghello R, Cerardi A, Gobbato EA, Bressan E. The precision of fit of cast and milled full-arch implant-supported restorations. *Int J Oral Maxillofac Implant* 2013;28:687-93.
 28. Faeghi Nejad M, Proussaefs P, Lozada J. Combining guided alveolar ridge reduction and guided implant placement for all-on-4 surgery. *J Prosthet Dent* 2016;115:662-7.
 29. Papaspyridakos P, Benic GI, Hogsett VL, White GS, Lal K, Gallucci GO. Accuracy of implant casts generated with splinted and non-splinted impression techniques for edentulous patients: an optical scanning study. *Clin Oral Implants Res* 2012;23:676-81.
 30. Stimmelmayer M, Güth JF, Erdelt K, Happe A, Schlee M, Beuer F. Clinical study evaluating the discrepancy of two different impression techniques of four implants in an edentulous jaw. *Clin Oral Investig* 2013;17:1929-35.
 31. Kan JY, Rungcharassaeng K, Bohsali K, Goodacre CJ, Lang BR. Clinical methods for evaluating implant framework fit. *J Prosthet Dent* 1999;81:7-13.

Corresponding author:

Dr Abdulaziz AlHelal
Loma Linda University
School of Dentistry
11092 Anderson Street, Suite 3313
Loma Linda, CA 92350
Email: alhelal.abdulaziz@gmail.com

Acknowledgments

The authors thank Mr Luis A. Calvillo, CDT, for laboratory expertise and assistance in the fabrication of the ISFCDPs.

Copyright © 2016 by the Editorial Council for *The Journal of Prosthetic Dentistry*.