

DENTAL TECHNIQUE

## An alternative conversion technique for fabricating an interim fixed implant-supported complete arch prosthesis



Shervin Hashemzadeh, DDS,<sup>a</sup> Burak Yilmaz, DDS, PhD,<sup>b</sup> Fred Zugaro, CDT,<sup>c</sup> and Edwin McGlumphy, DDS, MS<sup>d</sup>

The immediate loading of implants is a clinically successful procedure that offers patients the immediate restoration of esthetics and function.<sup>1,2</sup> A conversion prosthesis is a method of immediate loading in which clinicians fabricate an interim fixed implant-supported complete arch restoration (FISCAR) through an existing or new complete denture.<sup>3</sup> In this method, interim copings tightened on implants are picked up with acrylic resin and the existing complete denture. Access holes are first made on the denture to avoid any interference between the denture and the copings. Subsequently, the flanges and the palate of the denture are trimmed to convert the denture to a FISCAR that can be cleaned by the patients.

This interim denture splints the implants together, which minimizes the micromovement of the implants and leads to favorable stress distribution in the peri-implant tissues.<sup>3</sup> This prosthesis also protects the recently traumatized mucosa from external physical irritants.<sup>3</sup> However, the presence of a rubber dam during the process may prevent the accurate replication of the soft tissues and prevent an accurate recording of the distance between the intaglio surface of the denture and the mucosa. Complete interim restorations fabricated with this technique have been reported to present with some complications, including fracture of acrylic resin framework, which tends to break at the coping site.<sup>2,4-6</sup>

### ABSTRACT

The conversion technique enables the immediate loading of implants using an existing or a new complete denture. Acrylic resin is generally used directly intraorally when the conventional conversion technique is used. The technique described suggests picking-up the interim copings and capturing the soft tissue contour with the conversion prosthesis with a polyether impression material when 4 implants are placed with an angled implant protocol. A polyether impression was made to complete an autopolymerized reline jig reline. Acrylic resin was applied on the cast generated from this impression outside the oral cavity. This technique may minimize chair time and maximize the ability of the technician/clinician to adapt the prosthesis to the soft tissue contour. (*J Prosthet Dent* 2016;116:647-651)

The direct use of autopolymerizing acrylic resin intraorally may be another disadvantage of this technique, because the resin may flow around the rubber dam and negatively affect the healing of soft tissues. In addition, the exothermic polymerization of the acrylic resin may harm newly sutured soft tissues.

The technique described in this report is an alternative method of fabricating an interim conversion prosthesis. With this technique, the amount of acrylic resin needed to reline the existing denture and pick up the interim copings is controlled, and the acrylic resin application procedure is performed extraorally. Therefore, any shrinkage due to excessive acrylic resin can be minimized. This may also minimize a misfit of the prosthesis due to acrylic resin shrinkage. Moreover, making an impression of the tissue without rubber dam can allow clinicians to capture the tissue surface accurately and properly shape the intaglio surface of the prosthesis with a favorable distance between the mucosa and the intaglio surface of the denture. A proper distance between the denture and mucosa may help to minimize air escape

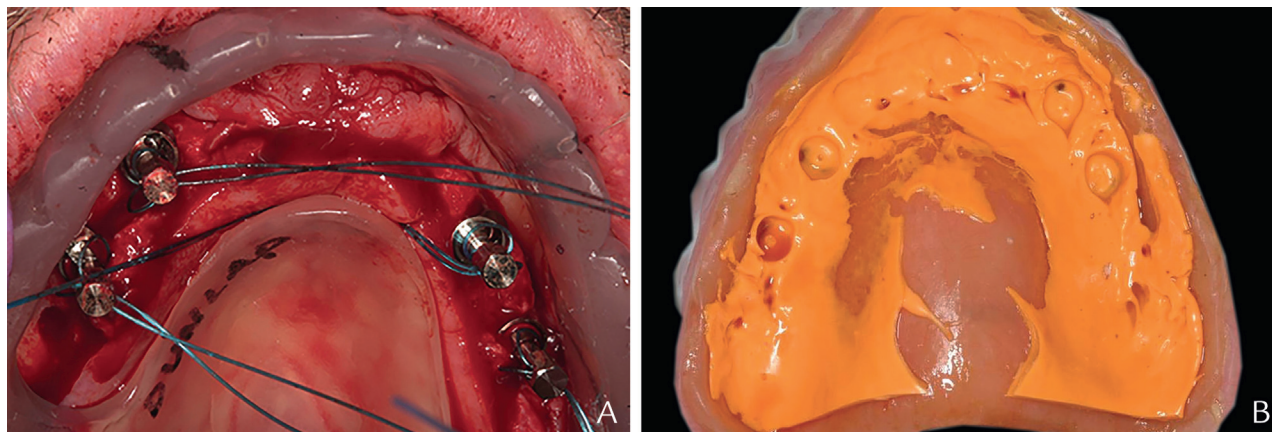
Presented at the 51st Annual Carl O. Boucher Conference, April 2016, Columbus, Ohio.

<sup>a</sup>Visiting scholar, Division of Restorative Sciences and Prosthodontics, The Ohio State University College of Dentistry, Columbus, Ohio.

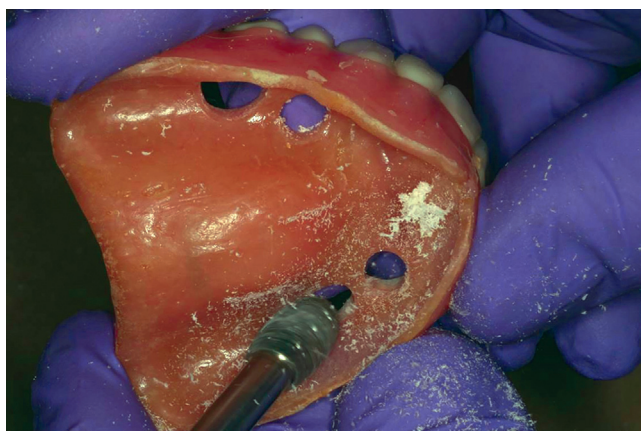
<sup>b</sup>Associate Professor, Division of Restorative Sciences and Prosthodontics, The Ohio State University College of Dentistry, Columbus, Ohio.

<sup>c</sup>Dental Technician, Private Practice, Columbus, Ohio.

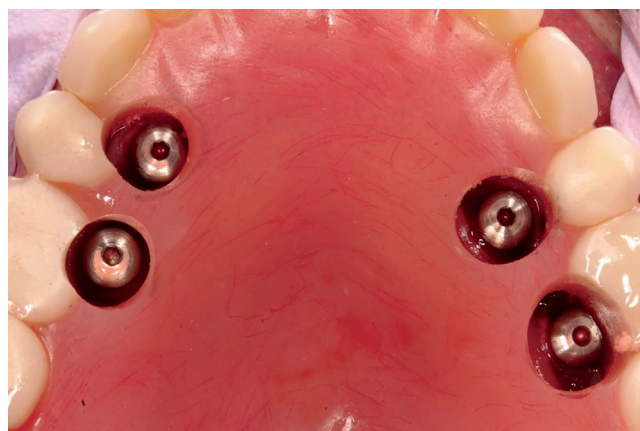
<sup>d</sup>Professor, Division of Restorative Sciences and Prosthodontics, The Ohio State University College of Dentistry, Columbus, Ohio.



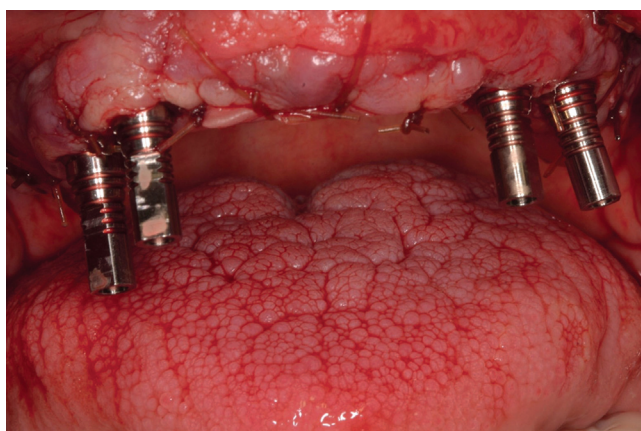
**Figure 1.** A, Placement of implants with surgical guide. B, Captured locations of healing abutments in intaglio surface of complete denture.



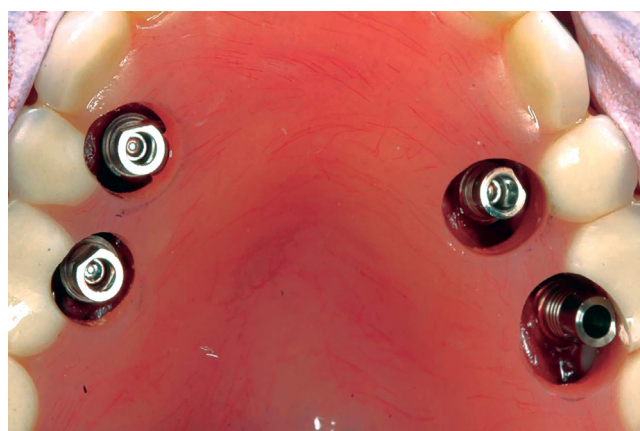
**Figure 2.** Preparing access holes in denture with acrylic resin bur.



**Figure 3.** Complete denture in place after access hole preparation.



**Figure 4.** Tightened interim copings on implants.



**Figure 5.** Passive seating of denture on maxillary arch.

and facilitate hygiene procedures.<sup>7</sup> In addition, the acrylic material does not polymerize in the oral cavity, which may help minimize trauma to the healing soft tissues.

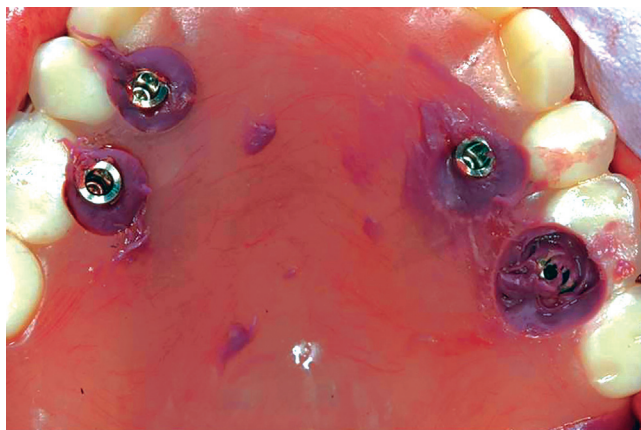
This technique may require a chairside technician during the appointment; however, it may be less time consuming intraorally. This chairside advantage comes primarily from the time gained by making an impression

rather than brush beading acrylic resin intraorally in the conventional conversion technique.

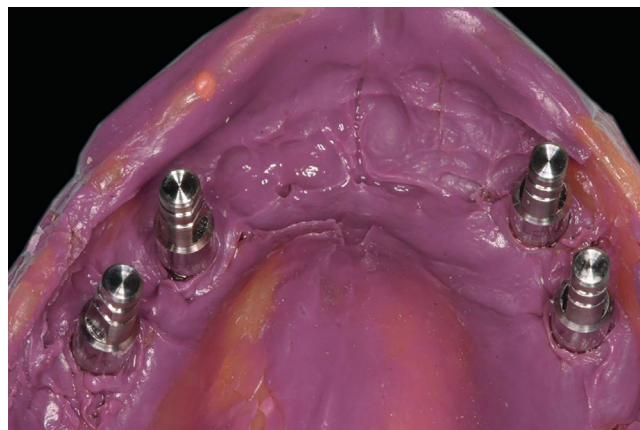
## TECHNIQUE

1. After the surgical placement of the implants and abutment connection is completed, make an

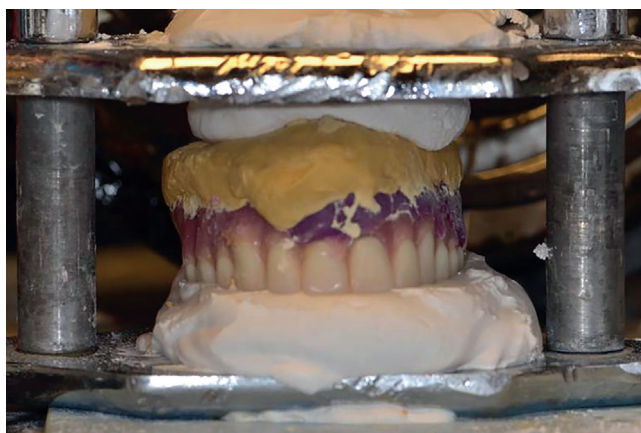



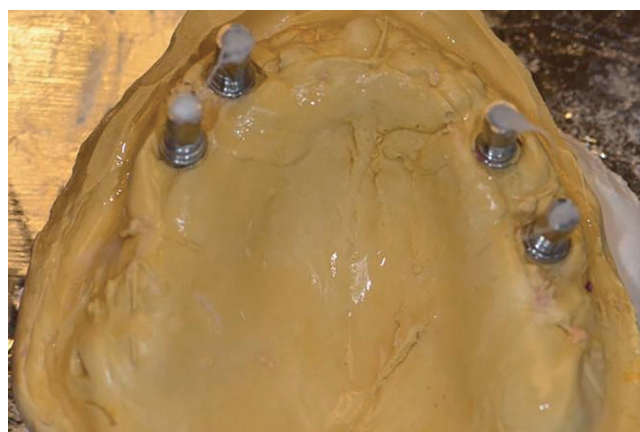
**Figure 6.** Impression using complete denture and polyether.



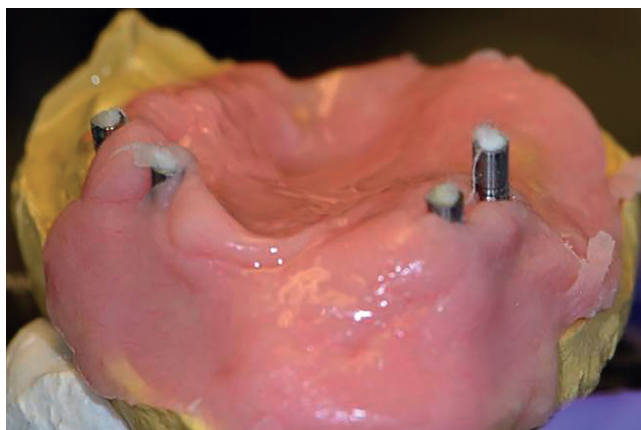
**Figure 7.** Impression of maxillary arch with analogs placed on picked up interim copings.



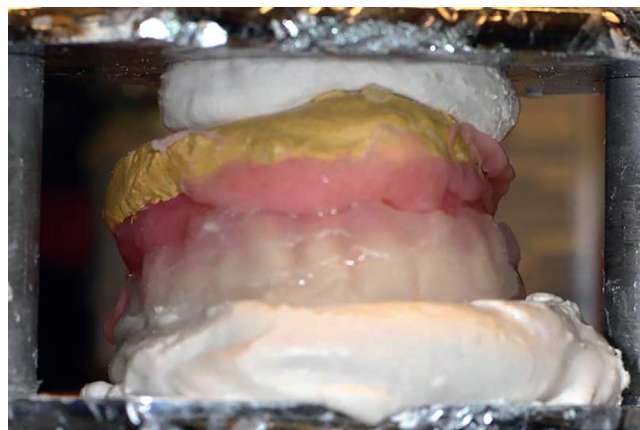**Figure 8.** Dental stone poured in impression and denture mounted on jig for reline.



**Figure 9.** Dental stone cast lubricated with petroleum jelly.



**Figure 10.** Dental stone cast covered with doughy acrylic resin.

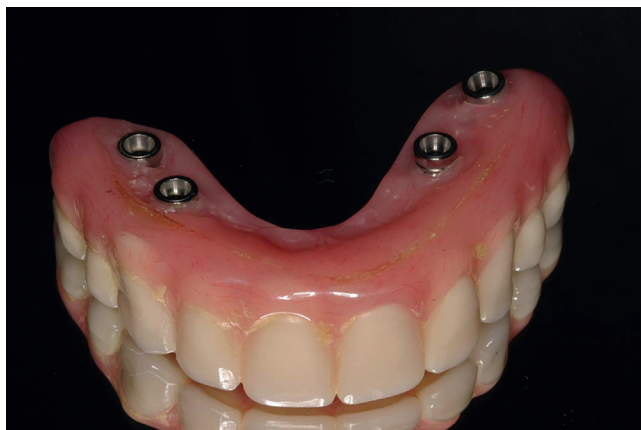

**Figure 11.** Complete denture seated on cast covered with acrylic resin.

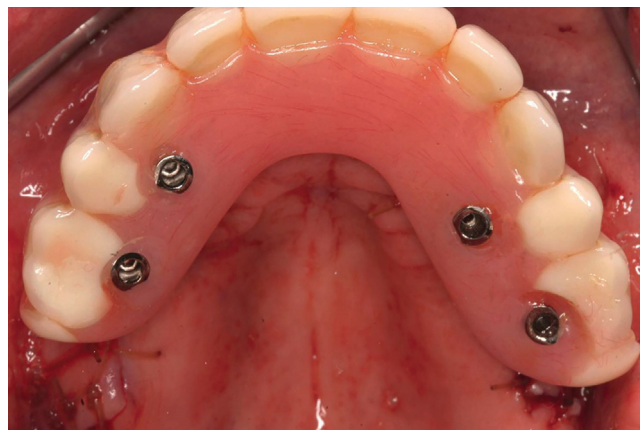impression (Light Body, Reprosil; Dentsply Intl) of the healing abutments by using the complete denture to locate the healing abutment positions in the intaglio surface of the complete denture (Fig. 1).

2. Remove the complete denture and use an acrylic resin bur (Euro Carbide Bur; Dedeco) to prepare

access holes on the existing complete denture at locations that correspond to the implants captured by the impression material (Figs. 2, 3). If a precise surgical guide is used, it may be possible to drill the holes in the denture before surgery and avoid this step.



**Figure 12.** Interim fixed implant-supported complete arch prosthesis.



**Figure 13.** Interim fixed implant-supported complete arch prosthesis in place immediately after implant surgery.

3. Remove the healing abutments (Tapered Screw-Vent; Zimmer) and tighten interim copings on multiunit abutments (Tapered Screw-Vent; Zimmer) (Fig. 4). Insert the complete denture to ensure passive seating with the interim copings projecting through the access holes. Enlarge the holes if necessary for passivity (Fig. 5). If the height of the copings interferes with the patient closing completely into occlusion with the denture in place, the copings should be shortened accordingly.
4. Inject a medium-bodied polyether impression material (Impregum; 3M ESPE) inside the denture and insert the denture to make the impression of the soft tissues and pick up the interim copings. Use the palate of the denture as a stop to maintain the patient's vertical dimension of occlusion. Make sure to expose the screw access holes of the interim copings as the impression material sets (Fig. 6). The patient should close lightly into occlusion while the impression material is setting.
5. Once the impression material polymerizes, unscrew all interim coping screws and pick up the copings in the complete denture reline impression. Tighten the laboratory analogs on the interim copings (Fig. 7).
6. Pour the impression in Type III dental stone (Microstone; Whip Mix Corp) and mount the denture on a reline jig (Fig. 8). Once the stone sets, remove it from the impression and remove the impression material from the complete denture.
7. Lubricate the soft tissue surface of the dental stone cast with petroleum jelly. Make sure not to apply the jelly on the interim copings. Place cotton into the screw access holes of the interim copings to prevent the acrylic resin from flowing (Fig. 9).

8. Mix acrylic resin powder and liquid (Repair Material; Dentsply Intl) in a 3-to-1 proportion and, once the mixture reaches a doughy stage, apply the dough to the isolated surface of the cast (Fig. 10). Seat the denture on the cast and remove excess acrylic resin material around the flanges and interim coping access holes with a sharp laboratory knife (Fig. 11).
9. Once acrylic resin polymerizes, unscrew the interim coping and remove the complete denture from the cast. Make necessary adjustments by shortening the flanges and polishing all tissue surfaces to create a proper soft tissue surface and contour (Figs. 12, 13).

## SUMMARY

The immediate loading of implants with the conversion technique and angled implant protocol is a method of restoring function and esthetics immediately after implant placement. Converting a complete denture enables clinicians to achieve immediate loading with a fixed, detachable prosthesis. This report describes an alternative conversion technique that allows the controlled application of acrylic resin extraorally. With this technique, direct contact of acrylic resin with the soft tissues can be avoided and optimum soft tissue surfaces achieved.

## REFERENCES

1. Malo P, de Araújo Nobre M, Lopes A, Moss SM, Molina GJ. A longitudinal study of the survival of All-on-4 implants in the mandible with up to 10 years of follow-up. *J Am Dent Assoc* 2011;142:310-20.
2. Maló P, de Araújo Nobre M, Lopes A, Francischone C, Rigolizzo M. "All-on-4" immediate-function concept for completely edentulous maxillae: a clinical report on the medium (3 years) and long-term (5 years) outcomes. *Clin Implant Dent Relat Res* 2012;14(suppl 1):e139-50.

3. Balshi TJ, Wolfinger GJ. Conversion prosthesis: a transitional fixed implant-supported prosthesis for an edentulous arch—a technical note. *Int J Oral Maxillofac Implants* 1996;11:106-11.
4. Wolfinger GJ, Balshi TJ, Rangert B. Immediate functional loading of Bråne-mark system implants in edentulous mandibles: clinical report of the results of developmental and simplified protocols. *Int J Oral Maxillofac Implants* 2003;18:250-7.
5. Nikellis I, Levi A, Nicolopoulos C. Immediate loading of 190 endosseous dental implants: a prospective observational study of 40 patient treatments with up to 2-year data. *Int J Oral Maxillofac Implants* 2004;19:116-23.
6. Cooper LF, Rahman A, Moriarty J, Chaffee N, Sacco D. Immediate mandibular rehabilitation with endosseous implants: simultaneous extraction, implant placement, and loading. *Int J Oral Maxillofac Implants* 2002;17:517-25.
7. Purcell BA, McGlumphy EA, Holloway JA, Beck FM. Prosthetic complications in mandibular metal-resin implant-fixed complete dental prostheses: a 5- to 9-year analysis. *Int J Oral Maxillofac Implants* 2008;23:847-57.

**Corresponding author:**

Dr Edwin McGlumphy  
Ohio State University College of Dentistry  
305 W12th Avenue  
Columbus, OH 43210  
Email: mcglumphy.1@osu.edu

Copyright © 2016 by the Editorial Council for *The Journal of Prosthetic Dentistry*.

## Noteworthy Abstracts of the Current Literature

### Effect of grain size on the monoclinic transformation, hardness, roughness, and modulus of aged partially stabilized zirconia

Lucas TJ, Lawson NC, Janowski GM, Burgess JO  
*Dent Mater* 2015;31:1487-92

**Objective.** Low-temperature-degradation (LTD) has been reported to cause property changes in yttria-tetragonal zirconia polycrystals (Y-TZP). The current study measured monoclinic phase transformation of Y-TZP with different grain sizes and corresponding property changes due to artificial aging.

**Null hypothesis.** The grain size of aged Y-TZP will not influence its transformation, roughness, hardness or modulus of elasticity.

**Methods.** Four groups of Y-TZP were examined with differing grain sizes ( $n=5$ ). The line intercept technique was used to determine grain sizes on SEM images (100,000 $\times$ ). Artificial aging was accomplished by autoclaving at 2bar pressure for 5h. X-ray diffraction (30mA, 40kV) was used to measure tetragonal to monoclinic transformation ( $t \rightarrow m$ ). Surface roughness analysis was performed using a non-contact surface-profilometer. Nano-hardness and modulus of elasticity were measured using nano-indentation.

**Results.** SEM analyses showed different grain sizes for each sample group (0.350 $\mu\text{m}$ , 0.372 $\mu\text{m}$ , 0.428 $\mu\text{m}$ , and 0.574 $\mu\text{m}$ ). The fraction of  $t \rightarrow m$  transformation increased as grain size increased; furthermore, aging of zirconia caused increased roughness. Modulus and hardness after aging displayed no significant correlation or interaction with grain size.

**Significance.** Smaller grains caused less transformation, and aging caused increased roughness, but grain size did not influence the amount of increased surface roughness. Future studies are needed to determine the effects of grain size on the wear and fracture properties of dental zirconia.

Reprinted with permission of the Academy of Dental Materials.