

CLINICAL REPORT

Hereditary gingival fibromatosis with extreme ridge thickness and insufficient interarch distance: A clinical report of surgical and prosthetic management



Pierre-Luc Michaud, DMD, MSc, FRCD(C)^a and Aditya Patel, HBSc, DDS, MPerio, FRCD(C)^b

Hereditary gingival fibromatosis (HGF) is a genetic disorder that can result in localized or generalized gingival enlargement.¹ The affected soft tissue is typically firm, very fibrous, and of normal pink color with a finely stippled surface. It usually has little tendency to bleed.^{1,2} The condition usually begins before 20 years of age and is usually associated with tooth eruption.^{1,2} Teeth and, by association, plaque are

ABSTRACT

Hereditary gingival fibromatosis is a rare genetic disorder resulting in gingival overgrowth that can be found in both dental arches. As a result of the gingival overgrowth and associated dental displacement, affected patients occasionally present with increased occlusal vertical dimension and/or inadequate lip closure. Depending on the disorder's severity, these patients can be challenging to treat. This clinical report describes a comprehensive surgical and prosthetic approach to the rehabilitation of a middle-aged patient with severe manifestations of hereditary gingival fibromatosis and severe generalized chronic periodontitis. (J Prosthet Dent 2016;116:15-20)

necessary for clinical symptoms to occur.^{2,3} However, no direct correlation seems to exist between the quality of oral hygiene or amount of calculus present and the

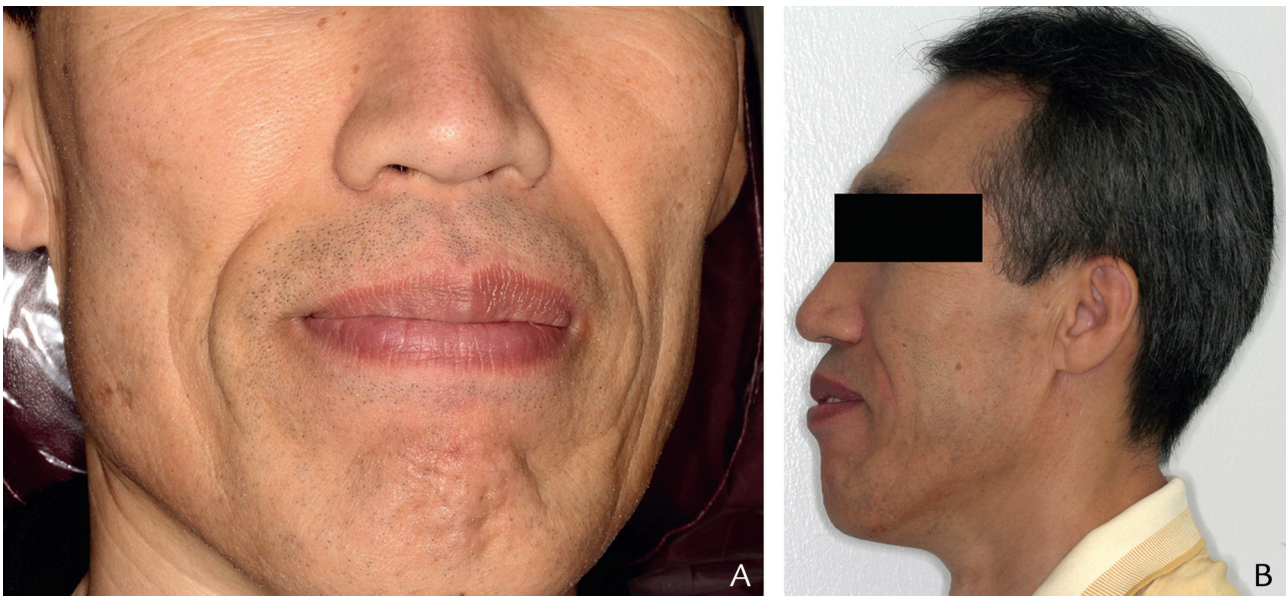

Figure 1. Extraoral views of patient.

^aAssistant Professor, Department of Dental Clinical Sciences, Faculty of Dentistry, Dalhousie University, Halifax, Nova Scotia, Canada.

^bClinical Instructor, Department of Dental Clinical Sciences, Faculty of Dentistry, Dalhousie University, Halifax, Nova Scotia, Canada.

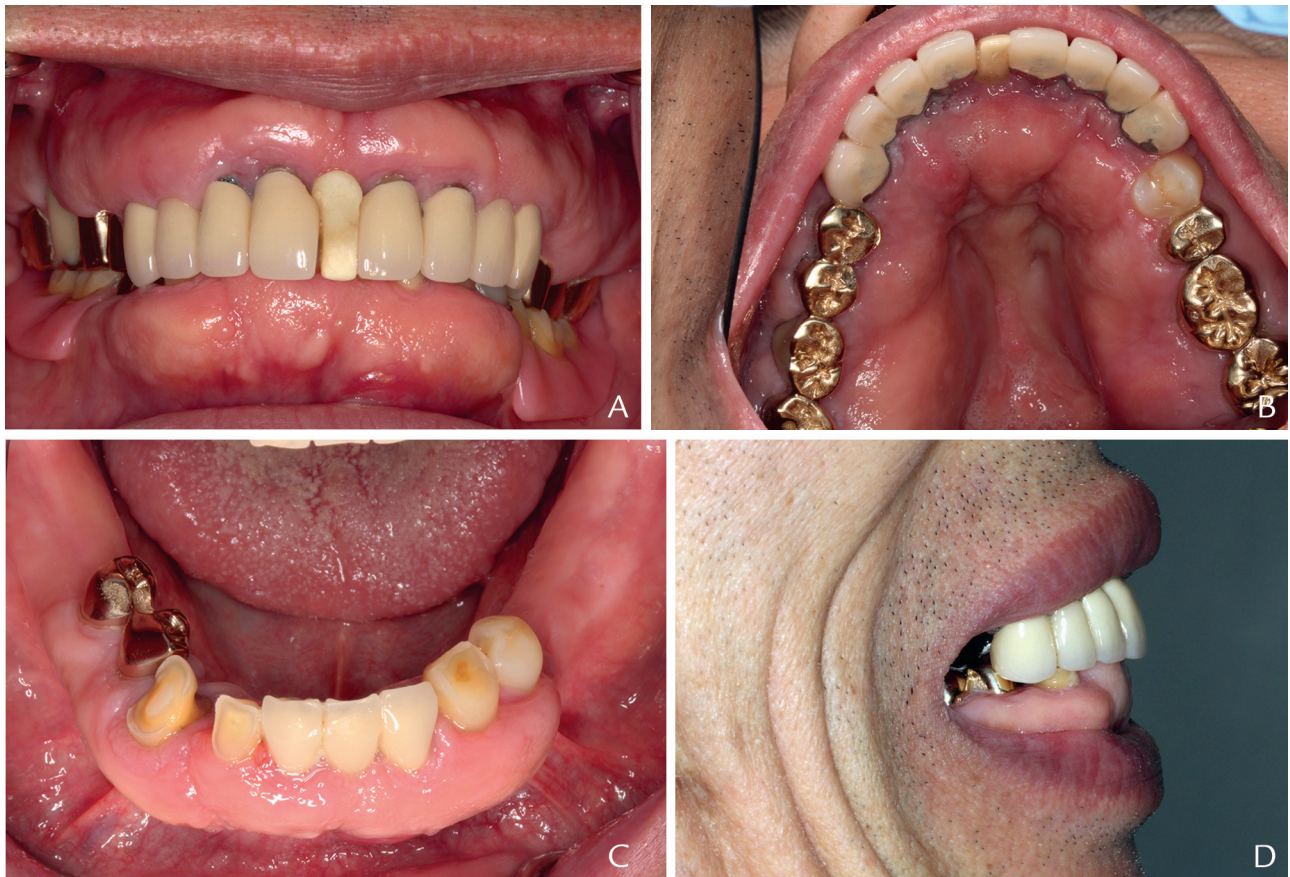

Figure 2. A, Intraoral examination, frontal view. B, Maxillary view. C, Mandibular view. D, Lateral smile.

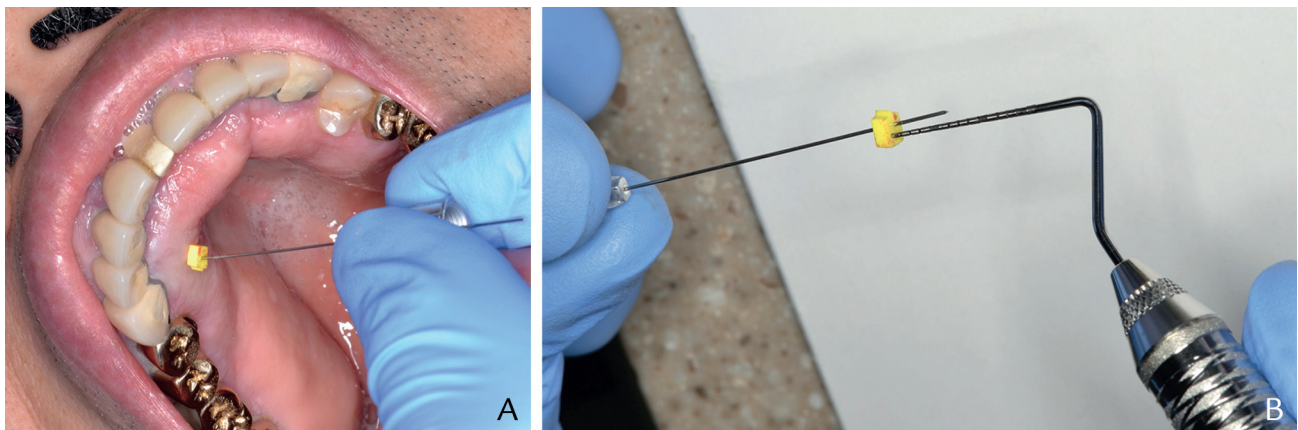


Figure 3. Evaluation of gingival thickness. Average tissue thickness observed: 3 mm on buccal side and 6 mm on palatal side.

extent of gingival fibromatosis.⁴ Clinical features of HGF include gingival overgrowth in both dental arches; however, the maxilla is affected more often and more severely than the mandible.² As a result of gingival overgrowth and associated malposition of the teeth and/or overeruption, affected patients will occasionally present with inadequate lip closure.^{2,5} According to a systematic review by Colleta and Graner,⁵ the histologic features of HGF are nonspecific. Also, even though

genetic tests are available, different genes seem to be involved in different forms of HGF, and some genetic anomalies may have yet to be identified.⁵ As such, the definitive diagnosis is heavily based on family history and clinical findings.⁵ They also suggested that the main reason for intervention in these patients is esthetic or their inability to maintain proper oral hygiene.⁵ When minimal gingival hyperplasia occurs, nonsurgical debridement every 3 months is usually recommended.⁶

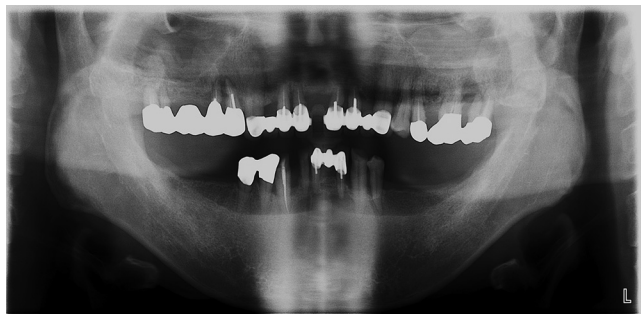

Figure 4. Preoperative panoramic view.

However, when overgrowth is excessive, surgical treatment of HGF is the preferred approach.³ Many techniques have been used to correct the soft tissues, including gingivectomy, gingivoplasty, and apically positioned flap.^{3,5} For severe manifestations of HGF, surgical intervention may also involve dental extractions and ostectomy.⁷⁻⁹ Nevertheless, the recurrence of gingival overgrowth in patients with HGF ranges between 3 and 10 years and is more frequently found in children and teenagers than in adults.^{10,11}

The following clinical report describes a comprehensive surgical and prosthetic approach to rehabilitation

in a patient with a severe case of HGF associated with underlying severe generalized chronic periodontitis.

CLINICAL REPORT

A 57-year-old man was referred to the Graduate Periodontal Clinic at Dalhousie Dentistry for management of his periodontal status. The patient's chief complaint was that his gingiva was oversized and his comfort, esthetics, and phonetics were affected.

His medical history was unremarkable. His family history revealed no significant medical conditions, except that his father also had gingival enlargement. The patient presented with a vertical overlap of approximately 100%, prominent lips, and an open lip posture (Figs. 1, 2). When his lips and chin were relaxed, his lips were incompetent by more than 10 mm. He had to contract his muscles significantly in order to close his lips (Fig. 1A). A lateral view shows a convex profile with a long lower face height and an acute nasolabial angle (Fig. 1B). Temporomandibular joint findings were within normal limits. In addition to extremely thick fibrous gingival enlargement (Fig. 3), this patient also had severe underlying bony exostoses. Periodontal examination revealed generalized deep probing depths with bleeding

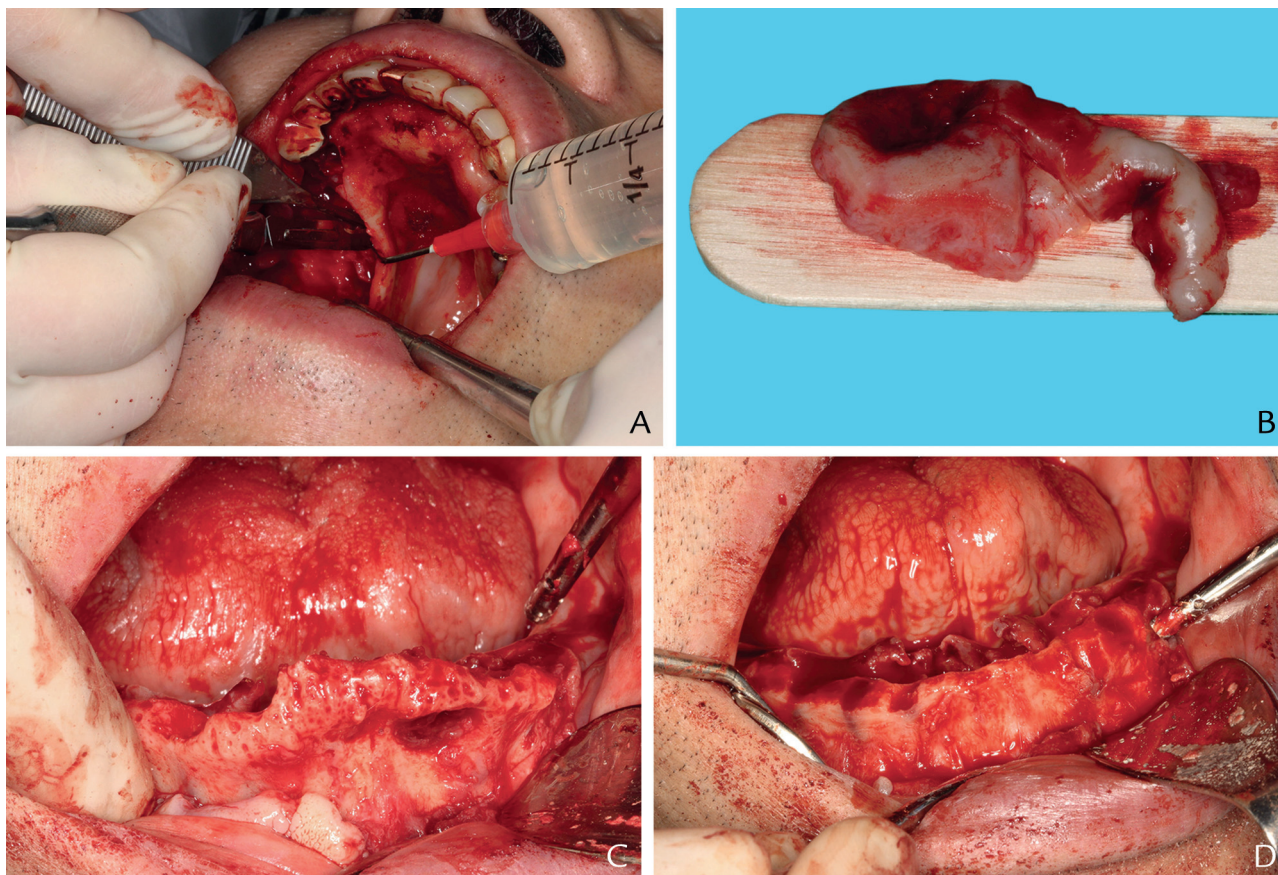


Figure 5. A, B, Surgical treatments. Thick soft tissue was thinned. C, D, Osteoplasty removed bone both horizontally and vertically.

on probing, suppuration, and severe clinical attachment loss. Radiographic examination confirmed generalized severe horizontal bone loss with localized vertical defects, along with failing endodontic treatments (Fig. 4). His maxillary alveolar ridges were extremely thick, and he had a particularly high vaulted palate (Fig. 2B). Additionally, because of soft and hard tissue overgrowth, deep rigid undercuts were also present on the labial side of the anterior segment of both ridges and on the buccal and palatal sides of the posterior maxillary ridges. As expected with HGF, no hyperplasia was evident in the edentulous sites of the mandible (Fig. 2C).

Based on family history and clinical and radiographic findings, the patient's condition was diagnosed as HGF of genetic origin, chronic periodontitis, periodontal abscesses, endodontic lesions, attrition, caries, and defective restorations.¹²⁻¹⁴ No genetic testing was conducted because of financial, availability, and relevance reasons. In fact, the result would not have justified changes in the treatment plan for this patient.

After medical consultation to eliminate systemic involvement, the patient underwent initial periodontal therapy.^{15,16} He was keen to retain as many teeth as possible. However, at the re-evaluation appointment, only his maxillary canines, maxillary first left premolar, and mandibular right premolars had a fair prognosis in the short to medium term. Retention and stability of a maxillary removable partial dental prosthesis, retained by only 2 canines and 1 premolar in a patient with a very deep palate and large ridges, were anticipated to be poor. Different techniques have been previously described to evaluate occlusal vertical dimension (OVD).¹⁷⁻¹⁹ Using a variety of these techniques, such as esthetic measurements (lip incompetency and lower face height) and evaluation of phonetics and physiological rest position, his OVD was judged to be excessive. His OVD needed to be decreased to improve his comfort, phonetics, and esthetics. Because the patient was dentulous, testing reduced OVD with conventional approaches was not possible. Instead, the anticipated decrease in OVD was first determined using the distance between his lips during muscular relaxation while his teeth were in maximum intercuspation. However, because the interarch distance was already less than ideal at his current OVD (Fig. 2A), keeping the ridges unaltered and decreasing the OVD would result in insufficient interarch space.²⁰

Therefore, surgical impaction of his maxilla and/or extensive bone recontouring would be required to maintain the interarch distance needed to fabricate prostheses of adequate contour and thickness. Considering these strategic factors, extracting all his teeth could enhance the chances of a stable outcome. Different conventional and implant-retained treatment alternatives were presented to the patient. He decided against LeFort

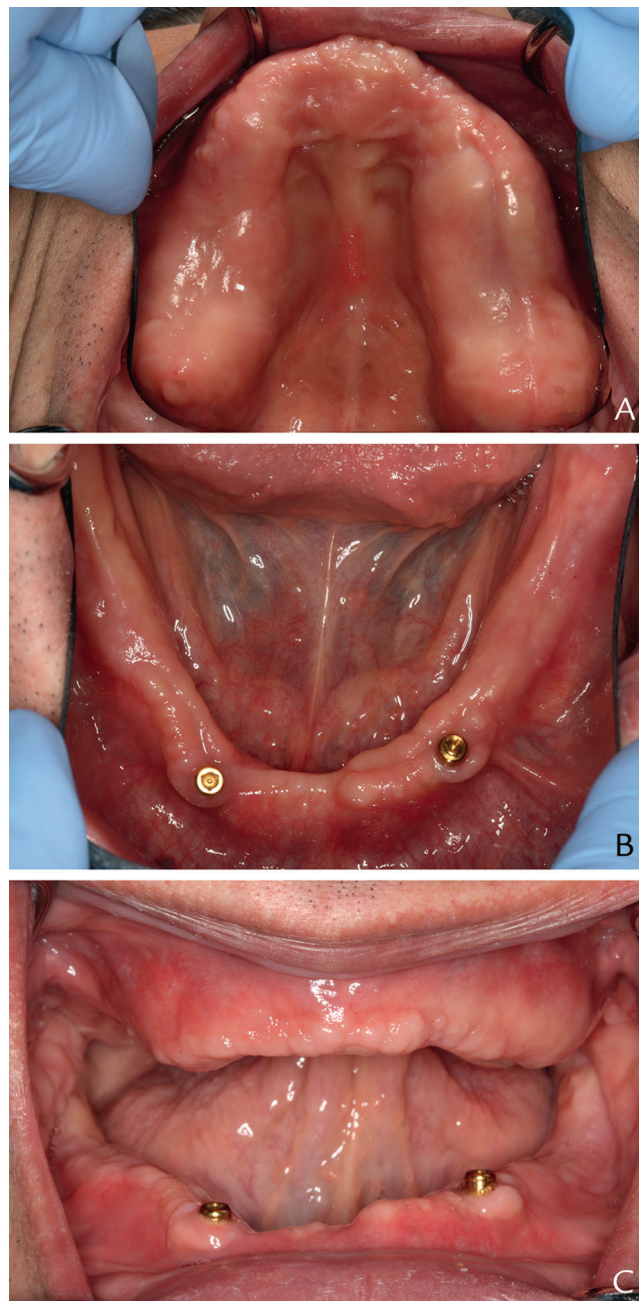


Figure 6. Intraoral views (1 year after treatment). A, Maxilla. B, Mandible. C, Frontal view of both ridges. Note: photograph was not made at restored vertical dimension.

1 surgery because he feared more advanced surgical treatments and implant dentistry in general. He chose to have his remaining teeth extracted, to have his alveolar bone recontoured, and to receive interim removable complete dentures first and then consider the placement of dental implants if needed.

The maxillary posterior sextants were treated by using extractions, inverse bevel incisions, palatal tissue thinning, osteotomy, and alveoplasty (Fig. 5A, B). After a healing phase of 8 weeks, the anterior segments of the

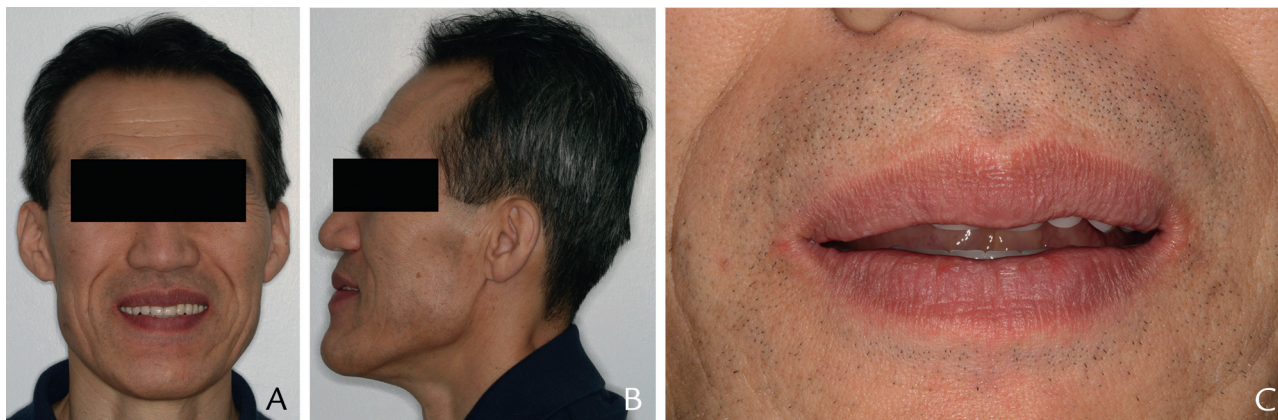


Figure 7. Patient with definitive prostheses. A, Face view. B, Profile view. C, Teeth shown with lips at rest.

maxilla and mandible underwent a similar process (Fig. 5C, D). Immediate dentures were not fabricated for the patient because major bone recontouring was performed (both horizontally and vertically), and, as a result, the outcome would have been unpredictable. Instead, primary impressions for interim dentures were made 1 week after the extractions, followed by definitive impressions in custom trays, wax occlusion rim adjustments, and a trial denture appointment. These interim dentures were delivered after 3 weeks of healing. Two months after delivery of the interim dentures, at the patient's request, 2 parasymphysal dental implants (OsseoSpeed Tx implants, 4.0×13 mm; Astra Tech) were placed (Fig. 6). After implant healing time, a new conventional removable maxillary complete denture and an implant-retained removable mandibular complete denture secured with 2 abutment-based attachments (Locator; Zest Anchor) were fabricated (Fig. 7).

One year after delivery of the restoration, the patient had adapted well to his prostheses. An overall improvement in esthetics was apparent. Clinical examination revealed stable edentulous ridges. However, both dental implants showed marginal edema and inflammation (Fig. 6). This could be consistent with signs of periimplant mucositis or recurrence of fibromatous tissue, which would be supported by the theory of plaque as a required stimulus for gingival overgrowth in HGF. The patient, therefore, underwent continuous maintenance and oral hygiene reinforcement to control plaque accumulation around the implants.

DISCUSSION

This clinical report describes a comprehensive treatment for rehabilitation in a patient with a diagnosis of HGF, severe chronic periodontitis, and insufficient interarch distance. Using different approaches, his OVD was judged to need reduction.¹⁷ Before his teeth were extracted, the amount of decrease in OVD was

determined using the distance by which his lips were incompetent. This was used to guide the amount of soft and hard tissue that needed to be removed to maintain interarch space. This technique had inherent inaccuracies because, as part of the treatment, the lip support would also be reduced, influencing its vertical position. However, after his teeth were extracted, wax occlusion rims were used to obtain a more accurate evaluation of OVD. An alternative technique would have been to use cephalometric measurements.^{18,19}

Implant-retained prostheses were initially suggested to the patient. Depending on the attachment system selected, 12 to 20 mm (removable) or 8 to 15 mm (fixed) of interarch distance would have been necessary.²⁰ However, because of his reluctance to undergo further surgeries and his satisfaction with his interim maxillary denture, he decided to proceed with a new conventional maxillary prosthesis. Conversely, because he experienced inadequate mandibular denture retention and gingival discomfort when incising, he chose to receive an implant-retained removable mandibular prosthesis. Ideally, because of space limitations, additional osteotomy and alveoplasty would have been needed after the first intervention; however the patient refused. As a result, even with the thinnest possible maxillary denture, the occlusal plane could not be ideally positioned, and the tooth display was increased when the upper lip was relaxed. The therapeutic OVD that ensued was also higher than sought. Consequently, the patient continued to have difficulties with phonetics. An alternative to the surgical approach used would have been to perform a LeFort 1 osteotomy with impaction of the maxilla. This option would have helped obtain an adequate interarch distance while maintaining bone height for implant therapy.²⁰

Recurrence of gingival fibromatosis after surgical intervention is considered unpredictable.^{6,10,11} In addition, no reports are available on the effects of implant placement on the soft tissues in patients with HGF. Regular follow-up should be part of management.⁶

SUMMARY

This clinical report describes oral rehabilitation in a middle-aged man affected with a severe form of HGF accompanied by severe chronic periodontitis. The treatment offered consisted of dental extractions, ostectomy, alveoplasty, implant placement, and conventional and implant-retained complete dentures. Even though ideal treatment could not be achieved because of both anatomic and patient limitations, a stable result and high patient satisfaction were achieved. Whether implants influence gingival enlargement in HGF is still unknown. Further long-term studies are required to address this question.

REFERENCES

- DeAngelo S, Murphy J, Claman L, Kalmar J, Leblebicioglu B. Hereditary gingival fibromatosis—a review. *Compend Contin Educ Dent* 2007;28:138–43. quiz 44, 52.
- Neville B, Damm D, Allen C, Chi A. *Oral and maxillofacial pathology*. 4th ed. St. Louis: WB Saunders/Elsevier; 2016. p. 151–3.
- Ramer M, Marrone J, Stahl B, Burakoff R. Hereditary gingival fibromatosis: identification, treatment, control. *J Am Dent Assoc* 1996;127:493–5.
- Emerson TG. Hereditary gingival hyperplasia. A family pedigree of four generations. *Oral Surg Oral Med Oral Pathol* 1965;19:1–9.
- Coletta RD, Graner E. Hereditary gingival fibromatosis: a systematic review. *J Periodontol* 2006;77:753–64.
- Bushehri S. Hereditary gingival fibromatosis—review of the literature. *J West Soc Periodontol Periodontol Abstr* 2014;62:3–6.
- Casavecchia P, Uzel MI, Kantarci A, Hasturk H, Dibart S, Hart TC, et al. Hereditary gingival fibromatosis associated with generalized aggressive periodontitis: a case report. *J Periodontol* 2004;75:770–8.
- Cuestas-Carnero R, Bornancini CA. Hereditary generalized gingival fibromatosis associated with hypertrichosis: report of five cases in one family. *J Oral Maxillofac Surg* 1988;46:415–20.
- Odessey EA, Cohn AB, Casper F, Schechter LS. Hereditary gingival fibromatosis: aggressive 2-stage surgical resection in lieu of traditional therapy. *Ann Plast Surg* 2006;57:557–60.
- Takagi M, Yamamoto H, Mega H, Hsieh KJ, Shioda S, Enomoto S. Heterogeneity in the gingival fibromatoses. *Cancer* 1991;68:2202–12.
- Anderson J, Cunliffe WJ, Roberts DF, Close H. Hereditary gingival fibromatosis. *Br Med J* 1969;3:218–9.
- Armitage GC. Development of a classification system for periodontal diseases and conditions. *Ann Periodontol* 1999;4:1–6.
- Bakaeen G, Scully C. Hereditary gingival fibromatosis in a family with the Zimmermann-Laband syndrome. *J Oral Pathol Med* 1991;20:457–9.
- He L, Ping FY. Gingival fibromatosis with multiple unusual findings: report of a rare case. *Int J Oral Sci* 2012;4:221–5.
- Veksler AE, Kayrouz GA, Newman MG. Reduction of salivary bacteria by pre-procedural rinses with chlorhexidine 0.12%. *J Periodontol* 1991;62:649–51.
- Olsson H, Asklov B, Johansson E, Slotte C. Rinsing with alcohol-free or alcohol-based chlorhexidine solutions after periodontal surgery. A double-blind, randomized, cross-over, pilot study. *Swed Dent J* 2012;36:91–9.
- Turrell AJ. Clinical assessment of vertical dimension. *J Prosthet Dent* 1972;28:238–46.
- DiPietro GJ, Moergeli JR. Significance of the Frankfort-mandibular plane angle to prosthodontics. *J Prosthet Dent* 1976;36:624–35.
- Yamashita S, Shimizu M, Katada H. A newly proposed method to predict optimum occlusal vertical dimension. *J Prosthodont* 2015;24:287–90.
- Emami E, Michaud PL, Sallaleh I, Feine JS. Implant-assisted complete prostheses. *Periodontol* 2000;2014(66):119–31.

Corresponding author:

Dr Pierre-Luc Michaud
Dalhousie University
5981 University Ave
PO BOX 15000
Halifax, NS, B3H 4R2
CANADA
Email: PL.Michaud@Dal.ca

Acknowledgments

The authors thank periodontics instructors, Dr Tamara Wright and Dr Jean-Pierre Lacroix for supervising the surgical component of the treatment; and the staff at the Graduate Periodontics clinic, Dalhousie University, Halifax, Nova Scotia.

Copyright © 2016 by the Editorial Council for *The Journal of Prosthetic Dentistry*.