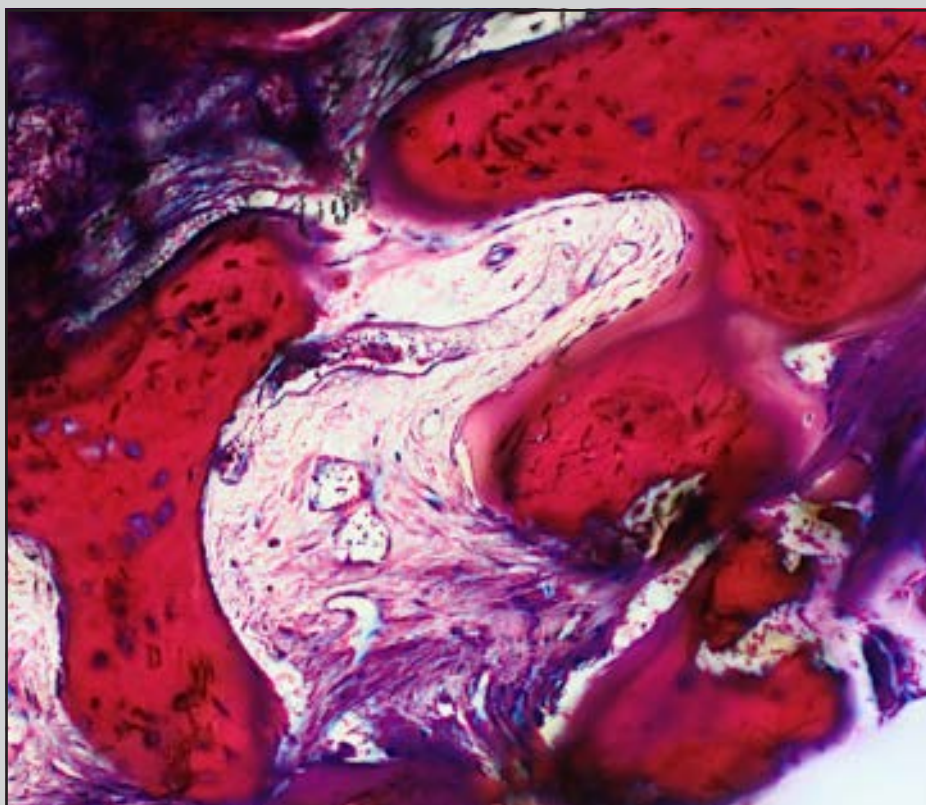

Choukroun Platelet-Rich Fibrin as an Autogenous Graft Biomaterial in Preimplant Surgery: Results of a Preliminary Randomized, Human Histomorphometric, Split-Mouth Study



Jonathan Du Toit, BChD, Dip Oral Surg,
Dipl Implantol, MSc Dent¹
Andreas Siebold, BChD, MChD (OMP)²
Andries Dreyer, BSc Med Sci, BDS, MChD (MFOS), MBChB³
Howard Gluckman, BDS, MChD (OMP)⁴

This study aimed to test the null hypothesis that platelet-rich fibrin (PRF), as an immediate postextraction graft material, produces bone that is histomorphometrically no different than bone derived from healing without intervention. The authors compared split-mouth human bone biopsy specimens derived from PRF with bone that had healed without intervention. Eight human bone biopsies were successfully harvested from four patients. The mean \pm standard deviation (SD) percent of newly formed osteoid was $9.9\% \pm 5.9\%$ for specimens derived from PRF, and $4\% \pm 2.1\%$ for specimens derived from the control sites ($P = .089$; 95% confidence interval [CI] 4.5–18.1 and 1.6–6.6, respectively). Mean \pm SD percent of new mineralized bone was $40.8\% \pm 10.3\%$ for the PRF specimens and $43.9\% \pm 16.8\%$ for the control specimens ($P = .72$, 95% CI, 33.4–55.6 and 19.3–55.5, respectively). Newly formed bone to fibrovascular tissue ratios for specimens in the PRF and control groups were 51%:49% and 48%:52%, respectively. Within the limitations of this study, the null hypothesis could not be rejected. Bone derived from PRF histologically did not differ from bone that healed without intervention. Int J Periodontics Restorative Dent 2016;36(suppl):s75–s86. doi: 10.11607/prd.2749

¹Postgraduate, Department of Periodontics and Oral Medicine, School of Dentistry, Faculty of Health Sciences, University of Pretoria, Pretoria, South Africa.

²Specialist and Consultant, Department of Oral Medicine & Periodontology, University of the Witwatersrand, School of Oral Health Sciences, Johannesburg, South Africa.

³Oral and Maxillofacial Surgeon, Department of Oral & Maxillofacial Surgery, Medical University of South Africa, Pretoria, South Africa.

⁴Specialist in Periodontics and Oral Medicine, Director of the Implant and Aesthetic Academy, Cape Town, South Africa.

Correspondence to: Dr Jonathan Du Toit, Department of Periodontics and Oral Medicine, School of Dentistry, Faculty of Health Sciences, University of Pretoria, Private bag X20 Hatfield, Pretoria, South Africa 0028.
Email: drjondu@gmail.com

©2016 by Quintessence Publishing Co Inc.

The tooth extraction socket remains a significant challenge in restorative implant treatment.¹ Marked dimensional changes occur during the first 8 weeks after tooth extraction, especially in the buccal or facial aspect.² Without intervention, the alveolar ridge will lose bone volume, and its form will change as the bony socket undergoes resorption, modeling, and healing.³ Among the treatment options for a missing tooth or teeth is the surgical placement of a dental implant, which provides a structural foundation for the restorative rehabilitation.⁴ Successful placement of a dental implant requires healthy supporting bone of adequate architecture.⁵ Areas of tissue deficit may not allow for the ideal prosthodontically planned placement of an implant; bone and soft-tissue augmentation may first be required.^{6,7} These procedures, be they preventive (pretissue loss) or corrective (postextraction tissue loss), require among many things the access to augmentation materials. Conventional autogenous bone harvesting sites (eg, mandible, palate, pelvis) are surgically invasive, traumatic, and technique-sensitive.⁸ Alternatively, graft material may be obtained from outside the host. More convenient alternatives are costly and require access to commercially prepared animal, synthetic, or human bone products.⁹

Table 1 Eligibility criteria for the study's participants

Selection criteria	
Inclusion criteria	Exclusion criteria
<ul style="list-style-type: none"> • Having two similar, single-rooted, and unsalvageable or hopeless teeth that were planned for extraction and subsequent dental implant therapy • Being identified to receive delayed placement of dental implants after tooth extraction • Having two teeth located within the maxilla only • Having two teeth that would leave an extraction socket measuring 7 mm deep by 2 mm in diameter when healed, from which core biopsy specimens could be harvested as part of the osteotomy preparation, in the ideal prosthodontic position, and as determined by a surgical guide • Not having any social, dental, or medical disadvantages for dental implants and exhibiting the following: <ul style="list-style-type: none"> - Being motivated toward the treatment - Being motivated to participate - Having good oral hygiene - Having no medically compromising conditions 	<ul style="list-style-type: none"> • Failing to meet accepted practice indications for treatment of missing teeth by dental implant-supported restorations • Having active periodontitis • Having loss of the buccal, lingual, or palatal bone plate during tooth extraction • Having mandibular teeth planned for extraction • Having molar teeth planned for extraction, with the exception of multirrooted first premolar teeth, if the interseptal bone within the socket was not shallower than 7 mm (verifiable with the trephine bur at the extraction visit) • Aged 18 years or younger • Currently smoking • Not consenting to participate in the study • Being unmotivated and unable to comply with the study's follow-up requirements

The use of platelet concentrates in healing and augmentation has been reported for more than 40 years.^{10,11} Their preparations have evolved, yet all methods involve the centrifugation of a patient's own blood, with or without additional preparation steps or additives, to derive an autogenous biomaterial.¹² Their most widespread applications are as intraoral graft materials. One of the most commonly reported platelet concentrates is Choukroun PRF—a leukocyte- and platelet-rich fibrin. A search of the PubMed database using the terms *platelet*, *rich*,

fibrin, and *PRF* returns 286 publications. This material is prepared by centrifuging a sample of the patient's own blood and separating it into platelet-poor plasma, a platelet-rich fibrin clot, and red blood cells (Fig 1).¹³ PRF is autogenous in that the blood sample is derived from the patient requiring the augmentation then processed externally, free of additives, and—as with autografts—is reimplanted to the surgical site in the same patient. PRF in implant surgery has been reported on extensively over the last two decades, although literature report-

ing objective, histologic analyses of bone healed from PRF is lacking.^{14–16} No gold standard exists regarding which platelet concentrate to use as an intraoral graft material, providing bone and soft tissue more suitable at dental implant sites.

The purpose of this study was thus to investigate and report on the application of Choukroun PRF in pre-implant surgery, including histologic findings of this PRF in healed and healing bone. The proposed null hypothesis was that the use of PRF as an immediate post-tooth extraction graft material produces bone that is histomorphometrically no different from bone derived from tooth sockets healing without any grafting.

Materials and methods

Study design and randomization

The research protocol was examined and approved by the Human Research Ethics Committee (Medical) at the University of the Witwatersrand in Johannesburg, South Africa. This approval was in accordance with the World Medical Association Declaration of Helsinki (ethics senate registration number M130462).

Patients presenting to the private practice of the study's treating clinician (AD) for implant therapy who met the study's eligibility criteria (Table 1) were invited to participate by informed and signed consent. Participants were randomly assigned to one of two groups using the following randomization system,

which was devised to ensure limited bias: Computer randomization ordered the word pairing *PRF* and *control* and allocated these words to the two teeth per participant in a split-mouth fashion: first tooth, control, and second tooth, PRF. (A detailed description of the study's randomization methodology is available at www.prfresearch.org). The words *PRF* and *control* were randomly allocated to integers 1 and 2. This randomization was compiled into a chart (Table 2) and concealed individually with black adhesive tape. Immediately before socket grafting, the tape was removed to reveal the allocation of PRF and control sites. The chart also recorded all clinical information. Participants were blinded to tooth allocation with a surgical drape and with both sites being "manipulated" with sutures. This blinding was to prevent participants from treating the wounds differently.

Table 2 Examples from the randomization chart, concealing the allocation of test and control sites, and recording treatment and patient information.

Participant	Tooth	Site	Tooth no.	Date/time of extraction	Date/time of biopsy	Participant name
1	1st	PRF	13	1/7/15	7 Apr'15	John Doe
	2nd	Control	21	09:00	11:00	
2	1st	Control	11	2/3/15	5/3/15	Jane Doe
	2nd	PRF	21	07:00	15:00	
3	1st	Control	13	3/26/15	6/26/15	Sam Smith
	2nd	PRF	21	11:00	14:00	

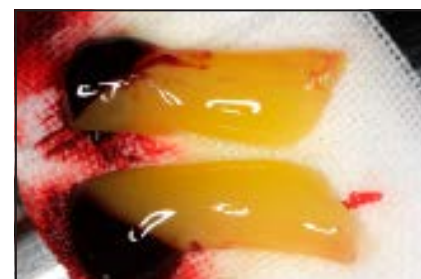
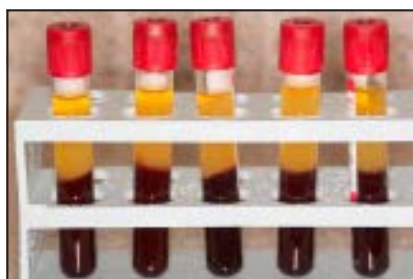


Fig 1 (a) The platelet-rich fibrin tubes immediately after centrifugation. (b) The platelet-rich fibrin clots separated from red blood cells coagulum. Printed with permission for use in this research from Dr Cliff Leachman, BC, Canada.

Extraction

All study participants were treated by a single oral surgeon (AD) experienced in graft procedures, the use of PRF, and implant surgery. All equipment, instruments, techniques, procedures, and the PRF protocol were standardized throughout this study. Patients were identified for participation in the study if they received a diagnosis of two nonmolar hopeless teeth requiring extraction (Fig 2a), if they desired to have a restoration after delayed implant placement, and if the additional eligibility criteria were met (Table 1). Teeth were removed using a minimally trau-

matic extraction technique. After patients received a 4% articaine with epinephrine local anesthetic solution (1:200,000; Ubistesin Forte, 3M ESPE), flapless removal of the teeth was performed by severing the attached gingiva circumferentially from the tooth crown. No other incisions were made. The tooth crown (if present) and roots were sectioned, the periodontal ligament severed by standard periosteal, and the tooth fragments delivered carefully by elevation to preserve the alveolar bone where at all possible. The buccal bone was specifically avoided

as an elevation purchase. If buccal, lingual, or palatal bone plates were damaged during the procedure or if a dehiscence was present, the extraction site was excluded from the study. Any signs of infection were cleared from the socket after extraction.

PRF grafting

The PRF was prepared strictly according to the Choukroun protocol.¹³ Its preparation was initiated before the extraction of teeth, as

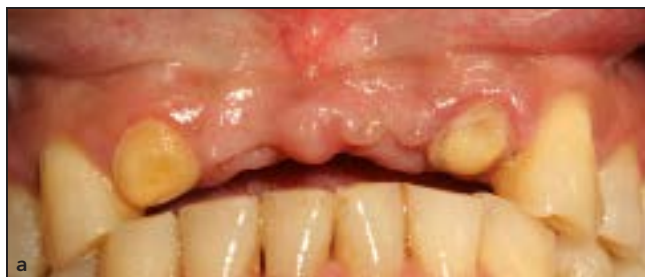
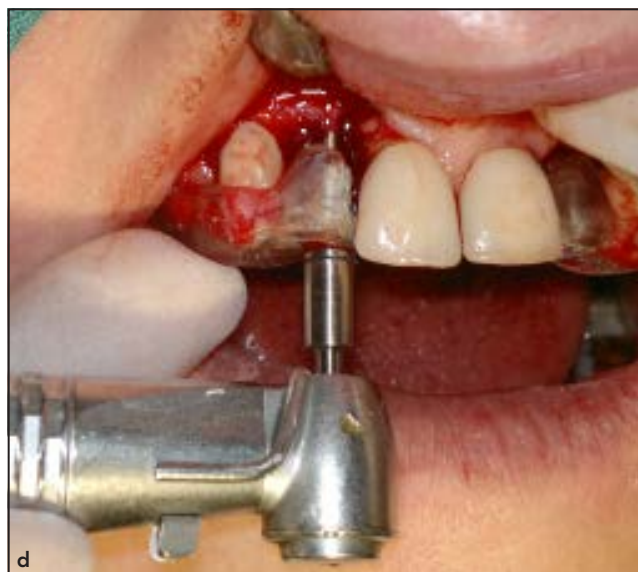
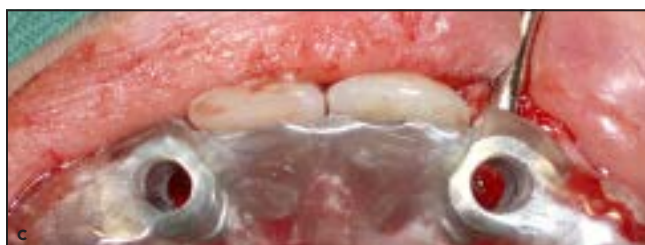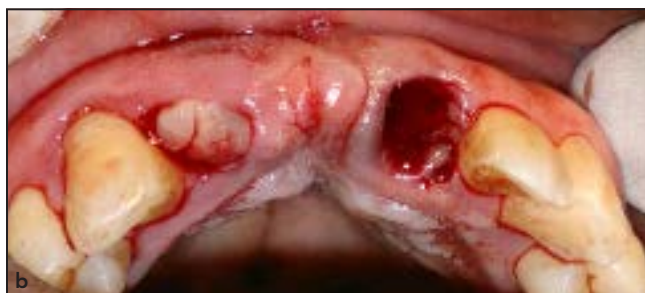Fig 2 (a) Preoperative view of a participant's teeth. (b) Platelet-rich fibrin clots inserted into a test socket (#7) and no intervention to the control site (#9). (c, d) Biopsy and implant insertion after 90 days of healing using the surgical guide. Printed with permission for use in this research from Dr Christopher Centeno, CO, USA.



approximately 20 minutes elapse until the PRF clot is ready for insertion. Two blood samples were drawn from each participant using venipuncture in 10-mL, anticoagulant-free, Choukroun original PRF tubes (Process) and a Choukroun centrifuge (EBA 20, Hettich) was used in this study. The tubes were placed directly opposite each other, counterbalancing their weight, and then centrifuged for 10 minutes at 3,000 rpm. After the cycle's completion, the tubes were removed and three distinct strata were noted: a top layer (cloudy, acellular blood plasma), a middle layer (the yellow-opaque PRF clot), and a lower layer

(red blood cells) (Fig 1a). Sterile tissue forceps removed the solid mass that was the PRF clot attached to the red blood cells. The mass was placed on a sterile working surface, and the red blood cells were scraped away with a sterile spatula from the Choukroun PRF kit (Process) (Fig 1b). The PRF clots were then left on this sterile surface for an additional 10 minutes to release any contained serum, as per the Choukroun protocol. Once the teeth were removed and the randomization chart consulted to identify the allocation of the test socket, the PRF clots were transferred to the mouth and placed in the tooth socket (Fig 2b).^{2,3} Simple

interrupted chromic catgut sutures (size 5.0) were placed passively over both sockets, which contained either the whole blood clot or the PRF clot, depending on the group to which it was assigned. An impression was taken of the upper jaw (Aqualsil, Dentsply) for the construction of an implant surgical and biopsy guide. Any participant with a removable partial denture had the fitting surface over the wounds reduced and a tissue conditioner (Visco-gel, Dentsply) placed to limit mechanical impact to the healing sites. Postoperative instructions were then given to the participants (Table 3), and they were dismissed.

Trephined bone core biopsy

Biopsy procedures were performed as described by Nevins and colleagues.^{17,18} The procedure was first tested by retrieving a single bone core after periodontal regeneration in a chacma baboon so as to familiarize the lab staff with the methodology and preparation of histologic sections. A delayed implant placement protocol was followed in all participants, and implants were placed at the extraction sites after 90 days of healing (Fig 3). A hollow trephine bur (2.8 mm wide and 7 mm long; ACE EasyRetrieve, ACE Surgical) replaced the implant pilot drill. After local anesthesia was applied to the sites as previously described, implant osteotomies were sequentially prepared by means of the surgical and biopsy guide (Figs 2c and 2d). The trephine bur retrieved a bone core (2 mm × 7 mm) from each of the PRF and control sites (Fig 4). The trephine's unique plunger delivered bone cores undamaged directly into a biopsy container containing a 70% ethanol fixative. These containers were then sealed and couriered for laboratory preparation.

Histologic preparation

The bone samples were prepared for histomorphometric evaluation—the criterion standard for obtaining quantitative information on bone structure and remodeling.¹⁹ The fixed, undecalcified biopsy specimens were dehydrated, infiltrated, and then slowly embedded in Technovit 7200

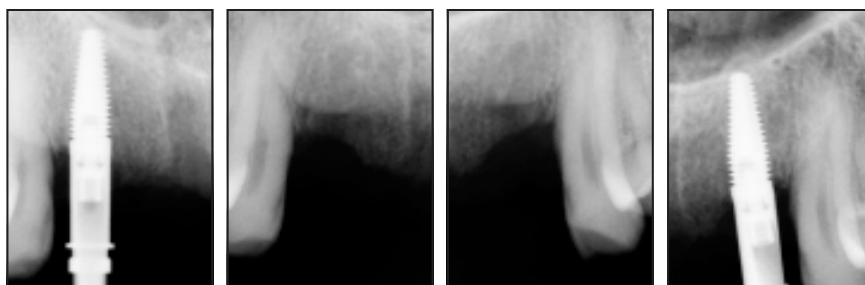


Fig 3 Biopsy specimen retrieval and implant insertion after 90 days of healing at the PRF site (far left, middle left) and control site (far right, middle right).

Table 3 Postoperative instructions given to participants verbally and in writing

1	Do not rinse or drink for the first hour after the procedure.
2	Gently rinse with a saline solution for 3 days after tooth extraction.
3	Adhere to a soft diet and take care not to traumatize the healing sites during the first 2 weeks after the procedure, which are critical for soft-tissue healing.
4	Maintain oral hygiene by brushing and flossing, but take meticulous care not to brush the tooth surfaces directly adjacent to the extraction sites for a minimum of 2 weeks after the procedure. Thereafter, the tooth surfaces adjacent to the edentulous spaces may be flossed and brushed gently and regularly to remove plaque accumulation.
5	Do not participate in sports or strenuous activity for the first week after the procedure.
6	Report for follow-up visits at 2 days and then at 1 week after the procedure to ensure the wounds are free of complication and to validate healing progress and oral hygiene maintenance.
7	Report for a follow-up visit after exactly 90 days of healing. (This date was written on the participant's postoperative instructions leaflet.)

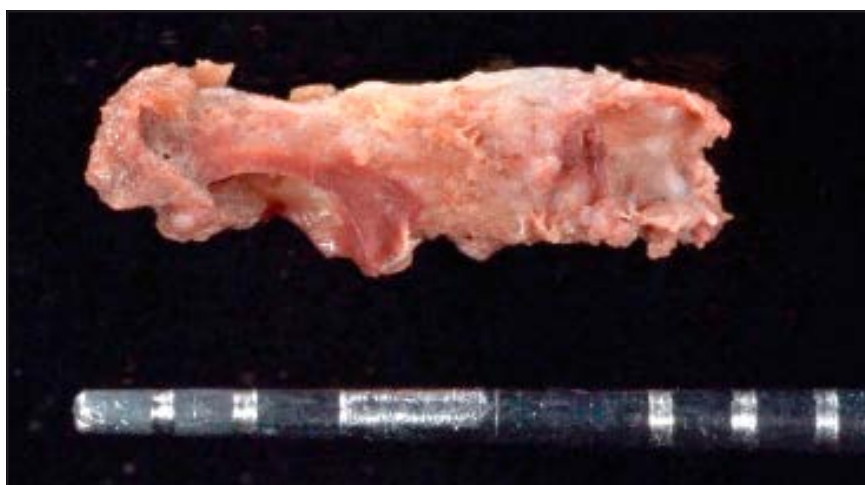

Fig 4 Trephined bone core (2 mm × 7 mm) next to a UNC15 probe for size reference.

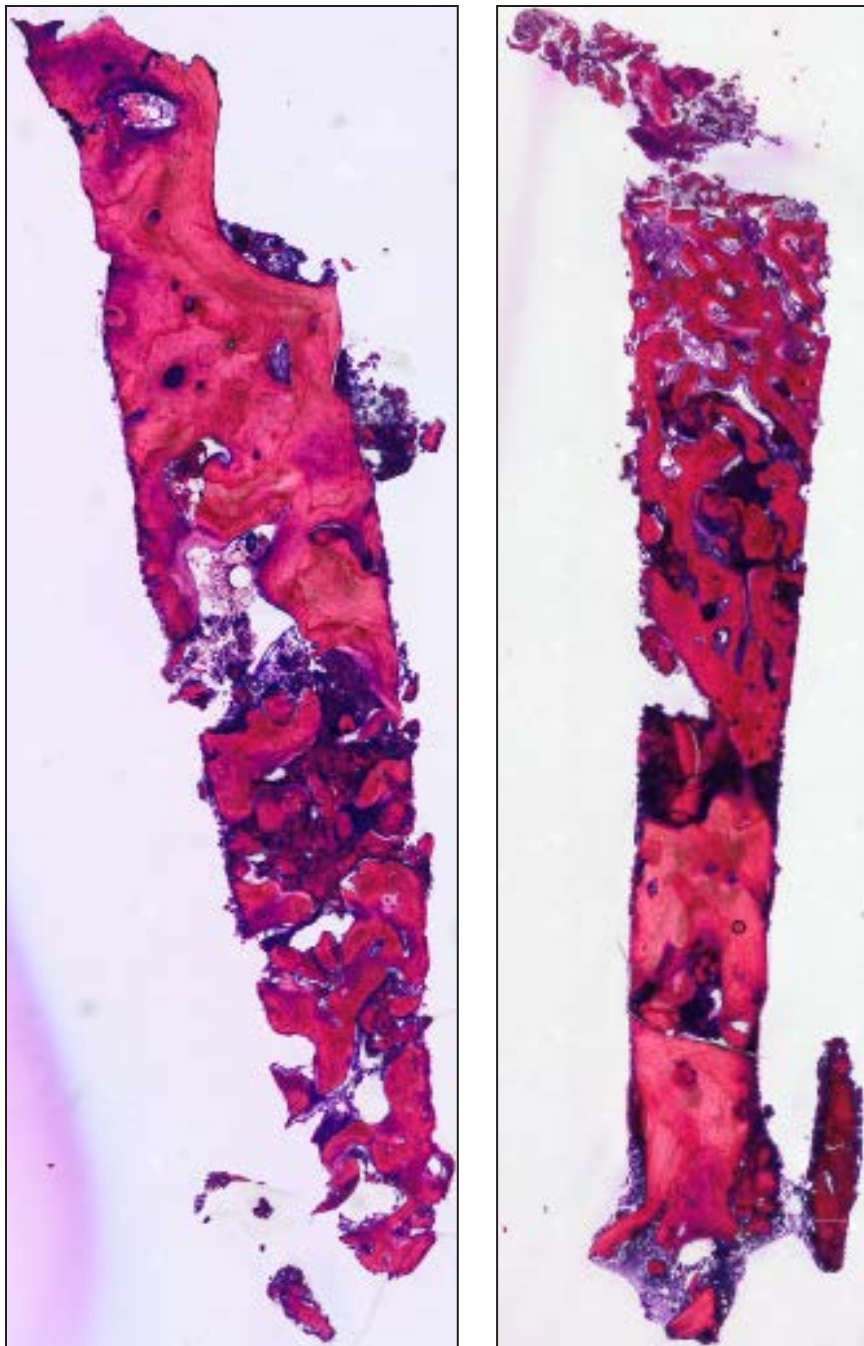


Fig 5 Trephined core biopsy specimen of platelet-rich fibrin bone after 90 days of healing. Undecalcified section, methylene blue-basic fuchsin stain ($\times 10$ magnification).

embedding media (EXAKT Technologies), as described by Nevins et al.²⁰ The biopsy specimens, each embedded in a resin block, were cut with

a diamond saw into sections and then polished down using a series of abrasive papers to roughly 10 μM (EXAKT 400 CS, EXAKT Technolo-

gies). The sections were then stained with methylene blue-basic fuchsin, as described by D'Amico²¹ (Fig 5).

Histomorphometric analysis

An Olympus BX63 research microscope (Olympus Optical) with a mounted Olympus XC10 digital imaging system captured high-resolution digital VSI images of the prepared histologic slides (Figs 5a and 5b). The images were then processed using Olympus Stream Essentials software (version 1.9, Olympus Optical). The stain distinguished mineralized tissues as cerise-purple, osteoid tissue as fuchsia-purple, and fibrovascular tissue as dark purple (Fig 6). The software allowed for manually tracing the outlines of every tissue component (Fig 7), totaling a surface area (μM^2) for each specimen, and exporting the collected data to individual Excel spreadsheets (MS Office, Microsoft).

Biostatistics

This study was powered against the Tanaka et al participant human biopsy study.²² A Wilcoxon rank sum test determined skewness and kurtosis of the prepared and compiled data. From these data, the z scores for the PRF and control groups were calculated to determine the normality of the distributed results. The data were then analyzed using SPSS statistical software (version 22.0, SPSS Statistics, IBM). A paired t test calculated population means with

standard deviations for both PRF and control groups and provided information regarding the statistical significance of the findings.

Results

The schedules of treatment for each participant followed near identically the methodology laid out in the research protocol. Four participants were included in this study; three men aged 38, 43, and 46 years, respectively, and one woman, aged 31 years (Table 4). Postsurgical healing was uneventful, and no patients were lost to follow-up. PRF and control biopsy specimens were successfully harvested from each of the four participants, for a total of eight samples. All biopsy specimens were harvested as close as possible to 90 days (mean, 92 days) after the extraction of teeth.

Histomorphometric evaluation

Histomorphometric evaluation of the samples identified the components of the healing alveolar bone derived from the extraction sockets by their orientation and respective staining shades and colors. Newly formed osteoid stained purple and lined the islands of new mineralized bone. Surprisingly, the osteoid had in some areas diffuse white-purple, nonstained, or lesser-stained regions. This osteoid in general was observed as a miniscule lining at the trabeculae peripheries, broadening in areas into a wider band of tissue, and was populated at

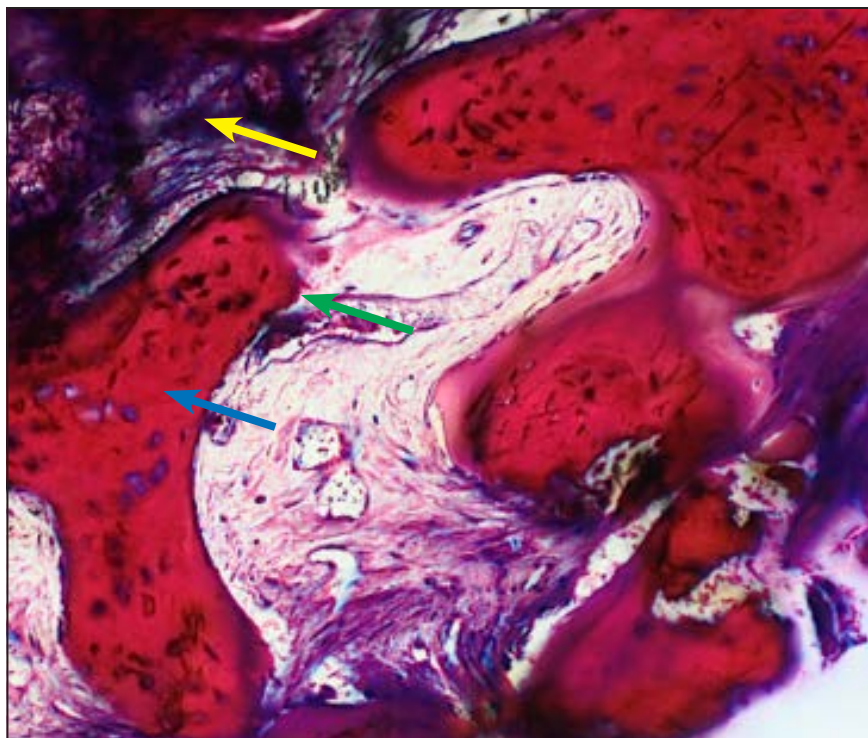


Fig 6 New mineralized bone shown as cerise-purple stain (blue arrow), osteoid shown as fuchsia-purple stain (green arrow), and fibrovascular tissue shown as dark-purple stain (yellow arrow).

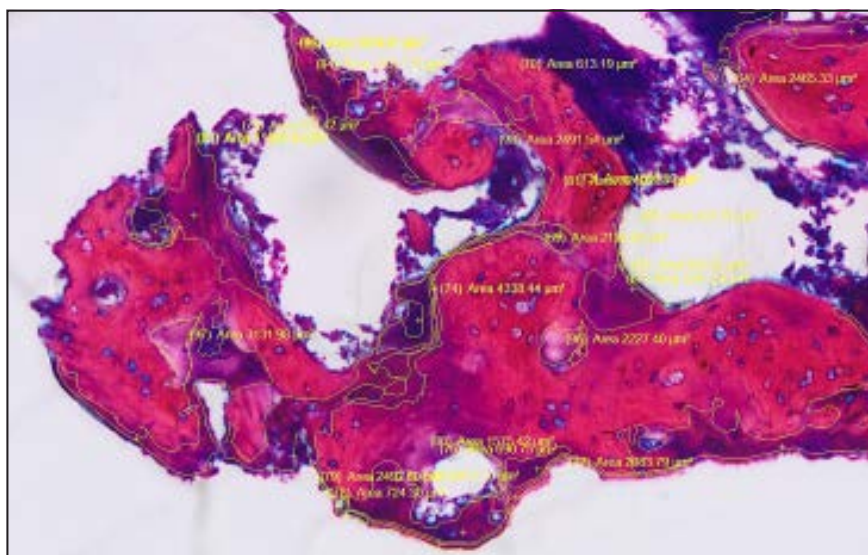


Fig 7 Manual tracing of tissue compartments at high magnification completed using Stream Essentials software (Olympus).

its borders by plump, dark blue-purple-staining osteoblasts.

The new mineralized bone was seen as islands of more reddish

cerise-purple, with fine white flecks, and was populated distinctly by numerous lacunae. These lacunae were observed as pinpoints of white

Table 4 Amounts of newly formed osteoid, new mineralized bone, and fibrovascular tissue in human bone biopsy specimens derived from platelet-rich fibrin and those that received no intervention

Measure		Participant							
		Test				Control			
		1	2	3	4	1	2	3	4
Newly formed osteoid	mm ²	220	434	275	141	84	223	140	124
	%	7	18.1	9.8	4.5	1.6	6.6	3.2	4.5
Mean value ± standard deviation		9.9 ± 5.9				4 ± 2.1			
Significance (α = .05)		P = .089							
New mineralized bone	mm ²	1,090	963	1,551	1,060	994	1,572	2,341	1,546
	%	34	40.2	55.6	33.4	19.3	46.6	54	55.5
Mean value ± standard deviation		40.8 ± 10.3				43.9 ± 16.8			
Significance (α = .05)		P = .718							
Fibrovascular tissue	mm ²	1,892	999	962	1,970	4,087	1,578	1,851	113
	%	59	41.7	34.5	62.1	79.1	46.8	42.8	40
Mean value ± standard deviation		49.3 ± 13.4				52.1 ± 18.2			
Significance (α = .05)		P = .77							
Total surface area of specimen	mm ²	3,202	2,396	2,788	3,171	5,165	3,373	4,332	2,783
	%	100	100	100	100	100	100	100	100
Total newly formed bone (osteoid + new mineralized)	%	41	58.3	65.4	37.9	20.9	53.3	57.2	60
	Mean value ± standard deviation		50.7 ± 13.3				47.9 ± 18.1		
Significance (α = .05)		P = .774							

spaces with dark-purple-staining osteocytes at their centers. Within or between these islands of new mineralized bone were darker and more densely stained regions of blue-black-purple fibrovascular connective tissue. These regions frequently contained white, vacuous spaces. Such spaces were not areas of interest and were disregarded from the software mapping of the total surface areas.

The specimens also had areas identified as residual bone—mature mineralized bone that with certainty could not be from the newly healing extraction socket and were

most likely the biopsy trephine bur penetrating part of the original socket wall. These areas were also excluded from the histomorphometric evaluations and thus did not contribute to the total surface areas against which the percentages of newly formed osteoid, new mineralized bone, and fibrovascular tissue quantities were calculated. The areas of residual bone were populated with lacunae and stained light cerise-pink with diffuse white-pink regions within them. Striate were observed within these regions and at their peripheries, seen as examples of creeping substitution. Nine-

ty days after the procedures, PRF could not be distinguished.

Statistical analyses

Histomorphometric evaluation of the samples mapped the bone surface areas for newly formed osteoid in the PRF group at 7%, 18.1%, 9.8%, and 4.5% for each participant, respectively. New mineralized bone in the PRF group comprised 34%, 40.2%, 55.6%, and 33.4% for each participant, respectively (Figs 8a and 8b). Fibrovascular connective tissue in this group was found to be

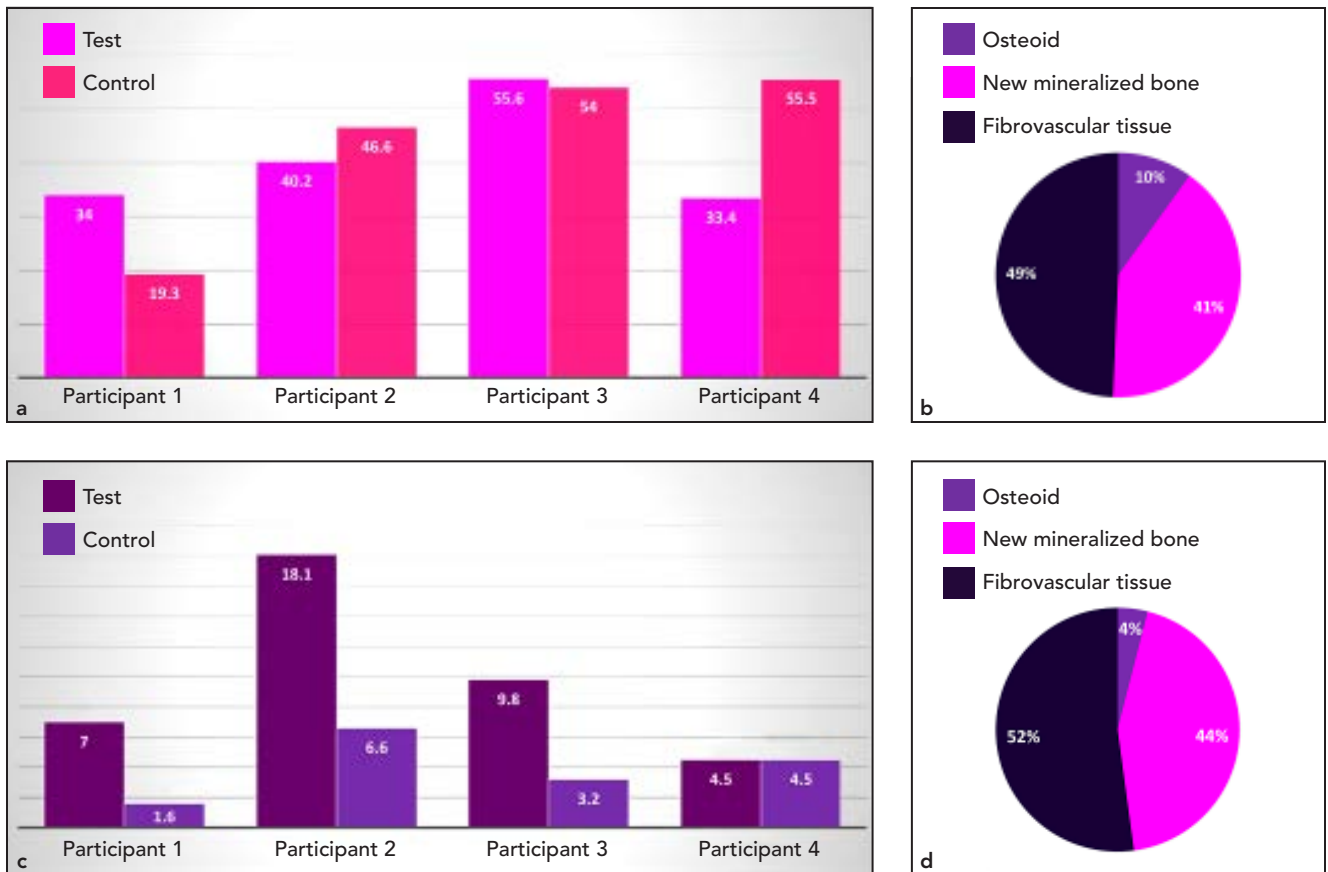


Fig 8 Results of comparisons between test and control sites (%) for (a) new mineralized bone and (b) osteoid. Visual quantification of newly formed bone to fibrovascular tissue ratios, (c) test and (d) control.

59%, 41.7%, 34.5%, and 62.1% for each participant, respectively. The data were analyzed to determine normality of distribution. The results were slightly skewed and kurtotic. However, the z score was calculated at -0.22 ($z = -0.57/2.57$), indicating that results were approximately normally distributed in terms of skewness and kurtosis, and a paired t test was applied ($-1.96 \leq z \leq 1.96$). Paired t tests comparing the means of newly formed bone (both osteoid and new mineralized bone) indicated near identical amounts in the PRF and control groups (mean \pm SD, $50.7\% \pm 13.3\%$, and $47.9\% \pm 18.1\%$,

respectively) (Table 4). At a confidence interval of 95%, the results were not shown to be statistically significant. After 90 days of healing, amounts of newly formed bone (both osteoid and new mineralized bone) and fibrovascular tissue were comparable between the PRF and control groups (Figs 8c and 8d).

Discussion

This study set out to evaluate the use of PRF as an autogenous graft material for use in preimplant surgery, specifically its effect on healing

alveolar bone. Evaluation of biopsy specimens retrieved after 90 days of healing showed newly formed bone derived from PRF that was comparable to bone having healed without any intervention. Within the limitations of this study, PRF had no significant effect on the healing of alveolar bone. The null hypothesis could not be rejected.

The mean quantities of newly formed bone and fibrovascular tissue were 51% and 49% for the PRF group and 48% and 52% for the control group. To correlate these results with available literature would be speculative because the bone

quantified in this study was immature tissue harvested at 12 weeks (as per Ripamonti's protocol)²³ and the limited human histologic data available in the literature are based on mineral, matrix, cancellous, and cortical compartments derived from fully healed sites within the jaws.²⁴ In addition, histologic descriptions in the literature are not congruent. The biopsy specimens harvested in a study by Lindhe et al,²⁴ for example, were found to have both cortical and cancellous bone. The findings of this study cannot be compared with Lindhe et al's results because a healing alveolus at 12 weeks has no cortex. The literature is also replete with studies reporting on the relationship between growth factors and their stimulus for bone healing.^{17,18,20,25} Again, within the limitations of this study, these promising effects could not histologically be demonstrated.

The complex methodology in this study was developed to conform to strict selection criteria to locate ideal participants, as could be expected in any split-mouth study involving such implant therapy. If the study were to be duplicated, revisions to the methodology may or may not reject the null hypothesis. The initial rationale was to replace a pilot implant drill for preparation of the osteotomy with a hollow, trephine bur of similar size to retrieve a core of the participant's bone from the healed or healing site and evaluate its histologic properties. The PRF and control extraction sockets were from single-rooted teeth, and molar sites were excluded to avoid the harvesting of residual bone. The

surgical guides were manufactured from stone models cast from impressions of the extraction sockets. Guide rings were positioned over the sockets and prosthodontically planned acrylic surgical guides were constructed. However, a surgical guide for restorative positioning of implant placement, and a surgical guide for a trephined biopsy for this study's purpose, do not coincide. Harvesting a biopsy specimen using a prosthodontically planned surgical guide derived a core of bone that included residual bone, and the socket wall was penetrated in all cases.

To improve upon the current study's protocol, separate guides for each purpose need to be constructed. An approximate biopsy guide needs to be ready at the time of extraction. After the guide is positioned, the trephine bur should be placed within it (similar to an open tray impression technique) and then into the extraction socket in the intended biopsy position. A prepared cold cure acrylic resin should be applied around the socket and left to set. In this manner, the ideal biopsy position can be recorded. In most cases, it would be inappropriate to prepare a pilot osteotomy to derive a biopsy core of bone from the center of these healing sockets as an implant placement strategy. In this study, the surgical guides contained guide rings that allowed for minor correction of angulation. In addition, the trephine bur was angulated more palatally in all cases to prepare osteotomies that were not off the ridge, facilitating implant placement and biopsies.

In addition, future studies should not be limited to anterior extraction sockets. Molar and premolar sites should also be included. As described previously, the trephine bur's position (eg, within the palatal root socket of a molar tooth) could be recorded in cold cure acrylic resin within the guide for future accurate retrieval of a biopsy specimen comprising solely newly formed bone.

Moreover, finding participants satisfying all the selection criteria was challenging. Although such suitable participants were critical to the study's validity, the low number of participants was a limitation. However, the present study examined an equal number of human histologic samples as notable studies that have substantially contributed to the bone regeneration knowledge base.¹⁷ To date, no blinded and randomized controlled trial performed as a split-mouth study of PRF from healed bone and ruling out interparticipant confounding factors (eg, age, healing, health, habits, genetics) has been reported in the literature. Modifying the current study's selection criteria to comprise all interparticipant single tooth extraction sites for comparison may stimulate a statistically powered study. For example, Araújo²⁶ and Lindhe,²⁴ two of the most prominent researchers on the topic of the healing periodontium, reported on the grafting of extraction sockets, comparing single sites between participants. Their results, however, are subject to confounding factors related to variation in interparticipant healing and thus also to critique.

It would also be counterproductive to exclude mandibular extraction sites. The literature reports on differences in healing between the mandible and the maxilla; however, the healing is oriented around osseointegration of implants, grafting defects by guided bone regeneration, and alveolar bone regeneration in the jaws by internal fixation—not of extraction sockets.²⁶ It is arguable whether immature bone and osteoid within an extraction socket after 90 days of healing would differ significantly enough between the jaws to confound results. In future studies, graft material should be applied in a range of patients and in both jaws.

In this study, bones were harvested after 90 days of healing, as described by Ripamonti.²³ After 90 days, sufficient amounts of newly formed bone should be available for examination, without having been mineralized to an extent that it cannot be distinguished from residual bone. The biopsy specimens in this study were harvested as close to 90 days as possible (mean, 92 days), and active osteoblast fronts at the peripheries of new mineralized bone with actively growing osteoid surrounded by dense fibrovascular tissue could be observed. But if after 3 months of healing the type of bone is statistically no different when grafted with PRF, the cost benefit of such therapy is unclear. Grafting with PRF requires additional equipment, time, skills, and patient compliance, and may or may not incur additional cost to the patient. The benefit needs to justify these costs. Today, a lot of research

and consensus statements seek to investigate and report on earlier entry to place dental implants, be it immediate or early-immediate.^{27–29} If PRF can stimulate more rapid healing, seen as increased newly formed bone and faster mineralization, then it supports the hypothesis that grafting defects and extraction sockets with PRF promotes earlier entry to place implants for faster treatment and restoration of edentulous and partially edentulous patients. In future studies, the participants should be randomized into groups that would have implants placed and bone biopsies retrieved at 30, 60, and 90 days after healing, so the bone can be compared at different stages.

Conclusions

The histologic findings from this study's human biopsy specimens revealed no statistical difference between test and control group findings. Therefore, this study, with its limitations, could not demonstrate that grafting extraction sockets with PRF produces alveolar bone histomorphometrically any different from bone that heals within sockets without grafting.

Acknowledgments

The authors reported no conflicts of interest.

References

1. Hammerle CH, Araújo MG, Simion M. Evidence-based knowledge on the biology and treatment of extraction sockets. *Clin Oral Implants Res* 2011;23(suppl 5):80–82.
2. Araújo MG, Sukekava F, Wennström JL, Lindhe J. Ridge alterations following implant placement in fresh extraction sockets: An experimental study in the dog. *J Clin Periodontol* 2005;32:645–652.
3. Nevins M, Camelo M, De Paoli S, et al. A study of the fate of the buccal wall of extraction sockets of teeth with prominent roots. *Int J Periodontics Restorative Dent* 2006;26:19–29.
4. Alani A, Austin R, Djemal S. Contemporary management of tooth replacement in the traumatized dentition. *Dent Traumatol* 2012;28:183–192.
5. Atsu SS. A surgical guide for dental implant placement in edentulous posterior regions. *J Prosthet Dent* 2006;96:129–133.
6. Chiapasco M, Casentini P, Zaniboni M. Bone augmentation procedures in implant dentistry. *Int J Oral Maxillofac Implants* 2009;24(suppl):237–259.
7. Darby I, Chen ST, Buser D. Ridge preservation techniques for implant therapy. *Int J Oral Maxillofac Implants* 2009;24(suppl):260–271.
8. Zubillaga G, Von Hagen S, Simon BI, Deasy MJ. Changes in alveolar bone height and width following post-extraction ridge augmentation using a fixed bioabsorbable membrane and demineralized freeze-dried bone osteoinductive graft. *J Periodontol* 2003;74:965–975.
9. Misch CE, Dietsh F. Bone-grafting materials in implant dentistry. *Implant Dent* 1993;2(3):158–167.
10. Matras H. Effect of various fibrin preparations on reimplantations in the rat skin [in German]. *Osterr Z Stomatol* 1970;67:338–359.
11. Whitman DH, Berry RL, Green DM. Platelet gel: An autogenous alternative to fibrin glue with applications in oral and maxillofacial surgery. *J Oral Maxillofac Surg* 1997;55:1294–1299.
12. Ehrenfest DMD, Sammartino G, Shibli JA, Wang HL, Zou DR, Bernard JP. Guidelines for the publication of articles related to platelet concentrates (Platelet-Rich Plasma - PRP, or Platelet-Rich Fibrin - PRF): The international classification of the POSEIDO. *POSEIDO* 2013;1:17–26.

13. Dohan DM, Choukroun J, Diss A, et al. Platelet-rich fibrin (PRF): A second-generation platelet concentrate. Part I: Technological concepts and evolution. *Oral Med Oral Pathol Oral Radiol Endod* 2006;101:e37–e44.
14. Hauser F, Gaydarov N, Badoud I, Vazquez L, Bernard JP, Ammann P. Clinical and histological evaluation of postextraction platelet-rich fibrin socket filling: a prospective randomized controlled study. *Implant Dent* 2013;22:295–303.
15. Zhao JH, Tsai CH, Chang YC. Clinical and histologic evaluations of healing in an extraction socket filled with platelet-rich fibrin. *J Dent Sci* 2011;(6):116–122.
16. Zhang Y, Tangl S, Huber CD, Lin Y, Qiu L, Rausch-Fan X. Effects of Choukroun's platelet-rich fibrin on bone regeneration in combination with deproteinized bovine bone mineral in maxillary sinus augmentation: A histological and histomorphometric study. *J Craniomaxillofac Surg* 2012;40:321–328.
17. Nevins ML, Camelo M, Schupbach P, Kim DM, Camelo JM, Nevins M. Human histologic evaluation of mineralized collagen bone substitute and recombinant platelet-derived growth factor-BB to create bone for implant placement in extraction socket defects at 4 and 6 months: A case series. *Int J Periodontics Restorative Dent* 2009;29:129–139.
18. Nevins ML, Reynolds MA, Camelo M, Schupbach P, Kim DM, Nevins M. Recombinant human platelet-derived growth factor BB for reconstruction of human large extraction site defects. *Int J Periodontics Restorative Dent* 2014;34:157–163.
19. Parfitt AM. Vitamin D and the pathogenesis of rickets and osteomalacia. In: Feldman D, Glorieux FH. *Vitamin D*. San Diego: Academic Press, 2005:1029–1048.
20. Nevins M, Garber D, Hanratty JJ, et al. Human histologic evaluation of anorganic bovine bone mineral combined with recombinant human platelet-derived growth factor BB in maxillary sinus augmentation: Case series study. *Int J Periodontics Restorative Dent* 2009;29:583–591.
21. D'Amico F. A polychromatic staining method for epoxy embedded tissue: A new combination of methylene blue and basic fuchsin for light microscopy. *Bio-tech Histochem* 2005;80:207–210.
22. Tanaka H, Toyoshima T, Atsuta I, et al. Additional effects of platelet-rich fibrin on bone regeneration in sinus augmentation with deproteinized bovine bone mineral: Preliminary results. *Implant Dent* 2015 Jul 22 [Epub ahead of print].
23. Ripamonti U. Soluble and insoluble signals sculpt osteogenesis in angiogenesis. *World J Biol Chem* 2010;1:109–132.
24. Lindhe J, Bressan E, Cecchinato D, Corrá E, Toia M, Liljenberg B. Bone tissue in different parts of the edentulous maxilla and mandible. *Clin Oral Implants Res* 2013;24:372–377.
25. Nevins ML, Camelo M, Schupbach P, Nevins M, Kim SW, Kim DM. Human buccal plate extraction socket regeneration with recombinant human platelet-derived growth factor BB or enamel matrix derivative. *Int J Periodontics Restorative Dent* 2011;31:481–492.
26. Araújo MG, da Silva JC, de Mendonça AF, Lindhe J. Ridge alterations following grafting of fresh extraction sockets in man. A randomized clinical trial. *Clin Oral Implants Res* 2015;26:407–412.
27. Gallucci GO, Benic GI, Eckert SE, et al. Consensus statements and clinical recommendations for implant loading protocols. *Int J Oral Maxillofac Implants* 2014;(29, suppl):287–290.
28. Chen ST, Buser D. Esthetic outcomes following immediate and early implant placement in the anterior maxilla—a systematic review. *Int J Oral Maxillofac Implants* 2014;(29, suppl):186–215.
29. Chrcanovic BR, Albrektsson T, Wennerberg A. Dental implants inserted in fresh extraction sockets versus healed sites: A systematic review and meta-analysis. *J Dent* 2015;43:16–41.