

Bone Augmentation of the Edentulous Maxilla for Implant Placement: A Systematic Review

Tara L. Aghaloo, DDS, MD, PhD¹/Craig Misch, DDS, MDS²/Guo-Hao Lin, DDS³/
Vincent J. Iacono, DMD⁴/Hom-Lay Wang, DDS, MS, PhD⁵

Purpose: Multiple bone augmentation techniques are available to allow implant placement in the atrophic maxilla. However, questions remain, regarding which methods are most predictable and have the best dental implant survival rate (SR) in grafted bone. The aim of this systematic review was to evaluate literature from the last 30 years to determine predictability of bone grafting of the edentulous maxilla for implant placement as well as for implant SR. **Materials and Methods:** A systematic review was performed of studies conducted during the period 1980 to 2014, specifically focusing on the edentulous maxilla and bone grafting. Surgical techniques discussed in the publications included were guided bone regeneration (GBR), sinus augmentation, onlay bone grafting, nasal floor grafting, and Le Fort I interpositional grafting. All identified articles were evaluated and screened to meet strict inclusion criteria of at least 10 patients, complete maxillary edentulism, 1-year follow-up, and information regarding implant SR. A total of 974 articles were identified with electronic and manual searches. On further evaluation of the titles and abstracts, 44 articles were excluded. Full texts of the articles that met the inclusion criteria were reviewed, of which 40 articles were included in the systematic review. **Results:** For onlay bone grafting, 16 studies were included and analyzed, and the weighted mean implant SR was 85.2%. For the GBR technique, two studies were included, with a reported SR ranging from 96.1% to 100%. For Le Fort I interpositional grafting, 11 studies were included, with a weighted mean SR of 89.6%. For the sinus augmentation technique, 12 studies were investigated and the weighted mean SR was 91.5%. For the combination technique, six studies were analyzed and the weighted mean SR was 93.6%. **Conclusions:** All five treatment modalities discussed—onlay bone grafting, GBR, Le Fort I interpositional grafting, maxillary sinus augmentation, and/or nasal floor inlay grafting or the combination approach—can be successfully used to augment edentulous maxillary ridge with high implant SRs. *INT J ORAL MAXILLOFAC IMPLANTS* 2016;31(SUPPL):s19–s30. doi: 10.11607/jomi.16suppl.g1

Key words: bone augmentation, GBR, Le Fort I interpositional grafting, nasal floor grafting, onlay bone grafting, sinus augmentation

¹Professor and Assistant Dean for Clinical Research, Division of Diagnostic and Surgical Sciences, University of California—Los Angeles School of Dentistry, Los Angeles, California, USA.

²Clinical Associate Professor, Department of Implant Dentistry, New York University College of Dentistry, New York, NY, USA.

³Resident, Graduate Periodontics, Department of Periodontics and Oral Medicine, University of Michigan School of Dentistry, Ann Arbor, Michigan, USA.

⁴Professor and Chair, Department of Periodontology, School of Dental Medicine, Stony Brook University, Stony Brook, New York, USA.

⁵Professor and Program Director, Graduate Periodontics, Department of Periodontics and Oral Medicine, University of Michigan School of Dentistry, Ann Arbor, Michigan, USA.

Correspondence to: Dr Tara L. Aghaloo, UCLA School of Dentistry, 10833 Le Conte Ave, Box 951668, Los Angeles, CA 90095-1668, USA.

©2016 by Quintessence Publishing Co Inc.

Dental implant placement for edentulous patients has become a common and well-accepted treatment modality. When implant-supported prosthetic alternatives are considered, the clinician must evaluate the patient for adequate bone volume for implant placement in the desired locations. The success of implant procedures and maintenance of long-term stability are directly related to the quality and quantity of the supporting bone. Restoring the edentulous maxilla poses significant challenges for the treating clinician, especially in situations of severe ridge resorption.^{1–8} Alveolar bone resorption may result from trauma, periodontal disease, pathology, congenital deformities, ill-fitting prostheses, or disuse atrophy from long-term edentulism.^{5,9–12} It is now extremely uncommon to tell patients that they are not candidates for dental implants, even when their remaining bone is of inadequate quality or quantity. When

the residual ridge lacks the necessary bone volume for proper implant placement, bone augmentation procedures are one option to be used.

Various grafting procedures and materials are available to aid the implant surgeon in providing the ideal foundation for prosthetic rehabilitation.^{1,8,13,14} However, the edentulous maxilla is particularly challenging with regard to augmentation because of anatomic limitations, such as the nasal floor, maxillary sinus, resorption pattern, and interarch relationship.^{4,5} Implant survival rates (SRs) are generally lower in the maxilla than in the mandible, especially in the posterior maxilla where bone quality can be poor.^{10,15–20} In terms of maxillary augmentation techniques, sinus augmentation is the most predictable and documented procedure to support implants, in both short- and long-term studies.^{21–24} In addition, many longer-term studies (> 5 years) report high SRs and implant stability when more extensive grafting is performed in the edentulous maxilla to support implants,^{6,10,13,25,26} with an improvement in quality of life, esthetics, and function.^{6,27} In comparison, the management of the severely resorbed edentulous maxilla, without grafting to support implants, is a more recent technique requiring adequate bone in the anterior maxilla. These tilted implants, as well as zygomatic and short implant alternatives to avoid grafting, may result in less favorable prosthetic designs such as long cantilevers as well as speech, hygiene, or esthetic issues.^{28–31} Although anecdotally or preliminarily, implants in the edentulous maxilla without bone grafting demonstrate high SRs, they are not without technical difficulties and side effects.^{32–34} It is apparent that more studies are needed to document those results with confidence and to establish long-term follow-up data.

Augmentation facilitates improved placement for prosthetic support and contour, the ability to place a greater number of implants, longer- and/or wider-diameter implants, and less prosthetic cantilever.^{10,35} In cases with shorter implants, higher failure rates have been reported.^{36–40} More recent studies demonstrate similar SRs when no grafting is performed, using short or narrow implants.^{41,42} However, long-term implant success and prosthetic outcomes in the edentulous maxilla are still largely unknown.^{43–45} Much of the increased failure rates observed when extensive bone grafts are performed is directly related to the quality and quantity of bone and use of machined surface implants.³⁶ Variations in surgical technique, augmentation materials, and published outcomes makes it difficult to compare studies or to combine results in a meaningful manner, especially when focusing on the edentulous maxilla. Therefore, the aim of this systematic review was to evaluate literature from the last 30 years to determine predictability for bone augmentation in the edentulous maxilla for implant placement as well as implant survival.

MATERIALS AND METHODS

Inclusion and exclusion criteria were defined by the authors before beginning the study (Table 1).

Focus Question

The focus question developed using the PICO (population, intervention, comparison, outcome) format was related to grafting of the edentulous maxilla.

Study Type

Only clinical studies in humans and published in English were accepted for this systematic review. The clinical study had to include a minimum of 10 completely edentulous patients, irrespective of the number of treated patients for a given therapeutic option. Case reports, review articles, technical notes, and experimental studies were excluded from the systematic review.

Type and Area of Intervention

Horizontal, vertical, Le Fort I interpositional and nasal floor grafting, or sinus bone augmentation had to be performed in the completely edentulous maxilla.

Outcome Parameters and Follow-up Period

Studies were included provided they reported data about implant success and/or SRs of implants that were placed in conjunction with data on horizontal, vertical, Le Fort I procedure, nasal floor grafting, or sinus augmentation and that the implants had been loaded for a minimum period of 1 year.

Search Strategy

A PubMed electronic search was conducted to identify the potential articles for inclusion in this systematic review. The search included articles from 1980 to 2014. In addition, the following journals were hand searched for potential relevant articles: *Clinical Oral Implant Research* and *International Journal of Oral and Maxillofacial Implants*. Articles were selected using the following search terms: (“Edentulous” OR “Atrophic”) AND “Maxilla” AND “Augmentation” AND “Sinus” “NOT” Partial. This search was combined with search terms: “Horizontal” and “Vertical.” Duplicates were removed from the search. The authors individually screened the titles of the articles based on the inclusion criteria. If the title or abstract did not allow a clear decision to be made about inclusion, the full article was obtained. Based on the preselection, the full-text articles were then analyzed as to whether they met the inclusion criteria, and mutual agreement on the final selection of studies was obtained. Furthermore, the references of included studies were searched for publications that had not been identified electronically.

Search Combination

Search terms included the following: ((“Jaw, Edentulous”[Mesh:NoExp] OR edentulous[text word] OR atrophic[text word]) AND (“Maxilla”[Mesh] OR maxilla[text word])) AND (“Oral Surgical Procedures”[Mesh] OR graft*[text word] OR “bone regeneration”[text word] OR “guided bone regeneration”[text word] OR transplantation[MESH] OR transplantation[subheading]) OR ((bone[text word] OR vertical[text word] OR sinus[text word] OR “horizontal”[text word]) AND augmentation*[text word])) NOT partial* NOT (animals[mh] NOT humans[mh]).

Data Extraction

Articles were evaluated exactly as published, and no additional reference or contact with authors was sought. The two reviewers independently extracted the data from the selected publications. The following information was collected from the publications:

- Study design
- Comparison group
- Randomization
- Masking (single, double, not possible)
- Time of follow-up
- Number of patients
- Number of patients with edentulous maxillae
- Number of subject dropouts
- Number of implants
- Number of implants in edentulous maxillae
- Health condition
- Grafting technique
- Implant length
- Implant diameter
- Implant system
- Type of prosthesis
- Healing period
- SR
- Data analyses and statistics

The method used for meta-analysis in this article was previously reported by another systematic review.⁴⁶ The primary outcome was the implant SR. The pooled weighted mean and the 95% confidence interval (CI) of each technique were estimated using a computer program (Comprehensive Meta-analysis Version 2, Biostat). Random-effects meta-analyses of the selected studies were applied to minimize potential bias caused by methodologic differences among studies. Forest plots were produced to graphically represent weighted mean and 95% CI for primary outcomes in the studies included. The number of implants placed was used as the analysis unit for primary outcome. In addition, heterogeneity among studies was assessed with the chi-square test, with a value of $P < .05$

Table 1 The Systematic Search Strategy Used in the Current Review

Focus question: Grafting the edentulous maxilla

Search strategy	Population: Patients with completely edentulous maxilla Intervention or exposure: Vertical ridge augmentation, horizontal ridge augmentation, sinus augmentation; implants; grafting materials Comparison: Grafting techniques; implant survival vs none Outcome: Survival rate Filters(language): English
Database search	Electronic: PubMed (English) Hand searched: Clinical Oral Implant Research and International Journal of Oral and Maxillofacial Implants
Selection criteria	Inclusion criteria 10 patients Implants placed with 12 months of follow-up Human studies only English language Exclusion criteria Animal studies < 10 patients < 12 months of follow-up

representing significant heterogeneity. The reporting of these meta-analyses adhered to the Preferred Reporting Items for Systematic Review and Meta-Analyses (PRISMA) statement.⁴⁷

RESULTS

Of the 89 studies evaluated based on titles and abstracts, 44 were excluded because of lack of 12-month follow-up, lack of reporting of implant SRs, inclusion of a large number of partially edentulous patients, or duplicate patients from previous studies (Fig 1). After full-text screening, another five studies were further excluded for data extraction and meta-analysis because of insufficient data reported. When evaluating the level of evidence for articles included, most were retrospective case series, or level II-3 studies without a concurrent or historical control group.⁴⁸ Many of these studies, however, had large numbers of patients, collected clinically relevant information, and reported patient-centered outcomes. Some studies also included control or nongrafting groups, conducted split-mouth studies, or randomized treatment allocation (Fig 2).

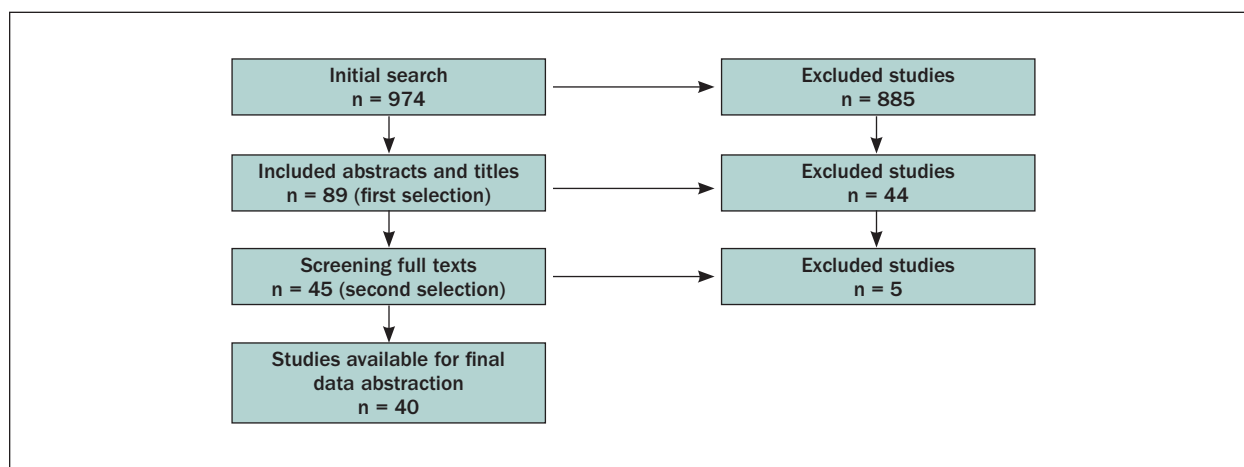


Fig 1 Flow chart showing the selection process of the current review.

Much importance has been placed on validating current therapies, especially with regard to implant dentistry. An increasing number of studies are now available to evaluate grafting success rate as well as implant survival. This is demonstrated in the distribution of studies from 1990 to the present (Fig 3). The number of studies has been increasing overall, especially those with very long-term follow-up. A detailed examination of the articles included revealed that few studies included patients with sinus augmentation as the only grafting technique. Most of the completely edentulous patients requiring sinus grafting also had severe anterior maxillary atrophy, which required either an onlay graft or a nasal floor (or inlay) graft. This is not surprising, because the length of time for which the patients were edentulous in these studies was often greater than 10 to 20 years. A combination of techniques was by far the most common, such as Le Fort I interpositional grafts that were combined with onlay grafts, or buccal guided bone regeneration (GBR) that was combined with sinus augmentation or nasal inlay grafts (Fig 4).

Onlay Bone Grafting

Scientific evidence for onlay bone grafting of the completely edentulous maxilla was provided by 16 (12 retrospective, 3 prospective, and 1 concurrent controlled) studies.^{3,8,13,14,36,38,49–59} These clinical studies included data from 515 patients in which 2,446 implants were placed. The follow-up period ranged from 1 to 12 years. The studies were heterogeneous in nature including various graft donor sites, simultaneous and staged implant placement, machine and textured implant surface types, and prosthetic designs. The majority of maxillae were reconstructed with iliac bone grafts but cranial and rib grafts were also used. The reported SRs of implants in maxillary onlay bone grafts ranged from 73.3% to 100%. Lower implant survival was associated with a machined implant surface (73.3%–91%) or simultaneous

graft-implant placement (73.8%–91%) compared with a staged approach (85.7%–100%) or textured surface implants (88.9%–100%). The prosthesis stability ranged from 75% to 100%. The marginal bone levels around the implants ranged from 1.49 to 4.80 mm.^{3,13,36,49,51,52} Greater bone loss was associated with simultaneous implant placement and long conical neck machined implants.

Of the 16 studies included, which used the onlay bone augmentation technique for ridge augmentation, the weighted mean SR was 85.2% (95% confidence interval [CI] = 80.8%–88.8%, Fig 5). The *P* value was .01 with the chi-square test, which represented a moderate to high heterogeneity among studies.

GBR

Only two studies included scientific evidence for GBR. One study⁶⁰ included 14 patients with 75 implants. After 1 year of loading, an SR of 100% was seen in all groups (no graft, autogenous bone with anorganic bovine bone, or autogenous bone with bone ceramic). The other study¹⁴ was a retrospective one including 26 patients with 5-year follow-up data, which compared iliac crest bone graft with demineralized freeze-dried bone allograft. The SR in iliac crest bone grafts was 96.1% compared with a 98.7% SR in demineralized freeze-dried bone allografts, with the differences between the two graft materials not significant.

These two studies that used the GBR technique were not included in the meta-analysis because their limited number precluded a meaningful meta-analysis.

Le Fort I Interpositional Grafting

Scientific evidence for Le Fort I interpositional grafting was included in 11 studies (seven retrospective case series, three prospective case series, and one prospective concurrent controlled study). These clinical studies included data from 250 patients with edentulous maxillae. Here, 1,588 implants with a follow-up of 1

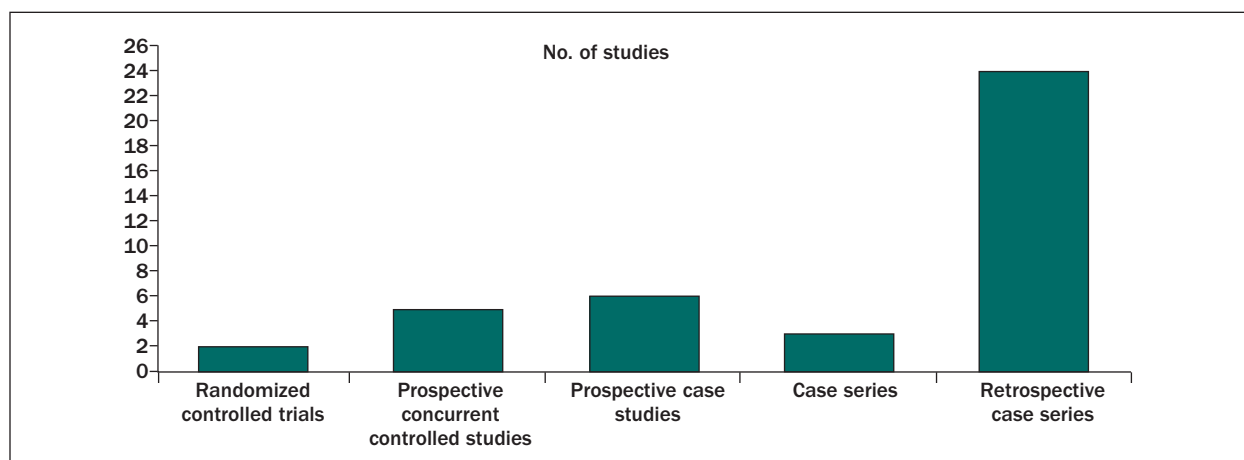


Fig 2 Bar chart representing the design of the studies included.

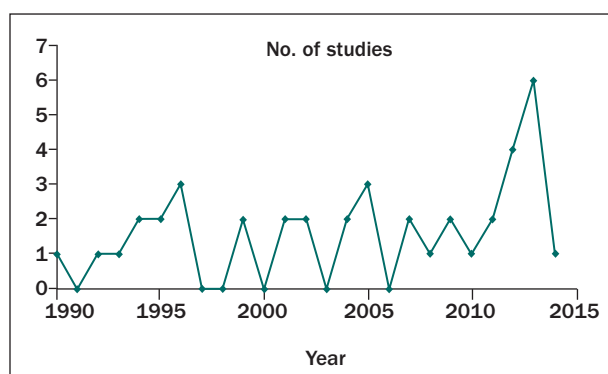


Fig 3 Line chart representing the year of publication of the studies included.

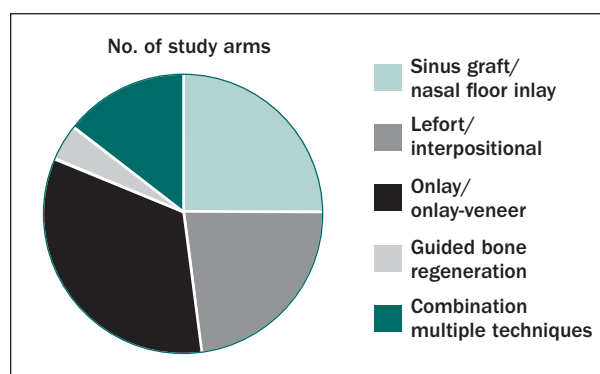


Fig 4 Circle chart representing the techniques studied in the current review.

to 12 years demonstrated an SR between 68.3% and 96.6%.^{5-7,10,13,26,37,61-66} One study reported that greater implant failure rate was associated with shorter implant length.³⁷ Three studies compared the implant SR between the Le Fort I grafting technique and combination (onlay and sinus augmentation) technique, of which two studies^{7,66} reported a higher implant SR for the combination technique. The prosthesis stability ranged from 75% to 100%. The marginal bone levels around the implants ranged from 0.3 to 3.1 mm.^{5,10,61,64,65}

For studies using the Le Fort I interpositional grafting technique for ridge augmentation, the weighted mean SR was 89.6% (95% CI = 85.5%–92.7%; Fig 6). $P = .24$ with the chi-square test, which represented a low heterogeneity among studies.

Sinus Augmentation/Nasal Floor Inlay Grafting

Scientific evidence for sinus augmentation^{18,31,43,56,67-71}/nasal floor inlay grafting^{50,54,72} was provided by 12 studies. These clinical studies included data from 561 patients with edentulous maxillae with 4,860 implants. The follow-up period ranged from 1 to 11.5 years, and the implant SR ranged from 75.2% to 99.1%. The marginal bone level changes around the implants ranged from 0.43 to

4.2 mm.^{43,67,69,71} Two studies compared implants placed in grafted vs nongrafted bone.^{18,43} Of these two studies, Pieri et al⁴³ reported that grafted (posterior) vs native bone (anterior) comparisons showed 98.7% survival and success at 1 year (97.7% test and 100% control implants). Johansson et al¹⁸ reported a cumulative implant success rate of 75.3% in grafted areas and 82.2% in nongrafted sites. Rickert et al⁷¹ compared anorganic bovine bone with either bone marrow aspirate or autogenous bone and reported an implant SR of 91% vs 100%, respectively.⁷¹ Another comparative study with anorganic bovine bone vs native bone demonstrated a 98.7% survival in the posterior maxilla (graft) compared with a 100% survival in the anterior maxilla (native bone).³¹ Zinser et al⁷⁰ performed a regression analysis and summarized that significant implant failure predictors include the graft material used, residual crestal bone height, American Society of Anesthesiologists class, surgical technique, implant proximity, smoking, and age.

For the 12 studies using sinus augmentation and/or nasal floor inlay grafting techniques, the weighted mean SR was 91.5% (95% CI = 86.4%–94.8%; Fig 7). $P = .43$ with the chi-square test, which represented a low heterogeneity among studies.

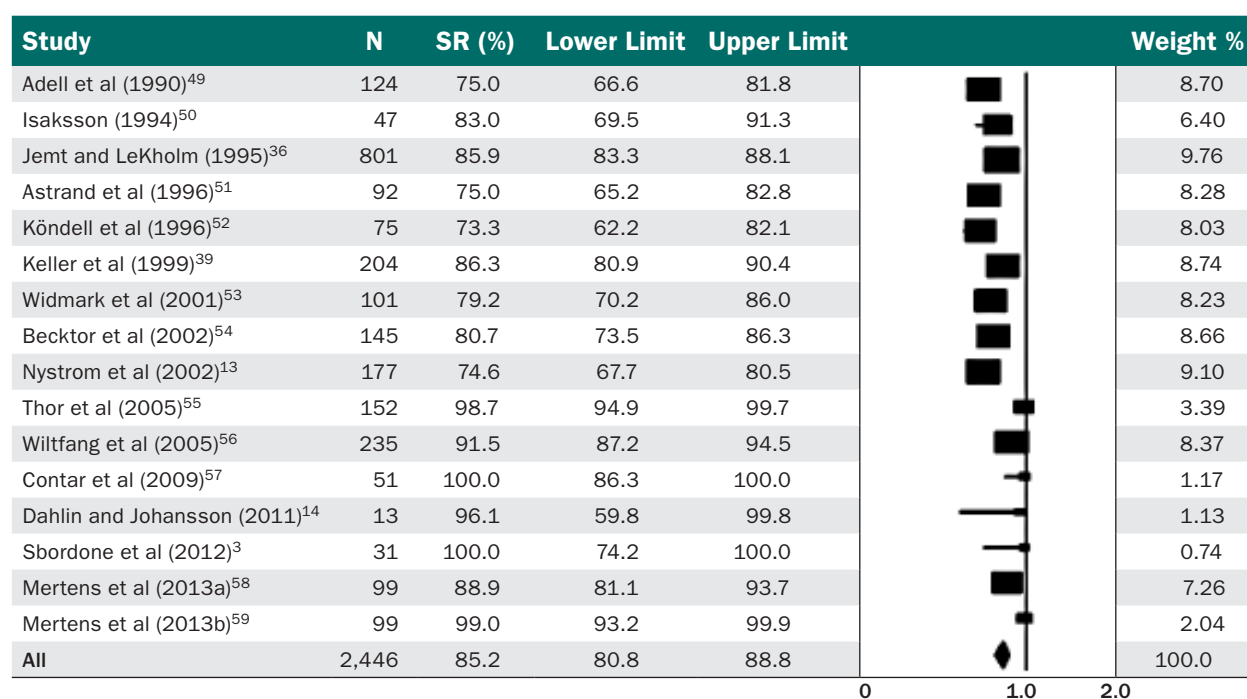


Fig 5 Forest plot representing the weighted mean SR of 85.2% (95% CI = 80.8%–88.8%) for the onlay bone grafting technique.

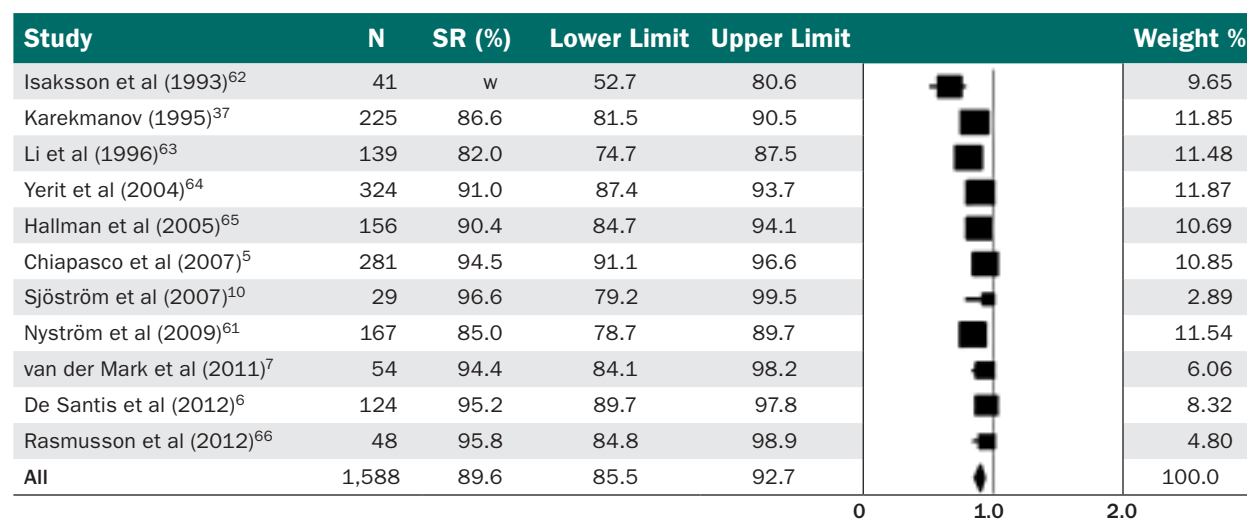


Fig 6 Forest plot representing the weighted mean SR of 89.6% (95% CI = 85.5%–92.7%) for Le Fort I interpositional grafting.

Combination Grafting

Scientific evidence for onlay-sinus graft or GBR-sinus graft was provided by six studies (three retrospective case series, two case series, and one prospective concurrent controlled study). These clinical studies included data from 166 patients who had edentulous maxillae with 963 implants and had follow-up periods of 19 to 72 months.

The reported implant SRs in the six studies ranged from 75.1% to 100%. One study reported⁸ that implant SR in the grafted sites was 75.1% compared with 84% in nongrafts. Higher failure of implants was seen after onlay grafting (37%) compared with inlay grafting (24.9%), with a marginal bone loss of 3.3 mm in grafted bone

vs 2.9 mm in native bone.⁸ Another study⁶⁶ included three study groups that received the Le Fort I technique, onlay bone grafting in combination with sinus augmentation, and GBR in combination with sinus augmentation, and reported implant SRs of 95.8%, 94.7%, and 100%, respectively.

The meta-analysis of SR excluded the study group that received GBR in combination with sinus augmentation⁶⁶ because of the different study designs. The weighted mean SR was 93.6% (95% CI = 84.6%–97.5%; Fig 8). $P = .26$ with the chi-square test, which represented low heterogeneity among studies.

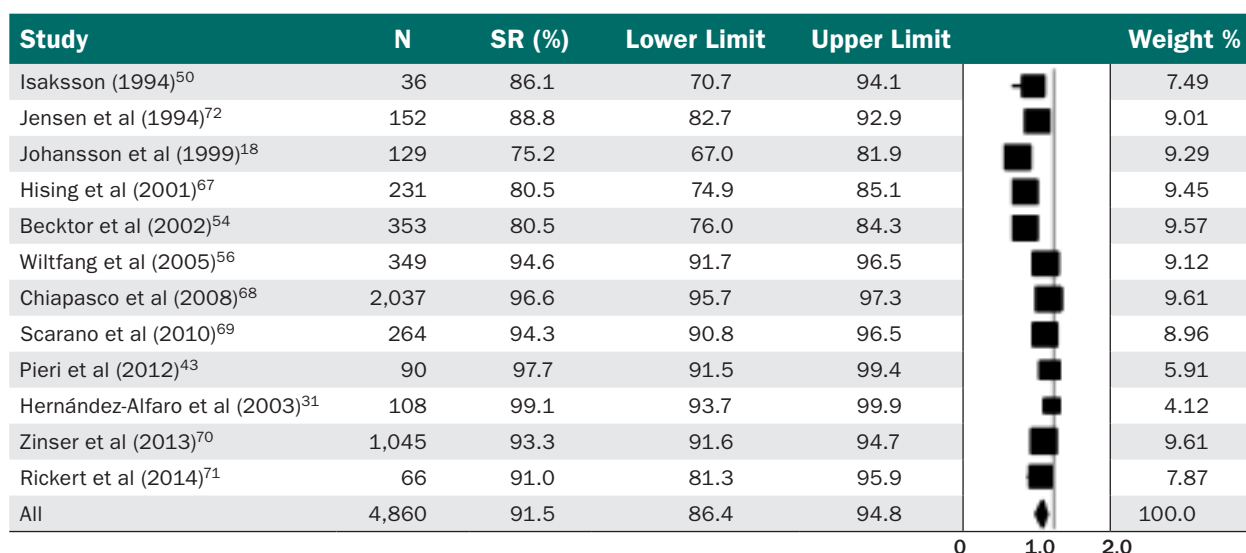


Fig 7 Forest plot representing the weighted mean SR of 91.5% (95% CI = 86.4%–94.8%) for sinus augmentation and/or nasal floor inlay grafting.

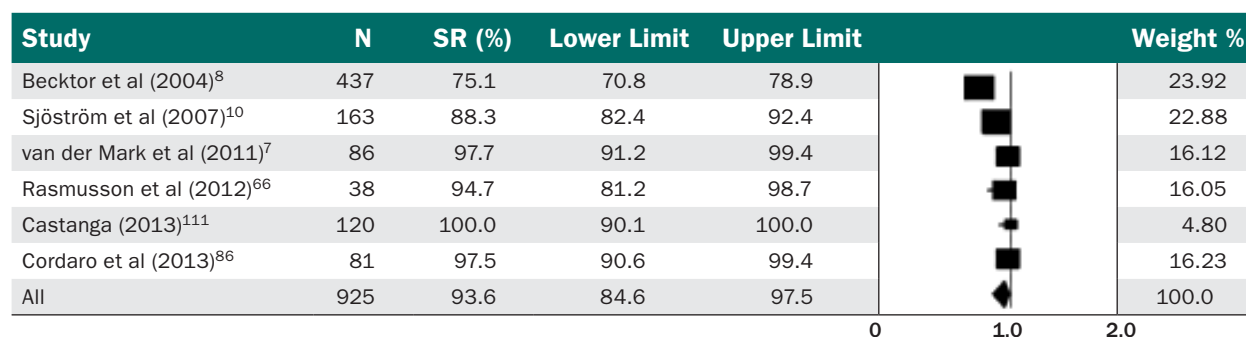


Fig 8 Forest plot representing the weighted mean SR of 93.6% (95% CI = 84.6%–97.5%) for the combination technique.

DISCUSSION

Systematic reviews carry the highest level of evidence to evaluate specific treatment protocols, and serve to make sense of a large body of literature.⁴⁸ In this review, implant survival was evaluated after bone grafting procedures were performed in edentulous maxillae for implant site development. Although a large body of literature exists, studies were not included if they were case reports, had fewer than 10 patients, or had follow-up periods of less than 1 year after implant loading.

Studies that met the inclusion criteria included those that performed sinus augmentation, onlay bone grafting, GBR, nasal floor grafting and Le Fort I interpositional grafting procedures. Most studies reported implant SRs comparable to those seen when bone grafting was not performed. Although dental implant survival was used in this systematic review to determine bone augmentation success, this evaluation

criterion has several limitations. Implant failure can occur independent of augmentation success. Often the baseline situation of the patient (degree of atrophy, bone quality) is not identified in the study. As such, patients who require more complex augmentation techniques (severe atrophy) may have implant SRs that are lower than less demanding procedures. If the result of the augmentation is compromised, the implant size may have been modified to accommodate the conditions, unknown to the reader. If the graft failed, then no implants would have been placed. If the implant surface is not identified (eg, machined), a lower implant SR may be interpreted as having low augmentation success. In addition, implant survival may be a function of the residual native bone supporting the implant rather than the grafted bone.⁷³ Although there are disadvantages in relying on implant survival to measure augmentation success, this is one of the few parameters that gets consistently reported to allow comparison between studies.

Additional information determined from many studies included implant success, graft resorption, prosthetic success, marginal bone measurements, mean bone gain or loss after grafting, implant stability, patient satisfaction, cost analysis, surgical complications, medical risk factors, and peri-implant parameters such as bleeding, plaque index, and pocket depths. A large amount of data was obtained and analyzed, but few studies directly compared specific treatment protocols or grafting techniques, or had control groups. This makes it difficult to generalize to large patient populations or draw definitive conclusions.

It is well accepted that survival is higher when implants are placed in native bone.^{8,17,43,74–76} However, when inadequate bone does not allow implants to be placed in the proper prosthetic position or even to be placed at all, it is unclear whether implant survival in those cases will be similar to implants placed in grafted bone. Even in cases with enough bone for implant placement, GBR may be performed on the buccal side of the ridge to augment a thin cortex or implant dehiscences or to improve esthetic outcomes.^{43,60} A dehiscence or thin buccal plate can lead to bone resorption and soft tissue recession.⁴³

The most predictable and well-documented bone grafting technique is maxillary sinus augmentation.^{22–24,73} In the edentulous maxilla, pneumatization of the maxillary sinuses is common. In these cases, sinus augmentation can be performed alone or in combination with anterior grafting procedures such as onlay grafting and nasal floor augmentation.^{8,37,67,71,77–79} Implant SRs in edentulous maxillae after sinus grafting are high, regardless of whether autogenous bone is used alone, in combination with xenograft, or xenograft alone.^{9,67,71,77} This approach avoids the significant posterior cantilever of tilted anterior implants, the technical difficulties and complications of zygomatic and pterygoid implants, and the concern for lack of long-term data for both procedures.^{28–30,53,80–82}

Maxillary sinus grafting and horizontal bone augmentation are predictable techniques associated with high implant SRs. Vertical ridge augmentation poses greater challenges. Although there are several methods for vertical augmentation, this review only investigated onlay bone grafting and interpositional grafts. Surgical complexity, donor site morbidity, graft stability under denture loading, graft resorption, and the degree of long-term fixation of implants in residual native bone are factors that need to be considered.^{1,3,52} The use of a denture during onlay graft healing can cause wound dehiscence, graft displacement, graft resorption, and implant failure. Minimal use of the denture and a soft diet is encouraged until the graft becomes incorporated after 4 months. Higher implant failure has been observed when the edentulous maxilla is grafted against opposing natural dentition.⁷⁹

Several factors may affect the amount of graft resorption during healing. Autogenous bone graft remodeling is necessary for incorporation to the osseous recipient site. Bone grafts inserted between osteotomized segments (interpositional grafts) resorb less than onlay grafts placed outside the bone contour.⁸³ Vertical bone grafts are more technically demanding and subject to greater volume loss than horizontal augmentations.⁸⁴ The osseous microarchitecture of the graft will also influence graft healing. Denser cortical grafts, from the calvarium or mandible, tend to resorb less than those containing a greater cancellous component, such as the iliac crest.^{58,85,86} When using iliac bone, it may be prudent to overbuild the reconstructed ridge in anticipation of volume loss on healing. Reconstruction of the atrophic maxilla is usually staged with implant placement after graft healing to allow for remodeling. Enough time should elapse for graft incorporation, but implants should be inserted early enough to stimulate and maintain the regenerated bone.⁸⁷ Most studies report that the majority of the resorption occurs within the first year and is low thereafter.^{85,88–90} Although the degree of iliac bone resorption can be variable and in some cases significant, it does not appear to be detrimental to long-term dental implant survival.^{1,3,88,89,91} Several studies document minimal marginal bone loss after implant placement and loading in grafted sites.^{53,92} This may be a factor of implant surface and/or design.^{91,93}

The use of a barrier membrane, titanium mesh, or slow resorbing bone substitute has been suggested to protect onlay bone grafts from resorption. Although some studies have found that membranes have a positive influence on graft healing, others dispute their significance.^{94,95} Titanium mesh maintains space but is usually used with particulate cancellous bone for ridge augmentation.⁹⁶ Bovine hydroxyapatite has been found to reduce graft loss when placed over and around autograft blocks.⁹⁷ As previously discussed, it is also important to limit graft loading by the upper complete or partial denture during graft healing.

Vertical augmentation continues to be one of the most challenging problems in implant dentistry today. Therefore alternative therapies continue to be investigated to avoid classic onlay grafting, such as distraction osteogenesis, interpositional graft, and growth factors with titanium mesh or other rigid scaffolds. Several studies on maxillary onlay autogenous bone grafts report lower implant SRs. Several variables can account for this finding. The most significant is the use of machined surface dental implants. During the developmental and early routine periods of reconstructing the severely atrophic maxilla, machined surface implants (Brånemark) were used with iliac bone grafts.^{25,36} The lower survival of machined surface implants in the

maxilla and poorer quality bone is well documented.^{19,36,98} The use of textured surface implants in onlay bone grafts can provide implant SRs similar to those seen in native bone.⁹⁹ Along with implant survival, crestal bone resorption also varies in machined vs enhanced implant surfaces. Studies show large variability, ranging from 0.04 to 2.7 mm with different implant macro- and microdesigns.^{9,100,101} Most crestal bone loss occurs within the first year of function, and may be lower with rough surface implants.^{98,102}

Simultaneous placement of dental implants in maxillary block autografts also has a much lower SR than staged insertion after graft healing (79.3% vs 93.4%).¹⁰³ This approach was used initially in an attempt to fix the bone graft, decrease the number of surgeries, and shorten treatment length. A staged technique is preferred, allowing the bone graft to remodel and incorporate before implant insertion. The type of bone graft and its inherent quality can also influence implant survival. Bone harvested from the iliac crest has a thin outer cortex and a thicker cancellous layer. Bone grafts from the calvarium or mandibular donor sites are mainly cortical and denser. Implant survival in calvarial and mandibular bone grafts is often higher than iliac bone augmentations.^{58,99} Many of the early studies on maxillary reconstruction used machined implants placed simultaneous with iliac bone grafts—a combination of variables that often produced poor results. Contemporary protocols for managing the atrophic maxilla typically involve onlay bone grafting followed by the placement of moderately rough surface implants 4 to 6 months later.

Onlay grafting has been shown to improve implant survival in long-term studies.³⁶ Depending on the skeletal relationship and maxillary resorption pattern, onlay or inlay (interpositional) grafts may be performed.²⁶ Le Fort I interpositional grafting addresses both bone volume and interarch relationship problems that are common in the long-term edentulous patient, but pose significant challenges such as hospitalization, long operating time, general anesthesia, and usually a secondary site for autogenous bone harvest.¹⁰⁴ In addition, implant SRs are often less than ideal, ranging from 81% to 98.5%.^{6,10,36,49,104} These higher SRs may be the result of enhanced implant surfaces.^{6,9,105,106}

Results from the present systematic review demonstrate the challenges in treating the atrophic edentulous maxilla. Bone grafting, including all techniques described herein, is an effective way to provide adequate support for prosthetically driven implant placement. Although studies from almost 30 years ago exist, some with long-term follow-up, it is still difficult to draw definitive conclusions. Several additional surgical procedures did not have adequate publications that fit the inclusion criteria. Bone augmentation may

also be performed with protected bone regeneration using scaffold techniques (ie, titanium mesh grafting), horizontal ridge expansion (splitting), and distraction osteogenesis. One major limitation of this systematic review is the lack of uniform data reporting in published studies. In general, implant SR per implant is reported rather than implant survival per patient. With this method of reporting, each implant is counted individually, whereas each patient should be counted individually. Of course this would significantly decrease the SR, and would make it difficult to compare results with those found in existing literature. However, it would give a more accurate and statistically meaningful representation of implant failure. Moreover, most studies still report implant survival and not success. Just as previous systematic reviews on bone grafting for implant placement have concluded, implant survival that shows the implant to be simply in the mouth is not adequate information for clinicians or patients. Increased demands on marginal bone levels, function, and esthetics, just to mention a few parameters, are generally not included in the literature.⁷³ It is important to go beyond survival to include basic success criteria, such as absence of pain, dysesthesia, paresthesia, subjective complaints, absence of infection with suppuration, absence of implant mobility, absence of continuous radiolucency around the implant, and bone loss of less than 1.5 mm in the first year followed by 0.2 mm per year.^{107,108}

Follow-up data are also extremely important when evaluating the implant literature. Many studies, especially those describing the more recently developed techniques, do not have the same stringent criteria or follow-up time. Because most of the bone graft resorption associated with many grafting techniques occurs during the first 12 to 24 months,^{10,26,79} a 12-month period was chosen as the minimum implant follow-up point. As we delved more into the full texts of the articles included, it was often difficult to decipher which patients and which implants failed in the specific treatment groups. This was especially challenging when studies included both completely and partially edentulous patients. These methodologic issues are well known in the implant literature, and have previously been identified.^{73,109,110} Many studies followed patients for several years and contained important information on long-term implant survival. However, because these implants were placed in the 1980s, 1990s, or early 2000s, machined surface implants were used. Most implants placed today contain enhanced or roughened surfaces, therefore the results may not apply directly to our current practices. This is not surprising, however, because the field of implant dentistry and related technology and procedures are always evolving.

CONCLUSIONS

Within the limitations of this systematic review and analysis, all five treatment modalities discussed here, such as onlay bone grafting, GBR, Le Fort I interpositional grafting, maxillary sinus augmentation, and/or nasal floor inlay grafting or the combination approach can be successfully used to augment edentulous maxillary ridge with high implant SRs.

ACKNOWLEDGMENTS

The authors do not have any financial interests, either directly or indirectly, in the products or information listed in the article. The authors reported no conflicts of interest related to this study.

REFERENCES

1. Dasmah A, Thor A, Ekestubbe A, Sennerby L, Rasmusson L. Particulate vs. block bone grafts: Three-dimensional changes in graft volume after reconstruction of the atrophic maxilla, a 2-year radiographic follow-up. *J Craniomaxillofac Surg* 2012;40:654–659.
2. Acocella A, Bertolai R, Ellis E 3rd, Nissan J, Sacco R. Maxillary alveolar ridge reconstruction with monocortical fresh-frozen bone blocks: A clinical, histological and histomorphometric study. *J Craniomaxillofac Surg* 2012;40:525–533.
3. Sbordone C, Toti P, Guidetti F, et al. Volume changes of iliac crest autogenous bone grafts after vertical and horizontal alveolar ridge augmentation of atrophic maxillas and mandibles: A 6-year computerized tomographic follow-up. *J Oral Maxillofac Surg* 2012;70:2559–2565.
4. Jemt T, Johansson J. Implant treatment in the edentulous maxillae: A 15-year follow-up study on 76 consecutive patients provided with fixed prostheses. *Clin Implant Dent Relat Res* 2006;8:61–69.
5. Chiapasco M, Brusati R, Ronchi P, Le Fort I osteotomy with interpositional bone grafts and delayed oral implants for the rehabilitation of extremely atrophied maxillae: A 1-9-year clinical follow-up study on humans. *Clin Oral Implants Res* 2007;18:74–85.
6. De Santis D, Trevisiol L, D'Agostino A, et al. Guided bone regeneration with autogenous block grafts applied to Le Fort I osteotomy for treatment of severely resorbed maxillae: A 4- to 6-year prospective study. *Clin Oral Implants Res* 2012;23:60–69.
7. van der Mark EL, Bierenbroodspot F, Baas EM, de Lange J. Reconstruction of an atrophic maxilla: Comparison of two methods. *Br J Oral Maxillofac Surg* 2011;49:198–202.
8. Becktor JP, Isaksson S, Sennerby L. Survival analysis of endosseous implants in grafted and nongrafted edentulous maxillae. *Int J Oral Maxillofac Implants* 2004;19:107–115.
9. De Bruyn H, Bouvy P, Collaert B, et al. Long-term clinical, microbiological, and radiographic outcomes of Brånemark implants installed in augmented maxillary bone for fixed full-arch rehabilitation. *Clin Implant Dent Relat Res* 2013;15:73–82.
10. Sjöström M, Sennerby L, Nilson H, Lundgren S. Reconstruction of the atrophic edentulous maxilla with free iliac crest grafts and implants: A 3-year report of a prospective clinical study. *Clin Implant Dent Relat Res* 2007;9:46–59.
11. Tallgren A. The continuing reduction of the residual alveolar ridges in complete denture wearers: A mixed-longitudinal study covering 25 years. *J Prosthet Dent* 1972;27:120–132.
12. Cawood JI, Howell RA. A classification of the edentulous jaws. *Int J Oral Maxillofac Surg* 1988;17:232–236.
13. Nyström E, Ahlqvist J, Legrell PE, Kahnberg KE. Bone graft remodelling and implant success rate in the treatment of the severely resorbed maxilla: A 5-year longitudinal study. *Int J Oral Maxillofac Surg* 2002;31:158–164.
14. Dahlin C, Johansson A. Iliac crest autogenous bone graft versus alloplastic graft and guided bone regeneration in the reconstruction of atrophic maxillae: A 5-year retrospective study on cost-effectiveness and clinical outcome. *Clin Implant Dent Relat Res* 2011;13:305–310.
15. Moy PK, Medina D, Shetty V, Aghaloo TL. Dental implant failure rates and associated risk factors. *Int J Oral Maxillofac Implants* 2005;20:569–577.
16. Jemt T, Book K, Linden B, Urde G. Failures and complications in 92 consecutively inserted overdentures supported by Brånemark implants in severely resorbed edentulous maxillae: A study from prosthetic treatment to first annual check-up. *Int J Oral Maxillofac Implants* 1992;7:162–167.
17. Esposito M, Hirsch JM, Lekholm U, Thomsen P. Biological factors contributing to failures of osseointegrated oral implants. (II). Etiopathogenesis. *Eur J Oral Sci* 1998;106:721–764.
18. Johansson B, Wannfors K, Ekenbäck J, Smedberg JI, Hirsch J. Implants and sinus-inlay bone grafts in a 1-stage procedure on severely atrophied maxillae: Surgical aspects of a 3-year follow-up study. *Int J Oral Maxillofac Implants* 1999;14:811–818.
19. Jaffin RA, Berman CL. The excessive loss of Brånemark fixtures in type IV bone: A 5-year analysis. *J Periodontol* 1991;62:2–4.
20. Cawood JI, Howell RA. Reconstructive preprosthetic surgery. I. Anatomical considerations. *Int J Oral Maxillofac Surg* 1991;20:75–82.
21. Yamamichi N, Itose T, Neiva R, Wang HL. Long-term evaluation of implant survival in augmented sinuses: A case series. *Int J Periodontics Restorative Dent* 2008;28:163–169.
22. Jensen OT, Shulman LB, Block MS, Iacono VJ. Report of the Sinus Consensus Conference of 1996. *Int J Oral Maxillofac Implants* 1998;13 Suppl:11–45.
23. Wallace SS, Froum SJ. Effect of maxillary sinus augmentation on the survival of endosseous dental implants. A systematic review. *Ann Periodontol* 2003;8:328–343.
24. Del Fabbro M, Testori T, Francetti L, Weinstein R. Systematic review of survival rates for implants placed in the grafted maxillary sinus. *Int J Periodontics Restorative Dent* 2004;24:565–577.
25. Nyström E, Kahnberg KE, Gunne J. Bone grafts and Brånemark implants in the treatment of the severely resorbed maxilla: A 2-year longitudinal study. *Int J Oral Maxillofac Implants* 1993;8:45–53.
26. Nyström E, Nilson H, Gunne J, Lundgren S. A 9–14 year follow-up of onlay bone grafting in the atrophic maxilla. *Int J Oral Maxillofac Surg* 2009;38:111–116.
27. Cricchio G, Lundgren S. Donor site morbidity in two different approaches to anterior iliac crest bone harvesting. *Clin Implant Dent Relat Res* 2003;5:161–169.
28. Shackleton JL, Carr L, Slabbert JC, Becker PJ. Survival of fixed implant-supported prostheses related to cantilever lengths. *J Prosthet Dent* 1994;71:23–26.
29. Rosén A, Gynther G. Implant treatment without bone grafting in edentulous severely resorbed maxillas: A long-term follow-up study. *J Oral Maxillofac Surg* 2007;65:1010–1016.
30. Maló P, Rangert B, Nobre M. All-on-4 immediate-function concept with Brånemark System implants for completely edentulous maxillae: A 1-year retrospective clinical study. *Clin Implant Dent Relat Res* 2005;7 Suppl 1:S88–S94.
31. Hernández-Alfaro F, Sancho-Puchades M, Guijarro-Martínez R. Total reconstruction of the atrophic maxilla with intraoral bone grafts and biomaterials: A prospective clinical study with cone beam computed tomography validation. *Int J Oral Maxillofac Implants* 2013;28:241–251.
32. Chrcanovic BR, Abreu MH. Survival and complications of zygomatic implants: A systematic review. *Oral Maxillofac Surg* 2013;17:81–93.
33. Monje A, Chan HL, Fu JH, et al. Are short dental implants (<10 mm) effective? A meta-analysis on prospective clinical trials. *J Periodontol* 2013;84:895–904.
34. Monje A, Fu JH, Chan HL, et al. Do implant length and width matter for short dental implants (<10 mm)? A meta-analysis of prospective studies. *J Periodontol* 2013;84:1783–1791.

35. Herrmann I, Lekholm U, Holm S, Kultje C. Evaluation of patient and implant characteristics as potential prognostic factors for oral implant failures. *Int J Oral Maxillofac Implants* 2005;20:220–230.
36. Jemt T, Lekholm U. Implant treatment in edentulous maxillae: A 5-year follow-up report on patients with different degrees of jaw resorption. *Int J Oral Maxillofac Implants* 1995;10:303–311.
37. Krekmanov L. A modified method of simultaneous bone grafting and placement of endosseous implants in the severely atrophic maxilla. *Int J Oral Maxillofac Implants* 1995;10:682–688.
38. Keller EE, Tolman DE, Eckert S. Surgical-prosthetic reconstruction of advanced maxillary bone compromise with autogenous onlay block bone grafts and osseointegrated endosseous implants: A 12-year study of 32 consecutive patients. *Int J Oral Maxillofac Implants* 1999;14:197–209.
39. Keller EE, Tolman DE, Eckert SE. Maxillary antral-nasal inlay autogenous bone graft reconstruction of compromised maxilla: A 12-year retrospective study. *Int J Oral Maxillofac Implants* 1999;14:707–721.
40. Sennerby L, Roos J. Surgical determinants of clinical success of osseointegrated oral implants: A review of the literature. *Int J Prosthodont* 1998;11:408–420.
41. Arisan V, Bölükbaşı N, Ersanli S, Ozdemir T. Evaluation of 316 narrow diameter implants followed for 5–10 years: A clinical and radiographic retrospective study. *Clin Oral Implants Res* 2010;21:296–307.
42. Neldam CA, Pinholt EM. State of the art of short dental implants: A systematic review of the literature. *Clin Implant Dent Relat Res* 2012;14:622–632.
43. Pieri F, Aldini NN, Fini M, Marchetti C, Corinaldesi G. Immediate fixed implant rehabilitation of the atrophic edentulous maxilla after bilateral sinus floor augmentation: A 12-month pilot study. *Clin Implant Dent Relat Res* 2012;14 Suppl 1:e67–e82.
44. Renouard F, Nisand D. Short implants in the severely resorbed maxilla: A 2-year retrospective clinical study. *Clin Implant Dent Relat Res* 2005;7 Suppl 1:S104–S110.
45. Corrente G, Abundo R, des Ambrois AB, Savio L, Perelli M. Short porous implants in the posterior maxilla: A 3-year report of a prospective study. *Int J Periodontics Restorative Dent* 2009;29:23–29.
46. Khoshkam V, Chan HL, Lin GH, et al. Reconstructive procedures for treating peri-implantitis: A systematic review. *J Dent Res* 2013;92:1315–1385.
47. Liberati A, Altman DG, Tetzlaff J, et al. The PRISMA statement for reporting systematic reviews and meta-analyses of studies that evaluate health care interventions: Explanation and elaboration. *J Clin Epidemiol* 2009;151:W65–W94.
48. Grimes DA, Schulz KF. An overview of clinical research: The lay of the land. *Lancet* 2002;359:57–61.
49. Adell R, Lekholm U, Gröndahl K, et al. Reconstruction of severely resorbed edentulous maxillae using osseointegrated fixtures in immediate autogenous bone grafts. *Int J Oral Maxillofac Implants* 1990;5:233–246.
50. Isaksson S. Evaluation of three bone grafting techniques for severely resorbed maxillae in conjunction with immediate endosseous implants. *Int J Oral Maxillofac Implants* 1994;9:679–688.
51. Astrand P, Nord PG, Brånemark PI. Titanium implants and onlay bone graft to the atrophic edentulous maxilla: A 3-year longitudinal study. *Int J Oral Maxillofac Surg* 1996;25:25–29.
52. Köndell PA, Nordenram A, Moberg LE, Eliasson S, Nyberg B. Reconstruction of the resorbed edentulous maxilla using autogenous rib grafts and osseointegrated implants. *Clin Oral Implants Res* 1996;7:286–290.
53. Widmark G, Andersson B, Carlsson GE, Lindvall AM, Ivanoff CJ. Rehabilitation of patients with severely resorbed maxillae by means of implants with or without bone grafts: A 3- to 5-year follow-up clinical report. *Int J Oral Maxillofac Implants* 2001;16:73–79.
54. Becktor JP, Eckert SE, Isaksson S, Keller EE. The influence of mandibular dentition on implant failures in bone-grafted edentulous maxillae. *Int J Oral Maxillofac Implants* 2002;17:69–77.
55. Thor A, Wannfors K, Sennerby L, Rasmusson L. Reconstruction of the severely resorbed maxilla with autogenous bone, platelet-rich plasma, and implants: 1-year results of a controlled prospective 5-year study. *Clin Implant Dent Relat Res* 2005;7:209–220.
56. Wiltfang J, Schultze-Mosgau S, Nkenke E, et al. Onlay augmentation versus sinuslift procedure in the treatment of the severely resorbed maxilla: A 5-year comparative longitudinal study. *Int J Oral Maxillofac Surg* 2005;34:885–889.
57. Contar CM, Sarot JR, Bordini J Jr, et al. Maxillary ridge augmentation with fresh-frozen bone allografts. *J Oral Maxillofac Surg* 2009;67:1280–1285.
58. Mertens C, Decker C, Seeberger R, et al. Early bone resorption after vertical bone augmentation—a comparison of calvarial and iliac grafts. *Clin Oral Implants Res* 2013;24:820–825.
59. Mertens C, Steveling HG, Seeberger R, Hoffmann J, Freier K. Reconstruction of severely atrophied alveolar ridges with calvarial onlay bone grafts and dental implants. *Clin Implant Dent Relat Res* 2013;15:673–683.
60. Van Assche N, Michels S, Naert I, Quirynen M. Randomized controlled trial to compare two bone substitutes in the treatment of bony dehiscences. *Clin Implant Dent Relat Res* 2013;15:558–568.
61. Nyström E, Nilson H, Gunne J, Lundgren S. Reconstruction of the atrophic maxilla with interpositional bone grafting/Le Fort I osteotomy and endosteal implants: A 11–16 year follow-up. *Int J Oral Maxillofac Surg* 2009;38:1–6.
62. Isaksson S, Ekfeldt A, Alberius P, Blomqvist JE. Early results from reconstruction of severely atrophic (Class VI) maxillas by immediate endosseous implants in conjunction with bone grafting and Le Fort I osteotomy. *Int J Oral Maxillofac Surg* 1993;22:144–148.
63. Li KK, Stephens WL, Gliklich R. Reconstruction of the severely atrophic edentulous maxilla using Le Fort I osteotomy with simultaneous bone graft and implant placement. *J Oral Maxillofac Surg* 1996;54:542–546; discussion 547.
64. Yorit KC, Posch M, Hainich S, et al. Long-term implant survival in the grafted maxilla: Results of a 12-year retrospective study. *Clin Oral Implants Res* 2004;15:693–699.
65. Hallman M, Mordenfeld A, Strandkvist T. A retrospective 5-year follow-up study of two different titanium implant surfaces used after interpositional bone grafting for reconstruction of the atrophic edentulous maxilla. *Clin Implant Dent Relat Res* 2005;7:121–126.
66. Rasmusson L, Thor A, Sennerby L. Stability evaluation of implants integrated in grafted and nongrafted maxillary bone: A clinical study from implant placement to abutment connection. *Clin Implant Dent Relat Res* 2012;14:61–66.
67. Hising P, Bolin A, Branting C. Reconstruction of severely resorbed alveolar ridge crests with dental implants using a bovine bone mineral for augmentation. *Int J Oral Maxillofac Implants* 2001;16:90–97.
68. Chiapasco M, Zaniboni M, Rimondini L. Dental implants placed in grafted maxillary sinuses: A retrospective analysis of clinical outcome according to the initial clinical situation and a proposal of defect classification. *Clin Oral Implants Res* 2008;19:416–428.
69. Scarano A, Piattelli A, Assenza B, et al. Porcine bone used in sinus augmentation procedures: A 5-year retrospective clinical evaluation. *J Oral Maxillofac Surg* 2010;68:1869–1873.
70. Zinser MJ, Randelzhofer P, Kuiper L, Zöller JE, De Lange GL. The predictors of implant failure after maxillary sinus floor augmentation and reconstruction: A retrospective study of 1045 consecutive implants. *Oral Surg Oral Med Oral Pathol Oral Radiol* 2013;115:571–582.
71. Rickert D, Vissink A, Slot WJ, et al. Maxillary sinus floor elevation surgery with BioOss(R) mixed with a bone marrow concentrate or autogenous bone: Test of principle on implant survival and clinical performance. *Int J Oral Maxillofac Surg* 2014;43:243–247.
72. Jensen J, Sindet-Pedersen S, Oliver AJ. Varying treatment strategies for reconstruction of maxillary atrophy with implants: Results in 98 patients. *J Oral Maxillofac Surg* 1994;52:210–216; discussion 216–218.
73. Aghaloo TL, Moy PK. Which hard tissue augmentation techniques are the most successful in furnishing bony support for implant placement? *Int J Oral Maxillofac Implants* 2007;22 Suppl:49–70.

74. Lekholm U, Wannfors K, Isaksson S, Adielsson B. Oral implants in combination with bone grafts. A 3-year retrospective multicenter study using the Brånemark implant system. *Int J Oral Maxillofac Surg* 1999;28:181–187.
75. Pjetursson BE, Tan K, Lang NP, et al. A systematic review of the survival and complication rates of fixed partial dentures (FPDs) after an observation period of at least 5 years. *Clin Oral Implants Res* 2004;15:625–642.
76. Haas R, Polak C, Fürhauser R, et al. A long-term follow-up of 76 Brånemark single-tooth implants. *Clin Oral Implants Res* 2002;13:38–43.
77. Lorenzoni M, Pertl C, Wegscheider W, et al. Retrospective analysis of Frialit-2 implants in the augmented sinus. *Int J Periodontics Restorative Dent* 2000;20:255–267.
78. Beltrão GC, de Abreu AT, Beltrão RG, Finco NF. Lateral cephalometric radiograph for the planning of maxillary implant reconstruction. *Dentomaxillofac Radiol* 2007;36:45–50.
79. Becktor JP, Rebellato J, Becktor KB, et al. Transverse displacement of the proximal segment after bilateral sagittal osteotomy. *J Oral Maxillofac Surg* 2002;60:395–403.
80. Fernández H, Gómez-Delgado A, Trujillo-Saldarriaga S, Varón-Cardona D, Castro-Núñez J. Zygomatic implants for the management of the severely atrophied maxilla: A retrospective analysis of 244 implants. *J Oral Maxillofac Surg* 2014;72:887–891.
81. Goiato MC, Pellizzer EP, Moreno A, et al. Implants in the zygomatic bone for maxillary prosthetic rehabilitation: A systematic review. *Int J Oral Maxillofac Surg* 2014;43:748–757.
82. Bidra AS, Huynh-Ba G. Implants in the pterygoid region: A systematic review of the literature. *Int J Oral Maxillofac Surg* 2011;40:773–781.
83. Motoki DS, Mulliken JB. The healing of bone and cartilage. *Clin Plast Surg* 1990;17:527–544.
84. Rocchietta I, Fontana F, Simion M. Clinical outcomes of vertical bone augmentation to enable dental implant placement: A systematic review. *J Clin Periodontol* 2008;35:203–215.
85. Carinci F, Farina A, Zanetti U, et al. Alveolar ridge augmentation: A comparative longitudinal study between calvaria and iliac crest bone grafts. *J Oral Implantol* 2005;31:39–45.
86. Cordaro L, Torsello F, Mirisola di Torresanto V, Baricevic M. Rehabilitation of an edentulous atrophic maxilla with four unsplinted narrow diameter titanium-zirconium implants supporting an overdenture. *Quintessence Int* 2013;44:37–43.
87. Nelson K, Ozyuvaci H, Bilgic B, Klein M, Hildebrand D. Histomorphometric evaluation and clinical assessment of endosseous implants in iliac bone grafts with shortened healing periods. *Int J Oral Maxillofac Implants* 2006;21:392–398.
88. Schmitt CM, Moest T, Lutz R, Neukam FW, Schlegel KA. Anorganic bovine bone (ABB) vs. autologous bone (AB) plus ABB in maxillary sinus grafting. A prospective non-randomized clinical and histomorphometrical trial. *Clin Oral Implants Res* 2014. (epub ahead of print).
89. Reinert S, König S, Bremerich A, Eufinger H, Krimmel M. Stability of bone grafting and placement of implants in the severely atrophic maxilla. *Br J Oral Maxillofac Surg* 2003;41:249–255.
90. Johansson B, Grepe A, Wannfors K, Hirsch JM. A clinical study of changes in the volume of bone grafts in the atrophic maxilla. *Dentomaxillofac Radiol* 2001;30:157–161.
91. Nyström E, Ahlqvist J, Gunne J, Kahnberg KE. 10-year follow-up of onlay bone grafts and implants in severely resorbed maxillae. *Int J Oral Maxillofac Surg* 2004;33:258–262.
92. Barone A, Toti P, Quaranta A, Derchi G, Covani U. The Clinical Outcomes of Immediate Versus Delayed Restoration Procedures on Immediate Implants: A Comparative Cohort Study for Single-Tooth Replacement. *Clin Implant Dent Relat Res* 2014. (epub ahead of print).
93. Chiapasco M, Casentini P, Zaniboni M. Implants in reconstructed bone: A comparative study on the outcome of Straumann tissue level and bone level implants placed in vertically deficient alveolar ridges treated by means of autogenous onlay bone grafts. *Clin Implant Dent Relat Res* 2014;16:32–50.
94. Gielkens PF, Bos RR, Raghoobar GM, Stegenga B. Is there evidence that barrier membranes prevent bone resorption in autologous bone grafts during the healing period? A systematic review. *Int J Oral Maxillofac Implants* 2007;22:390–398.
95. Heberer S, Ruhe B, Krekeler L, et al. A prospective randomized split-mouth study comparing iliac onlay grafts in atrophied edentulous patients: Covered with periosteum or a bioresorbable membrane. *Clin Oral Implants Res* 2009;20:319–326.
96. Louis PJ, Gutta R, Said-Al-Naief N, Bartolucci AA. Reconstruction of the maxilla and mandible with particulate bone graft and titanium mesh for implant placement. *J Oral Maxillofac Surg* 2008;66:235–245.
97. Cordaro L, Torsello F, Morcavallo S, di Torresanto VM. Effect of bovine bone and collagen membranes on healing of mandibular bone blocks: A prospective randomized controlled study. *Clin Oral Implants Res* 2011;22:1145–1150.
98. Adell R, Lekholm U, Rockler B, Brånemark PI. A 15-year study of osseointegrated implants in the treatment of the edentulous jaw. *Int J Oral Surg* 1981;10:387–416.
99. Chiapasco M, Casentini P, Zaniboni M. Bone augmentation procedures in implant dentistry. *Int J Oral Maxillofac Implants* 2009;24 Suppl:237–259.
100. Blanes RJ, Bernard JP, Blanes ZM, Belser UC. A 10-year prospective study of ITI dental implants placed in the posterior region. I: Clinical and radiographic results. *Clin Oral Implants Res* 2007;18:699–706.
101. Cehreli MC, Karasoy D, Kökat AM, Akça K, Eckert S. A systematic review of marginal bone loss around implants retaining or supporting overdentures. *Int J Oral Maxillofac Implants* 2010;25:266–277.
102. Schwarz F, Herten M, Bieling K, Becker J. Crestal bone changes at nonsubmerged implants (Camlog) with different machined collar lengths: A histomorphometric pilot study in dogs. *Int J Oral Maxillofac Implants* 2008;23:335–342.
103. Chiapasco M, Zaniboni M, Boisco M. Augmentation procedures for the rehabilitation of deficient edentulous ridges with oral implants. *Clin Oral Implants Res* 2006;17 Suppl 2:136–159.
104. Chiapasco M, Zaniboni M, Rimondini L. Autogenous onlay bone grafts vs. alveolar distraction osteogenesis for the correction of vertically deficient edentulous ridges: A 2–4-year prospective study on humans. *Clin Oral Implants Res* 2007;18:432–440.
105. Pinholt EM. Brånemark and ITI dental implants in the human bone-grafted maxilla: A comparative evaluation. *Clin Oral Implants Res* 2003;14:584–592.
106. Cosyn J, Vandenbulcke E, Browaeys H, Van Maele G, De Bruyn H. Factors associated with failure of surface-modified implants up to four years of function. *Clin Implant Dent Relat Res* 2012;14:347–358.
107. Albrektsson T, Zarb G, Worthington P, Eriksson AR. The long-term efficacy of currently used dental implants: A review and proposed criteria of success. *Int J Oral Maxillofac Implants* 1986;1:11–25.
108. Weyant RJ, Burt BA. An assessment of survival rates and within-patient clustering of failures for endosseous oral implants. *J Dent Res* 1993;72:2–8.
109. Coulthard P, Esposito M, Jokstad A, Worthington HV. Interventions for replacing missing teeth: Bone augmentation techniques for dental implant treatment. *Cochrane Database Syst Rev* 2003;CD003607.
110. Esposito M, Coulthard P, Worthington HV, Jokstad A. Quality assessment of randomized controlled trials of oral implants. *Int J Oral Maxillofac Implants* 2001;16:783–792.
111. Castagna L, Polido WD, Soares LG, Tinoco EM. Tomographic evaluation of iliac crest bone grafting and the use of immediate temporary implants to the atrophic maxilla. *Int J Oral Maxillofac Surg* 2013;42:1067–1072.