

CLINICAL REPORT

## Frenectomy with anterior lingual sulcoplasty for an implant-supported overdenture: A clinical report



Paulo Sergio Perri de Carvalho, DDS, PhD,<sup>a</sup> Luiz Antonio Janjacom, DDS,<sup>b</sup> and Daniela Ponzoni, DDS, PhD<sup>c</sup>

After the loss of the mandibular teeth and bone resorption of the alveolar process, the floor of the mouth and the lingual frenulum often become raised to the level of the bone ridge during normal functional movements, especially during speech and swallowing. This situation makes the stabilization of a conventional complete dental prosthesis difficult, because it becomes nearly impossible to provide a lingual flange, and frequent ulceration of the lingual frenulum may occur in osseointegrated implant-retained overdentures.<sup>1,2</sup> Frenectomy and anterior lingual sulcoplasty are indicated for these situations.

Cooley<sup>3</sup> proposed lingual frenectomy and the transposition of the superficial fibers of the genioglossus and geniohyoid muscles to deepen the lingual sulcus. This procedure is often associated with osteoplasty of the mental spine.

### CLINICAL REPORT

A 72-year-old man who was unable to use his overdenture prosthesis because of pain and frequent ulcerations in the anterior mandible region was referred by Oral Rehabilitation Clinic (Araçatuba, São Paulo, Brazil). He presented with 2 osseointegrated implants with abutments in the anterior mandible region and the lingual frenulum close to the crest of the ridge with absence of depth of the anterior lingual sulcus. The insertion position of the lingual musculature was palpated near the crest of the ridge (Fig. 1). Initially, the replacement of the overdenture with a

### ABSTRACT

This clinical report describes the deepening of a patient's anterior mandibular lingual sulcus in combination with frenectomy and the use of an acrylic resin guiding device fixed to an osseointegrated dental implant to maintain the patency of the new sulcular depth. (J Prosthet Dent 2016;115:406-408)

fixed prosthesis was proposed after additional mandibular implant placement. However, this option was declined because the patient's lack of motor coordination might have prevented adequate hygiene of a fixed prosthesis. Thus, frenectomy and anterior lingual sulcoplasty were suggested.

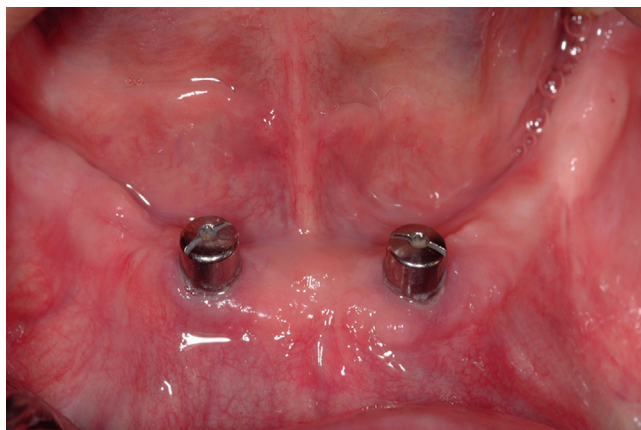
A mandibular impression was made with a polyvinyl siloxane material (Express; 3M ESPE) and an acrylic resin guiding device was designed and fabricated so that it could be retained by the dental implants. The following procedure was performed under local anesthesia. The tongue was extended, and hemostats were placed on the lingual frenulum as determined by the single hemostat frenectomy technique<sup>4</sup> (Fig. 2). After excising the frenulum with a scalpel, a diamond-shaped wound was formed (Fig. 3). Then, only the superior and lateral fibers of the genioglossus and geniohyoid muscles were excised from the mandible. The removed mandibular fibers were sutured directly around the muscle and connecting tissue. The lingual mandible side remained covered by the periosteum; the sublingual region was sutured with simple interrupted stitches.

The acrylic resin guiding device was extended to attain the desired depth, internally coated with a surgical cement (COE-PAK; GC America Inc), and finally stabilized with screws to the 2 implants (Figs. 4, 5). The

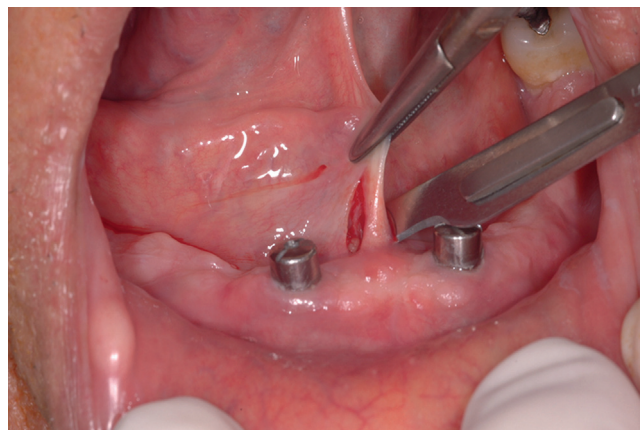
<sup>a</sup>Professor, Bauru School of Dentistry, University of São Paulo (USP), Brazil.

<sup>b</sup>Professor, Specialization Course on Implant Dentistry at NEC Araçatuba School of Dentistry (UNESP), São Paulo, Brazil.

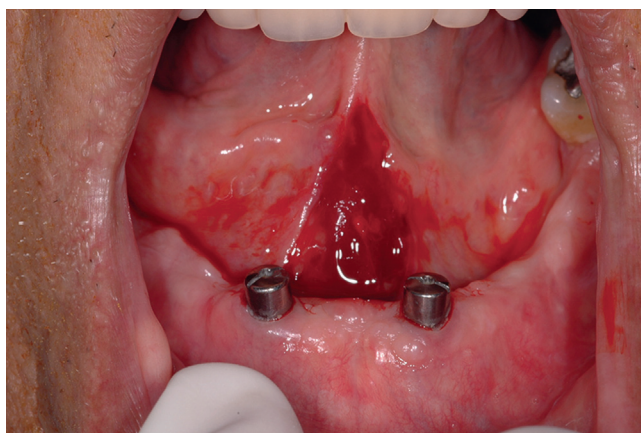
<sup>c</sup>Assistant Professor, Department of Surgery and Integrated Clinic, Araçatuba School of Dentistry (UNESP), São Paulo, Brazil.



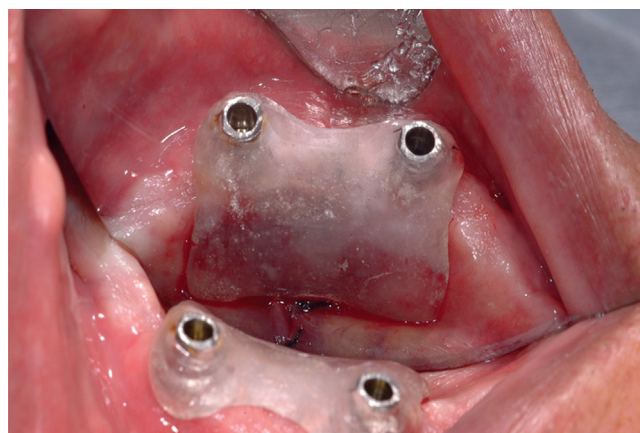
**Figure 1.** Initial clinical presentation: lack of lingual sulcus depth.



**Figure 2.** Single hemostat frenectomy technique.



**Figure 3.** After frenectomy.



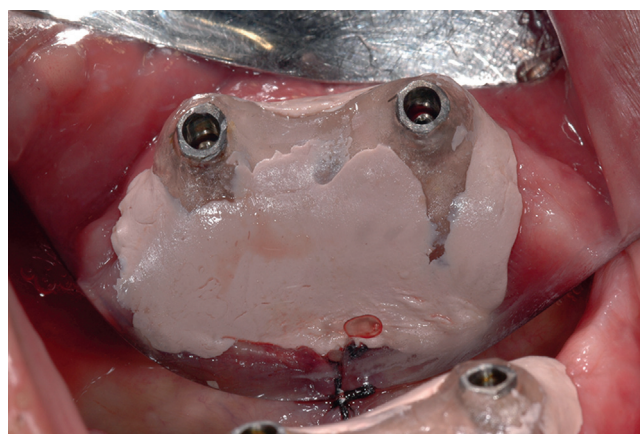
**Figure 4.** Acrylic resin guide positioned and fixed on osseointegrated implants.

surgical guide was unscrewed and removed 5 weeks later. Epithelialization of the lingual surface was observed, and deepening of the lingual sulcus was achieved (Fig. 6). The overdenture prosthesis retained on the 2 osseointegrated implants was installed without the formation of ulcerations on the lingual side of the mandible (Fig. 7).

## DISCUSSION

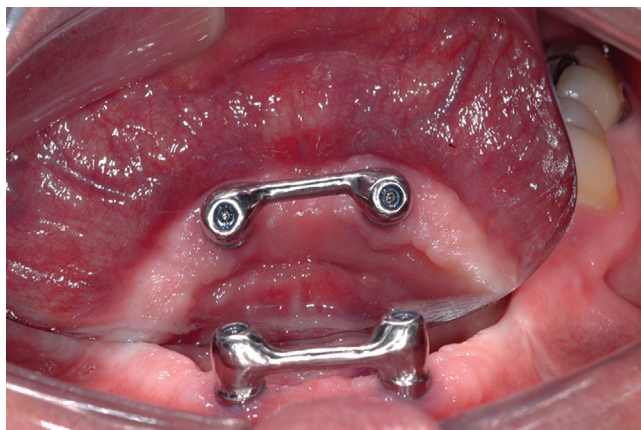
Owing to alveolar process resorption that follows tooth loss, the lingual frenulum and the genioglossus and geniohyoid muscles may become shallow with respect to the ridge crest, making it difficult to stabilize conventional or overdenture-type removable prostheses.<sup>2,3</sup> In this patient, discomfort could have been resolved by substituting the removable system with a fixed prosthesis. However, considering the patient's inability to carry out prosthesis hygiene, he opted for the implant-based removable prosthesis.

On palpation, good positioning of the mental spine was found; this allowed the deepening of the lingual

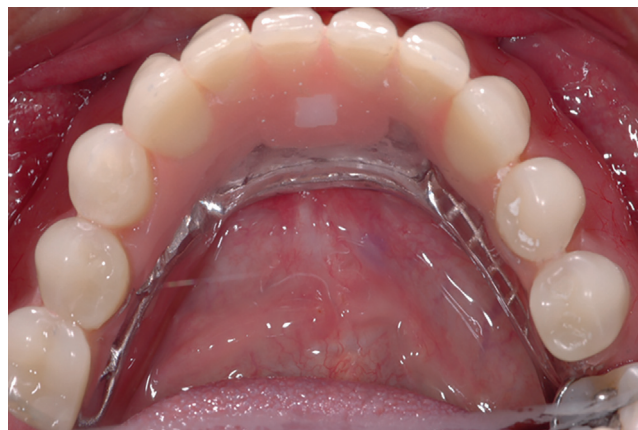

**Figure 5.** Acrylic resin guide positioned with surgical cement.

sulcus by removing a part of the superior and lateral muscle fibers without spine osteoplasty. If all the genioglossus and geniohyoid muscle fibers were removed from the bone, the whole muscle mass would retract posteriorly under the patient's tongue, resulting in



**Figure 6.** Thirty days after procedure.



**Figure 7.** Definitive overdenture prosthesis.

postoperative speech and swallowing problems.<sup>5,6</sup> By screwing the acrylic resin device on to the implants the lingual tissues were preserved in place during scarring, and sutures transfixed on the lingual region of the mandible and anchored to the menton region were unnecessary; moreover, as proposed by Cooley, this technique also avoided the use of steel sutures transfixed on the anterior mandible and twisted on the vestibular side.<sup>1</sup>

This technique increased the patient's comfort during the postoperative phase. The treatment provided stability of and prevented ulcerations on the lingual side of the mandible during the use of the overdenture prosthesis retained on the 2 osseointegrated implants.

## SUMMARY

The technique of deepening the lingual sulcus in the anterior mandibular region is used in patients with atrophy of the alveolar ridge and uplifting of the mouth floor. Both situations make prosthetic rehabilitation difficult. A modified technique can be used with a surgical guide supported by the dental implants during the healing phase. Thus, the procedure becomes straightforward, comfortable, and less traumatic for the patient, enabling adequate prosthetic rehabilitation of the area.

## CONCLUSION

This clinical report described the specific application of a localized anterior mandibular sulcoplasty and lingual frenectomy, together with accompanying surgical-guide stabilization with dental implants to ensure the surgical procedure's efficacy.

## REFERENCES

1. von Wowern N, Hjørtting-Hansen E. The mandibular bone mineral content in relation to vestibulolingual sulcoplasty. A 2-year follow-up. *J Prosthet Dent* 1991;65:804-8.
2. Kwakman JM, Voorsmit RA, Freihofer HP. Treatment of the edentulous mandible with a vestibuloplasty combined with Intramobil Zylinder implants: a 5-year follow-up. *Br J Oral Maxillofac Surg* 1998;36:296-300.
3. Cooley DO. Method for deepening the mandibular and maxillary sulci to correct deficient edentulous ridges. *J Oral Surg* 1952;10:279-89.
4. Archer H. Oral surgery for dental prosthesis. In: *Oral and maxillofacial surgery*. 5th ed. Philadelphia: Saunders; 1975. p. 135-210.
5. Watson CJ. Changes to the lower third facial profile following mandibular sulcoplasty with free skin grafting. *Br J Oral Maxillofac Surg* 1987;25:465-73.
6. Berg RW, Goldman BM, Kurtz K, Schweitzer K, Kraut RA. Prosthodontic management of sulcoplasty and sialodochoplasty with a conforming surgical stent. *J Prosthodont* 2008;17:52-4.

## Corresponding author:

Dr Daniela Ponzoni  
Department of Surgery and Integrated Clinic  
Araçatuba School of Dentistry (UNESP)  
Rua José Bonifácio, 1193 CEP 16015-050  
BRAZIL  
Email: [dponzoni@foa.unesp.br](mailto:dponzoni@foa.unesp.br)

Copyright © 2016 by the Editorial Council for *The Journal of Prosthetic Dentistry*.