

Changes in Sinus Membrane Thickness After Lateral Sinus Floor Elevation: A Radiographic Study

Christian Makary, DDS, PhD¹/Alberto Rebaudi, MD, DDS²/
Abdallah Menhall, DDS³/Nada Naaman, DDS, PhD⁴

Purpose: To radiographically monitor sinus membrane swelling after lateral sinus floor elevation surgery at short and long healing periods. **Materials and Methods:** For 26 patients seeking posterior maxillary implant-supported reconstruction, 32 lateral sinus floor elevations were performed using Piezosurgery. Sinus membranes were grafted using synthetic calcium phosphate bone substitutes, and graft volume was measured in cubic centimeters for each case. Cone beam computed tomography (CBCT) examination was conducted preoperatively in all patients and for each grafted sinus at 1 day (n = 8), 2 days (n = 9), 3 days (n = 8), or 7 days (n = 7) after surgery. Control CBCT was then performed for all patients at 3, 6, and 12 months after surgery. Sinus membrane thickness was measured on cross-sectional CBCT images at nine standardized points per sinus, before lateral sinus floor elevation and at all postoperative examinations. **Results:** Mean sinus membrane thickness was 0.73 mm before surgery, and 5 mm, 4.1 mm, 5.9 mm, and 7 mm, respectively, at 1, 2, 3, and 7 days after surgery. First week combined postoperative CBCT measurements of membrane thickness was 5.4 mm, then 1.3, 0.68, and 0.39 mm at 3, 6, and 12 months, respectively, after surgery. Membrane thickness significantly increased the first week after surgery and gradually decreased significantly at 3, 6, and 12 months in all groups ($P < .001$). First-week postoperative measurements showed a significant increase in membrane thickness at 3 days compared with the 1- and 2-day results ($P < .001$) and at 7 days compared with all other time points ($P < .001$). Membrane thickness at 2 days did not change significantly compared with 1-day measurements. Larger graft volume was positively correlated with an increase in membrane thickness after surgery at all time points ($n = 32$; $r = 0.527$; $P < .001$). **Conclusion:** After lateral sinus floor elevation surgery, transient swelling of sinus membrane is observed. It reaches a peak value 7 days after surgery and completely resolves over months. This swelling is correlated to the extent of sinus floor elevation. *INT J ORAL MAXILLOFAC IMPLANTS* 2016;31:331–337. doi: 10.11607/jomi.4108

Key words: CBCT, lateral sinus floor elevation, mucosal thickness, posterior maxilla, sinus augmentation, sinus membrane

The edentulous posterior maxilla often presents insufficient bone quality and quantity for a predictable rehabilitation using endosseous oral implants.¹ Crestal bone resorption along with pneumatization of the maxillary sinus are often evident after posterior tooth loss.²

Sinus floor elevation was introduced to restore an atrophic posterior maxilla.^{3,4} This procedure showed high clinical success whether applied before or in conjunction with implant placement.^{5,6}

Different biomaterials can be predictably used for sinus augmentation such as autogenous bone in blocks from extraoral donor sites⁷ or from intraoral sites,⁸ allografts,⁹ xenografts,¹⁰ and synthetic biomaterials.¹¹

Rotary instruments were first used to perform sinus floor elevation,⁴ but nowadays, Piezosurgery is the technique of choice for lateral window opening and sinus membrane elevation.¹² Because of their selective action on hard and soft tissues, ultrasonic instruments allow precise and effective osteotomy when preparing a lateral window without compromising soft tissue integrity, thus reducing sinus membrane perforation during surgery.¹³

Radiographic technology is a major tool for lateral sinus floor elevation planning and grafted bone follow-up.¹⁴ Since its introduction, cone beam computed tomography (CBCT)¹⁵ has become the technique of choice for exploring

¹Assistant Professor and Head, Oral Surgery Department, Faculty of Dental Medicine, St Joseph University, Beirut, Lebanon.

²Private Practice, Genoa, Italy; Vice-President, Biomaterials Clinical Research Association, Pescara, Italy.

³Resident, Oral Surgery Department, Faculty of Dental Medicine, St Joseph University, Beirut, Lebanon.

⁴Professor, Periodontology Department and Dean, Faculty of Dental Medicine, St Joseph University, Beirut, Lebanon.

Correspondence to: Dr Christian Makary, Department of Oral Surgery, Faculty of Dental Medicine, Campus of Medical Sciences, Saint-Joseph University, Damascus Road, Beirut 1104 2020, Lebanon. Fax +961 (1) 421024. Email: christian.makary@usj.edu.lb

©2015 by Quintessence Publishing Co Inc.

paranasal sinuses before lateral sinus floor elevation.¹⁴ CBCT was shown to be very effective for evaluating the presence of anatomical variations and pathologies inside the sinus¹⁶ and for measuring sinus membrane thickness.¹⁷

Maxillary sinus lining membrane consists of a pseudostratified ciliated respiratory epithelium protecting it from exogenous agents by acting as a physical barrier and a mechanical clearing system.¹⁸ Following sinus membrane damage, initial postsurgical bleeding causes vasoactive substance release, leading to primary clot formation underneath it. It is followed by an inflammatory phase characterized by membrane transitory swelling that predominates at 48 hours and subsides over a period of several days.¹⁹

Following lateral sinus floor elevation, radiographic studies have not shown substantial changes in sinus membrane thickness at long-term healing periods.²⁰ Nevertheless, very few studies described early changes in the membrane after this procedure.

In a clinical study, Quirynen et al²¹ described a transient swelling of sinus membrane 1 week after crestal sinus floor elevation, which returned to normal after 3 weeks. Membrane thickness changes after sinus surgery are believed to occur because of the expression of swelling and postsurgical inflammatory reaction; the present radiographic study observed membrane thickness behavior after lateral sinus floor elevation at early and late healing times using CBCT.

MATERIALS AND METHODS

A prospective clinical study was conducted to assess clinical, histologic, and radiographic performance of eight different bone substitutes grafted into the maxillary sinus, and the behavior of sinus membrane after lateral sinus floor elevation was observed. Twenty-six patients seeking 32 lateral sinus floor elevations were included in this study. All treated patients had pneumatized sinuses with residual sinus floor heights of less than 5 mm. All patients were in good health, with no systemic disorders. All were accurately informed about the procedure, and all signed an informed consent form. The study was approved by the ethics committee at Saint Joseph University (Beirut, Lebanon).

Preoperative examination included CBCT as well as clinical examination. All surgeries were performed at the Oral Surgery Department, Faculty of Dental Medicine at Saint-Joseph University.

Surgical Procedure

Patients were asked to rinse with chlorhexidine digluconate solution (0.2%) for 1 minute approximately 10 minutes before surgery. Under localized anesthesia, a crestal incision and a full-thickness flap elevation were performed to expose the buccal wall of the maxillary sinus.

Lateral window opening was performed using Piezosurgery (Mectron). With standard elevators and Piezosurgery inserts specific to this procedure, the sinus membrane was elevated. Metronidazole solution (0.5%) was used to wash the sinus and hydrate the graft as described by Choukroun et al.²² The sinus membrane was then grafted using synthetic calcium phosphate bone substitutes (Eurocoating, Trento, Italy), and the graft volume, measured in cubic centimeters, was noted for each case. Four types of synthetic calcium phosphate biomaterials were used in this study: pure phase HA, pure phase bTCP, biphasic HA/bTCP (60%/40%), and biphasic HA/TTCP (60%/40%). In each graft type, two different granulometries were used, round 500- to 1,000- μ m granules and 1,200- to 5,000- μ m aggregates of round granules. The eight different combinations of biomaterials and granule sizes were randomly and evenly used for all 32 sinus grafts included in this study, leading to four grafted sinuses per biomaterial type/granule size.

A collagen membrane was placed to cover the lateral window, and flaps were approximated and sutured. Patients were prescribed analgesics (ibuprofen 400 mg twice a day), local steroid and prophylactic antibiotic coverage (amoxicillin + clavulanic acid 2 g daily, or in case of allergy, clindamycin 600 mg daily) for 7 days, and oral rinses of 0.12% chlorhexidine gluconate for 15 days after implant placement. Patients were recalled for suture removal 7 days after surgery and were clinically and radiographically followed up until implant placement and final prosthetic reconstruction.

Radiographic Examination

CBCT was performed before surgery using the same Newtom VGI radiographic machine (QR) for all patients. After lateral sinus floor elevation, patients were randomly assigned to four different groups to perform CBCT for each grafted sinus at 1 day ($n = 8$), 2 days ($n = 9$), 3 days ($n = 8$), or 7 days ($n = 7$) after surgery. Postoperative control CBCT was then performed for all patients at 3 months, 6 months, and 12 months.

Sinus membrane thickness was measured to the nearest 0.1 mm at three different locations in the maxillary sinus by two different investigators (C.M. and A.M.). To define these locations, a horizontal line was drawn on the panoramic CBCT view along the maximal mesiodistal length of the sinus, and three measuring planes were selected at quarter, half, and three quarters that distance (Fig 1). For each of these locations, the corresponding cross-sectional CBCT image was retrieved and three different measurements were performed on it. To locate the measurement points, a first vertical line passing through the middle of the crest was drawn (midline); a middle (m) measurement of the sinus membrane thickness was taken on the intersection between the midline and sinus floor. A second horizontal line perpendicular to the midline was drawn 5 mm above

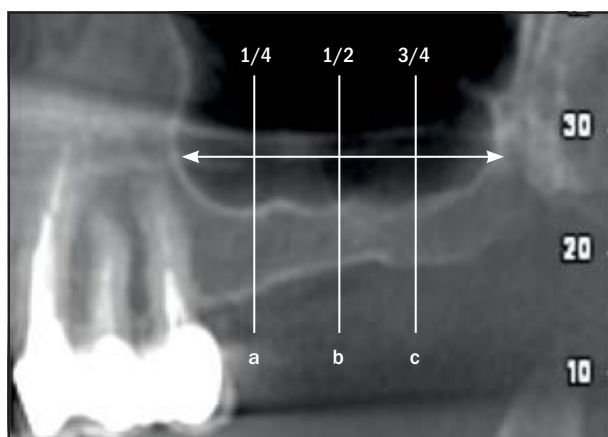


Fig 1 For each maxillary sinus, three locations were selected at the (a) quarter, (b) middle, and (c) third quarter of the mesiodistal sinus dimension.

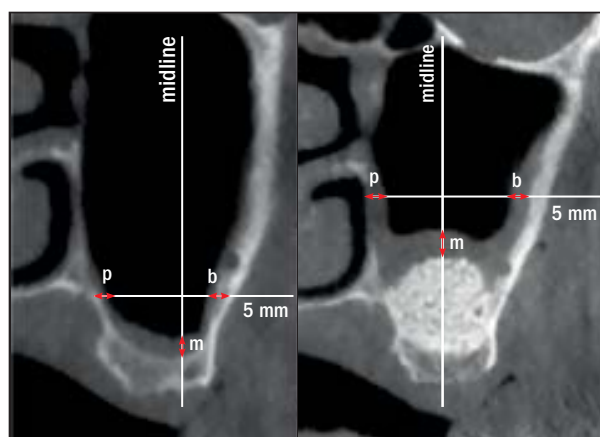


Fig 2 Three measurement points were selected at chosen cross-sectional CBCT images: middle (m), palatal (p), and buccal (b).

the sinus mucosa, and the intersections between this line and both palatal and buccal sinus walls, at two different points, were defined as palatal (p) and buccal (b). The sinus membrane thickness was then measured at these points (Fig 2). These measurements were repeated at the three sinus locations described earlier, leading to a total of nine standardized measuring points per sinus. Measurements were done before the lateral sinus floor elevation, at the first-week examinations (1, 2, 3, and 7 days), and at the 3-, 6-, and 12-month postoperative examinations.

The combined mean value of 1-, 2-, 3-, and 7-day results was calculated and defined as the first-week postoperative combined result.

Statistical Analyses

Statistical analyses were performed using the SPSS for Windows, version 18.0 software program (SPSS). The level of significance was set at $\alpha = .05$. Repeated-measures analysis of variance was conducted to explore significant differences in mean membrane thickness at baseline, first-week postoperative combined, 3 months, 6 months, and 12 months. This analysis was followed by Bonferroni multiple comparison.

One-way analysis of variance followed by Tukey (honest significant difference) post-hoc tests were also conducted to explore a significant difference in first week mean sinus membrane thickness among day 1, day 2, day 3, and day 7 values.

The relationship between graft volume and sinus membrane thickness for each time point was investigated using a Pearson product-moment correlation coefficient. Preliminary analyses were performed to ensure that normality, linearity, and homoscedasticity assumptions were not violated.

RESULTS

All 26 patients selected for the study underwent 32 lateral sinus floor elevations successfully and with no major complication.

Preoperative sinus membrane mean thickness as evaluated on CBCT was 0.73 mm.

First-week CBCT images indicated mean sinus membrane thickness of 5 mm, 4.1 mm, 5.9 mm, and 7 mm at 1 day, 2 days, 3 days, and 7 days, respectively. Mean membrane thickness increases significantly at 3 days compared with results at 1 day and 2 days ($P < .001$) and at 7 days compared with all other time points ($P < .001$). There was no significant change in membrane thickness at 2 days compared with 1-day results (Figs 3 and 4).

Mean sinus membrane thickness for the combined first-week postoperative measures was 5.4 mm, decreasing to 1.3 mm, 0.68 mm, and 0.39 mm at 3, 6, and 12 months, respectively (Figs 5 and 6). Sinus membrane thickness increased significantly the first week after surgery and then decreased significantly at 3, 6, and 12 months ($P < .001$). Mean sinus membrane thickness was significantly lower 12 months after surgery than before surgery ($P = .048$).

A positive correlation was noted between larger graft volume and membrane thickness immediately after surgery at all time points ($n = 32$; $r = 0.527$; $P < .001$).

No significant correlation was noted between sinus membrane thickness and type of synthetic bone substitute ($P = .359$) or between sinus membrane thickness and size of biomaterial particles ($P = .293$).

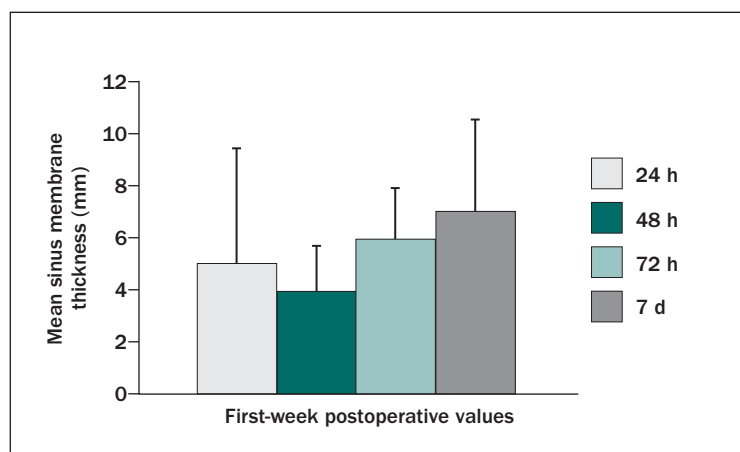


Fig 3 (left) Mean Shneiderian membrane thickness at early postoperative periods.

Fig 4 (below) Typical sinus membrane thickness as seen on CBCT cross-sectional images in different patients at (a) 1 day, (b) 2 days, (c) 3 days, and (d) 7 days after surgery.

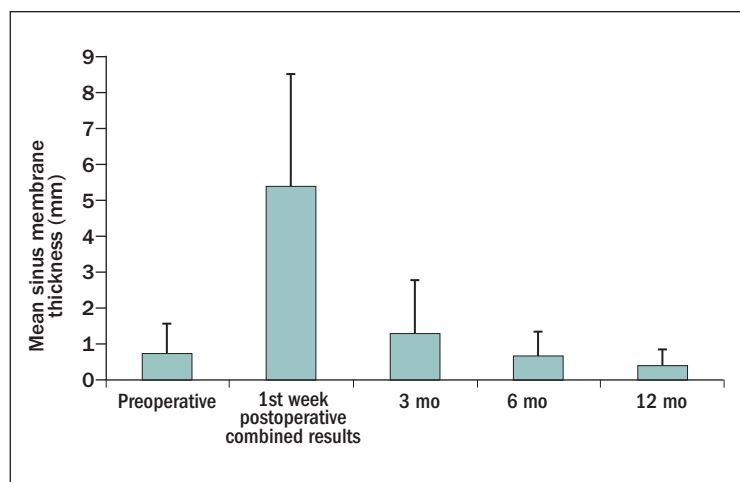
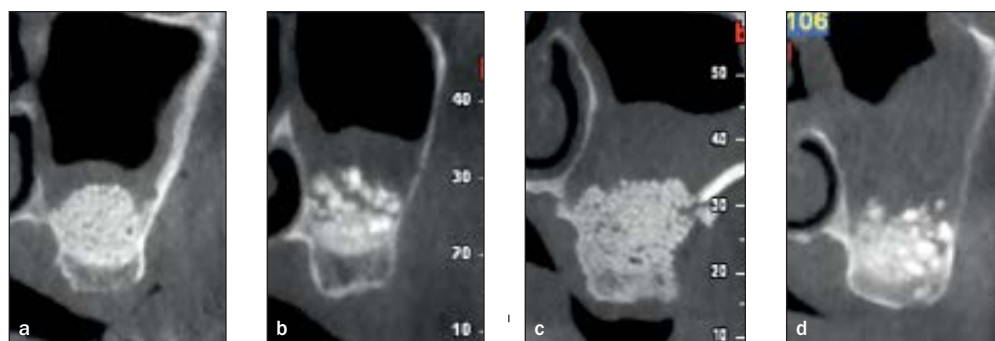
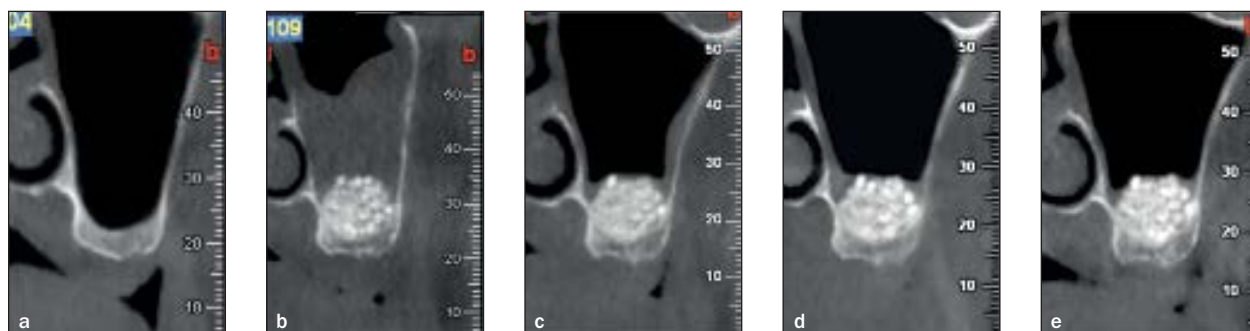


Fig 5 (left) Mean sinus membrane thickness over a 12-month period. Preop = preoperative; postop = postoperative.

Fig 6 (below) Radiographic follow-up findings of changes in sinus membrane thickness for the same patient (a) before surgery and at (b) 7 days, (c) 3 months, (d) 6 months, and (e) 12 months after surgery.



DISCUSSION

In the present study, sinus membrane thickness was measured with CBCT. Although an automated Hounsfield threshold-based computed tomography evaluation has been used to predictably determine sinus membrane thickness,²³ the present study measured sinus membrane thickness on CBCT images following linear measurements at two points. Because this technique may have some limitations with regard to measurement reproducibility, all calculations were done after agreement between two different evaluators.

Multiple studies showed large variability in sinus membrane thickness; some studies reported postmortem sinus mucosa measurements of a mean value of 0.8 mm in noninfected sinuses,²⁴ whereas others described a mean value of 0.09 mm.²⁵ This intervariability in sinus mucosa thickness was described by Janner et al¹⁷ in a radiographic study that showed a wide range of measurements varying between 0.16 and 34.61 mm.

Sinus mucosa thickness in this study varied between 0.1 and 3.6 mm, with a mean value of 0.7 mm. The present study enrolled only those patients who were suitable for sinus surgery with no evident sinus pathologies; therefore, preoperative sinus membrane thickness measurements were probably lower than those described in other studies,¹⁷ which manifestly enrolled patients regardless of pre-existing pathologic thickening of sinus mucosa. Moreover, many factors may influence sinus membrane thickness, such as gender, climate, smoking habits, allergies, and seasonal changes.¹⁷ Six of the 26 patients included in the present study underwent bilateral lateral sinus floor elevation and were among the 32 sinuses with follow-up data. Consequently, the aforementioned individual factors might be a source of bias in sinus mucosa behavior described in this article.

The main observation of the present study was a significant transient thickening of sinus membrane after lateral sinus floor elevation surgery. This thickening may be caused by a physiologic inflammatory reaction to surgical trauma involving bleeding and swelling at initial healing phases. Although nasal and paranasal mucosa reaction to different injuries such as infection, allergy, or surgical trauma have been described,^{26,27} sinus membrane reaction to lateral sinus floor elevation is poorly described in the literature. In 2002, Watelet et al¹⁹ clearly described the process of nasal and paranasal mucosa wound healing after injury. These authors divided this process into four overlapping phases: inflammation, cell proliferation, matrix deposition, and tissue remodeling. However, these recovery stages are described in the context of sinus surgery involving partial or total resection of sinus membrane, whereas in lateral sinus floor elevation, the sinus mucosa is kept intact and is only detached from underlying bone. Scala et al,²⁸ after performing

lateral sinus floor elevation in monkeys, sacrificed the animals at 4, 10, and 30 days and performed a histologic examination. The authors described the presence of a coagulum underneath the sinus membrane along with a dense inflammatory infiltrate inside this membrane at 4 days. Inflammatory infiltrate significantly reduced at 10 days, whereas at 30 days, the sinus mucosa appeared normal with only a few inflammatory cells.

Quirynen et al,²¹ in a radiographic study, were the first to describe early sinus mucosa behavior after crestal sinus floor elevation. They showed a significant swelling of sinus mucosa 1 week after surgery, which totally disappeared after 1 month. The radiographic results of the present study showed membrane thickening after lateral sinus floor elevation with a mean value of 5.4 mm during the first-week follow-up. This value is lower than the mean value of 6.7 mm measured by Quirynen et al. This difference may be explained by the fact that these authors only calculated 7 days' results, whereas the present study also takes into account findings at 1, 2, and 3 days. When considering only 7-day postoperative values, results of this study showed a mean sinus mucosa thickness of 7 mm, which is similar to previously described findings.

The present study interestingly showed a significant increase in sinus membrane thickening at 3 and 7 days compared with the lower increase observed at 1 and 2 days after surgery. The lower values encountered at 1 and 2 days may be related to the early wound healing phase that involves primary clot formation, whereas the inflammatory phase starts at 48 hours.¹⁹ This inflammatory phase, characterized by a larger infiltration of polymorphonuclear cells inside the sinus membrane, is clearly demonstrated by significantly higher thickening of sinus membrane at 3 and 7 days, and reaching up to 10 times its original thickness.

In some instances, early hemorrhagic fill of the sinus that might occur after surgery may mimic pathologic or inflammatory thickening of sinus membrane observed on radiographs. Nevertheless, this radiographic finding shows a horizontal fill of the sinus, and is different from membrane swelling, which can also be observed on the lateral aspect of sinus walls. In the present study, lateral wall membrane swelling was taken into consideration by measuring membrane thickness at the palatal, middle, and buccal part of the sinus to obtain more reliable measurements.

To the best of the authors' knowledge, this is the first longitudinal study monitoring sinus membrane swelling at different early healing periods, along with a follow-up period of 3, 6, and 12 months. In the present study, sinus mucosa at 3 months was significantly thicker than it was before surgery, whereas the results of other authors showed a return to normal of the sinus mucosa 1 month after surgery.²⁸ To explain the apparent contradiction,

the previously cited study applied a crestal sinus approach, which involves less invasive surgery, and therefore minimal detachment of sinus mucosa. The present study, however, describes sinus mucosa behavior after sinus floor elevation using a lateral approach, which requires an extensive detachment of the membrane along with considerable flap elevation and a large bone access window.

A positive significant correlation between sinus graft volume and membrane thickening at early postoperative periods was observed in the present study. This observation supports the authors' hypothesis that larger sinus elevation may lead to more pronounced membrane thickening even at 3 months after surgery.

The persistent thickening of sinus mucosa observed in this work may be the result of altered physiologic function after surgical trauma. Studies have reported histologic alterations of sinus mucosa after sinus surgery, leading to a decrease in its physiologic behavior mainly characterized by cleaning and clearance of the surface.²⁹ After lateral sinus floor elevation, animal studies showed histologic changes in the sinus mucosa, characterized by reduction of mucocilliary cells and increase of goblet cells.^{30,31} Clinical studies have shown mucocilliary activity impairment in the detached part of this mucosa.³² Timmenga et al,³³ in a human histologic study, described an increase of goblet cells at 3 and 9 months after lateral sinus floor elevation compared with preoperative histology. The authors explained this cellular modification as a physiologic adaptation that the sinus membrane undergoes over months. The same authors also examined the microbiology of sinus mucosa surface and described an increase in cultures with bacterial growth at 3 months after sinus floor elevation. The authors hypothesize that the maxillary sinus mucosal lining was affected after the surgical procedure, leading to the impairment of mucosal defense system mainly characterized by transitory reduction of sinus drainage.

Sinus membrane behavior at 3 months observed in the present study may be the result of the physiologic and microbiologic changes described before, leading to a temporary impaired function of sinus mucosa and causing a slight persistent but transitory inflammation.

The present study also indicated that sinus mucosa thickening was significantly reduced at 6 months compared with 3 months, reaching its preoperative normal value. This observation is in contradiction with those of other authors who described a significant difference in postoperative sinus thickness that persisted at 6 and 9 months compared with preoperative results.^{23,34} Moreover, sinus mucosa thickening was significantly reduced at 12 months compared with findings at 6 months, and showed a mean thickness of 0.12 mm that was also significantly lower than preoperative values.

This gradual decrease in membrane thickness that goes on until 1 year after surgery may be caused by the

physiologic readaptation of sinus mucosa along with an enhanced activity of ciliary epithelium, leading to a better cleansing of sinus surface. This is in accord with Timmenga et al,³³ who described a recovery of both microbiologic flora and histologic characteristics of sinus membrane at 9 months after surgery. Also, in an animal study, histologic examination 6 months after lateral sinus floor elevation showed a totally healthy aspect of sinus mucosa.³⁵

Findings at 12 months surprisingly showed a significant reduction of membrane thickness compared with preoperative measurements. This may be explained by an improvement in sinus mucosa physiologic function related to the aforementioned histologic changes occurring in this mucosa after surgical trauma. On the other hand, Forsgren et al,³⁶ in an animal study, described atrophic sinus membrane with a decreased thickness after complete sinus membrane removal. In the present work, sinus mucosa was not removed but only elevated. Nevertheless, this reduction in membrane thickness may also be caused by sinus mucosa atrophy after surgical trauma. Further histologic studies should be conducted to confirm both hypotheses.

The choice of grafting materials for sinus augmentation may play a role in membrane behavior at longer postoperative healing periods because it is obvious that a biomaterial that can evoke a higher immunologic response may lead to an inflammatory reaction. In a series of endoscopic observations at long healing periods, Aimetti et al³⁷ described a slightly inflamed sinus mucosa over allografts and heterografts compared with totally healthy mucosa when the sinus was grafted with autogenous bone. In the present study, four different allopastic calcium phosphate biomaterials were used, and data showed that these biomaterials did not generate an inflammatory response of the sinus membrane at long healing times because its thickness returned to normal at 6 months. Also, both grafting particle sizes used in this study did not lead to any differences in membrane behavior at short and long healing periods.

CONCLUSIONS

After lateral sinus floor elevation surgery, the sinus mucosa undergoes significant thickening. This thickening is believed to be a physiologic inflammatory reaction that is more pronounced at 3 and 7 days after surgery compared with the results at 1 and 2 days. Long-term observations revealed a slight but persistent swelling at 3 months, which completely disappeared at the 6-month follow-up when sinus mucosa reached its previous preoperative thickness. At 12 months, observations interestingly showed a significant reduction of membrane thickness compared with its preoperative size.

ACKNOWLEDGMENTS

The authors report no conflicts of interest related to this study.

REFERENCES

1. Zarb GA, Albrektsson T. *Tissue-Integrated Prosthesis: Osseointegration in Clinical Dentistry*. Chicago: Quintessence, 1985.
2. Misch CE, Judy KW. Classification of partially edentulous arches for implant dentistry. *Int J Oral Implantol* 1987;4:7–13.
3. Tatum H Jr. Maxillary and sinus implant reconstructions. *Dental Clin North Am* 1986;30:207–229.
4. Boyne PJ, James RA. Grafting of the maxillary sinus floor with autogenous marrow and bone. *J Oral Surg* 1980;38:613–616.
5. Del Fabbro M, Testori T, Francetti L, Weinstein R. Systematic review of survival rates for implants placed in the grafted maxillary sinus. *Int J Periodontics Restorative Dent* 2004;24:565–577.
6. Pjetursson BE, Tan WC, Zvahlen M, Lang NP. A systematic review of the success of sinus floor elevation and survival of implants inserted in combination with sinus floor elevation. *J Clin Periodontol* 2008;35:216–240.
7. Tulasne JF. *Sinus grafting with calvarial bone*. The Sinus Bone Graft, London: Quintessence 1999:107–116.
8. Wood RM, Moore DL. Grafting of the maxillary sinus with intraorally harvested autogenous bone prior to implant placement. *Int J Oral Maxillofac Implants* 1987;3:209–214.
9. Froum SJ, Wallace SS, Elian N, Cho SC, Tarnow DP. Comparison of mineralized cancellous bone allograft (Puros) and anorganic bovine bone matrix (Bio-Oss) for sinus augmentation: Histomorphometry at 26 to 32 weeks after grafting. *Int J Periodontics Restorative Dent* 2006;26:543–551.
10. Yildirim M, Spiekermann H, Handt S, Edelhoff D. Maxillary sinus augmentation with the xenograft Bio-Oss and autogenous intraoral bone for qualitative improvement of the implant site: A histologic and histomorphometric clinical study in humans. *Int J Oral Maxillofac Implants* 2001;16:23–33.
11. Zijdeveld SA, Zerbo IR, van den Bergh JP, Schulten EA, ten Bruggenkate CM. Maxillary sinus floor augmentation using a beta-tricalcium phosphate (Cerasorb) alone compared to autogenous bone grafts. *Int J Oral Maxillofac Implants* 2005;20:432–440.
12. Vercellotti T, De Paoli S, Nevins M. The piezoelectric bony window osteotomy and sinus membrane elevation: Introduction of a new technique for simplification of the sinus augmentation procedure. *Int J Periodontics Restorative Dent* 2001;21:561–567.
13. Vercellotti T. Technological characteristics and clinical indications of piezoelectric bone surgery. *Minerva Stomatol* 2004;53:207–214.
14. Harris D, Horner K, Gröndahl K, et al. EAO guidelines for the use of diagnostic imaging in implant dentistry 2011. A consensus workshop organized by the European Association for Osseointegration at the Medical University of Warsaw. *Clin Oral Implants Res* 2012;23:1243–1253.
15. Mozzo P, Procacci C, Tacconi A, Martini PT, Andreis IAB. A new volumetric CT machine for dental imaging based on the cone-beam technique: Preliminary results. *Eur Radiol* 1998;8:1558–1564.
16. Lana JP, Carneiro PM, Machado Vde C, de Souza PE, Manzi FR, Horta MC. Anatomic variations and lesions of the maxillary sinus detected in cone beam computed tomography for dental implants. *Clin Oral Implants Res* 2012;23:1398–1403.
17. Janner SFM, Caversaccio MD, Dubach P, Sendi P, Buser D, Bornstein MM. Characteristics and dimensions of the Schneiderian membrane: A radiographic analysis using cone beam computed tomography in patients referred for dental implant surgery in the posterior maxilla. *Clin Oral Implants Res* 2011;22:1446–1453.
18. Torkkeli T, Rautiainen M, Nuutinen J. Ciliary ultrastructure and mucociliary transport in upper respiratory tract infections. *Am J Rhinol* 1994;8:211–215.
19. Watelet JB, Bachert C, Gevaert P, Van Cauwenberge P. Wound healing of the nasal and paranasal mucosa: A review. *Am J Rhinol* 2002;16:77–84.
20. Anduze-Acher G, Brochery B, Felizardo R, Valentini P, Katsahian S, Bouchard P. Change in sinus membrane dimension following sinus floor elevation: A retrospective cohort study. *Clin Oral Implants Res* 2013;24:1123–1129.
21. Quirynen M, Lefever D, Hellings P, Jacobs R. Transient swelling of the Schneiderian membrane after transversal sinus augmentation: A pilot study. *Clin Oral Implants Res* 2014;25:36–41.
22. Choukroun J, Simonpieri A, Del Corso M, Mazor Z, Sammartino G, Ehrenfest DMD. Controlling systematic perioperative anaerobic contamination during sinus-lift procedures by using metronidazole: An innovative approach. *Implant Dent* 2008;17:257–270.
23. Pommer B, Dvorak G, Jesch P, Palmer RM, Watzek G, Gahleitner A. Effect of maxillary sinus floor augmentation on sinus membrane thickness in computed tomography. *J Periodontol* 2012;83:551–556.
24. Tos M. Mucus production in the nasal sinuses. *Acta Otolaryngol Suppl* 1979;360:131–134.
25. Pommer B, Unger E, Sütö D, Hack N, Watzek G. Mechanical properties of the Schneiderian membrane in vitro. *Clin Oral Implants Res* 2009;20:633–637.
26. Wigand ME, Göde U, Linger F, Dunker I. Normal wound healing of the paranasal sinuses: Clinical and experimental investigations. *Eur Arch Otorhinolaryngol* 1991;248:390–394.
27. Fokkens W, Lund V, Bachert C, et al. EAACI position paper on rhinosinusitis and nasal polyps executive summary. *Allergy* 2005;60:583–601.
28. Scala A, Botticelli D, Rangel IG Jr, de Oliveira JA, Okamoto R, Lang NP. Early healing after elevation of the maxillary sinus floor applying a lateral access: A histological study in monkeys. *Clin Oral Implants Res* 2010;21:1320–1326.
29. Toskala E, Rautiainen M. Effects of surgery on the function of maxillary sinus mucosa. *Eur Arch Otorhinolaryngol* 2005;262:236–240.
30. Bravetti P, Membre H, Marchal L, Jankowski R. Histologic changes in the sinus membrane after maxillary sinus augmentation in goats. *J Oral Maxillofac Surg* 1998;56:1170–1177.
31. Onisor-Gligor F, Lucaci O, Campian R, Oana L, Gheban D, Florea A. Experimental study on histological changes in the sinus membrane following sinus lift. *Rom J Morphol Embryol* 2011;52:1293–1297.
32. Griffa A, Berrone M, Boffano P, Viterbo S, Berrone S. Mucociliary function during maxillary sinus floor elevation. *J Craniofac Surg* 2010;21:1500–1502.
33. Timmenga NM, Raghoobar GM, Liem RSB, Van Weissenbruch R, Manson WL, Vissink A. Effects of maxillary sinus floor elevation surgery on maxillary sinus physiology. *Eur J Oral Sci* 2003;111:189–197.
34. Anduze-Acher G, Brochery B, Felizardo R, Valentini P, Katsahian S, Bouchard P. Change in sinus membrane dimension following sinus floor elevation: A retrospective cohort study. *Clin Oral Implants Res* 2013;24:1123–1129.
35. Sul SH, Choi BH, Li J, Jeong SM, Xuan F. Histologic changes in the maxillary sinus membrane after sinus membrane elevation and the simultaneous insertion of dental implants without the use of grafting materials. *Oral Surg Oral Med Oral Pathol Oral Radiol Endod* 2008;105:e1–e5.
36. Forsgren K, Stiernä P, Kumlien J, Carlsson B. Regeneration of maxillary sinus mucosa following surgical removal. Experimental study in rabbits. *Ann Otol Rhinol Laryngol* 1993;102:459–466.
37. Aimetti M, Romagnoli R, Ricci G, Massei G. Maxillary sinus elevation: The effect of macrolacerations and microlacerations of the sinus membrane as determined by endoscopy. *Int J Periodontics Restorative Dent* 2001;21:581–589.