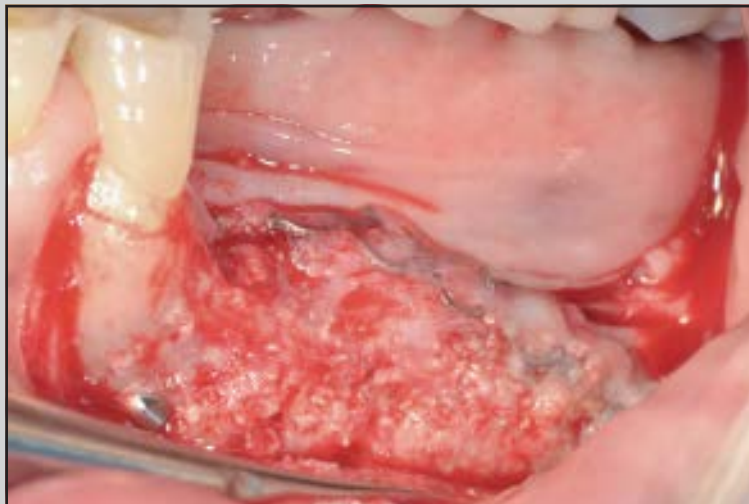
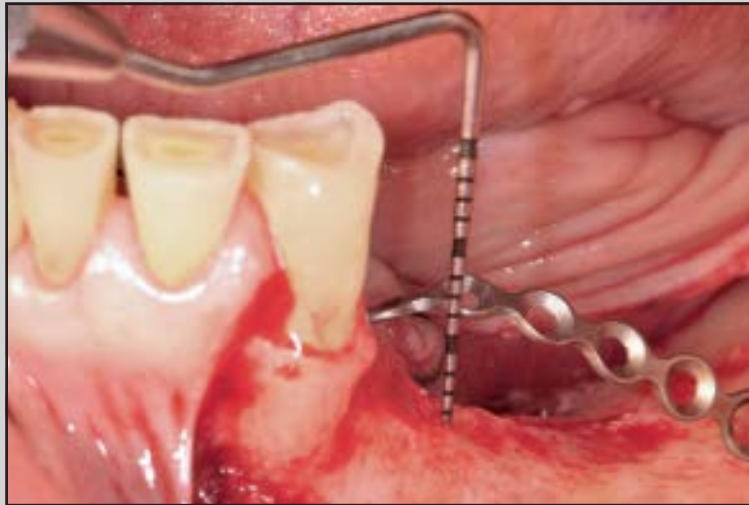
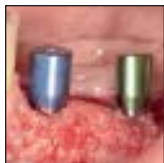# Fence Technique for Localized Three-Dimensional Bone Augmentation: A Technical Description and Case Reports



Mauro Merli, MD, DDS<sup>1</sup>  
 Giorgia Mariotti, DDS<sup>2</sup>/Marco Moscatelli, DDS<sup>2</sup>  
 Alessandro Motroni, MS<sup>3</sup>/Annalisa Mazzoni, DDS, PhD<sup>4</sup>  
 Simona Mazzoni, MD, DDS, PhD<sup>5</sup>/Michele Nieri, DDS<sup>6</sup>

*This study presents a novel bone reconstructive technique based on guided bone regeneration for localized three-dimensional hard tissue augmentation. This two-stage technique utilized a titanium osteosynthesis plate and a collagen membrane to form a physical barrier resembling a fence that contains bone graft biomaterial composed of a combination of deproteinized bovine bone matrix and autologous bone grafted from intraoral sites. Six patients were treated. At 6 months postsurgery, an increase in bone volume of 953 mm<sup>3</sup> was shown. Mean maximum linear augmentation in the vertical direction was 6.75 mm. Histologic analysis of the regenerated area revealed the presence of compact newly formed bone with no sign of inflammation. A total of 13 implants were placed. Peri-implant marginal bone level was 0.94 mm at implant placement and 1.30 mm after 6 months. The patients were satisfied with the procedure and no complications were observed. (Int J Periodontics Restorative Dent 2015;35:57–64. doi: 10.11607/prd.2029)*

Bone augmentation procedures are applied in patients lacking an adequate quantity of bone for implant placement. Augmentation procedures are divided into two broad categories: horizontal bone augmentation, which increases the width of the recipient bone, and vertical bone augmentation, which increases the height of the recipient bone.<sup>1</sup>

In many instances, a combination of horizontal and vertical bone augmentation is needed. These three-dimensional (3D) bone defects can be treated by guided bone regeneration (GBR), distraction osteogenesis, autogenous inlay or onlay bone graft from intra- and extraoral donor sites, and an array of other techniques.<sup>2–9</sup> However, these techniques are often associated with high complication rates, costs, and patient discomfort.<sup>1</sup> Complications and discomfort at the extraoral donor site have been previously reported.<sup>10,11</sup> Szabò et al<sup>12</sup> described cases in which harvesting autogenous bone from the iliac crest resulted in permanent sensory loss in the distribution of the lateral femoral cutaneous nerve in one patient and

<sup>1</sup>Private Practice, Rimini, Italy; Clinical and Research Director, International Dental Research and Education (InDent), Rimini, Italy; Visiting Professor, Politecnico delle Marche, Ancona, Italy.

<sup>2</sup>Private Practice, Rimini, Italy; Research Assistant, InDent, Rimini, Italy.

<sup>3</sup>Director, Applied Medical Imaging Research Group (AMIRG), Milan, Italy.

<sup>4</sup>Fellow Researcher, Department of Medical Sciences, University of Trieste, Trieste, Italy.

<sup>5</sup>Private Practice, Rimini, Italy.

<sup>6</sup>Statistics and Research Coordinator, InDent, Rimini, Italy; Visiting Professor, University of Florence, Florence, Italy.

Correspondence to: Dr Mauro Merli, Viale Settembrini 17/O 47923 Rimini, Italy;  
 fax: +39-0541-52308; email: mauromerli@gmail.com.

©2015 by Quintessence Publishing Co Inc.

prolonged wound drainage in two patients. Intraoral donor sites could lead to fewer and less severe complications.<sup>13–15</sup>

The data obtained from a systematic review showed that GBR is a predictable technique that allows for the placement of implants in atrophic areas.<sup>16</sup> In GBR, barrier membranes, in combination with various graft materials such as autogenous bone, allografts, xenografts, and alloplastic materials, are often used for vertical bone augmentation.<sup>17–22</sup>

The results of a recent randomized controlled trial showed that the addition of bovine bone mineral and a collagen barrier membrane placed around and over a mandibular bone block graft could minimize graft resorption during healing compared to a mandibular bone block graft alone.<sup>23</sup>

The use of an autogenous bone block in combination with a barrier membrane has been reported to be effective when edentulous segments are to be treated for vertical ridge augmentation, but there are few reports of vertical GBR by applying a particulate graft.<sup>24</sup>

Recently, a new procedure for GBR, called the “fence technique,” was described: A space, based on the volume of the bone graft planned in advance, is created by modeling an osteosynthesis plate.<sup>25</sup> The “fence” provides a retaining space for the compressed particulate grafting biomaterial and support for the covering collagen membranes. This two-stage technique allows for the formation of large quantities of regenerated bone in both the horizontal and vertical dimensions with

limited discomfort to the patient and has been proposed for cases of extreme bone atrophy in edentulous maxillary jaws.<sup>25</sup>

The fence technique could be applied for osseous defects localized to a portion of a maxillary or mandibular arch for partially edentulous patients whose anatomy or prosthetic requirements do not permit the use of short or tilted implants.<sup>26–28</sup>

The aim of this study was to illustrate a variation of the original fence technique to be used for localized 3D augmentation.

## Method and materials

Eligible participants for this study were adults, 18 years old or older, in need of implant treatment and with an extremely atrophic localized edentulous alveolar crest in the mandible or the maxilla. The patients’ medical histories showed no systemic or local contraindications for surgical therapy. The research was conducted in full accordance with ethical principles, including the Declaration of Helsinki, and each participant gave written consent according to these principles.

### *Surgical procedure: The localized fence technique*

A two-stage procedure with intravenous sedation was planned for the six patients treated with the localized fence technique.

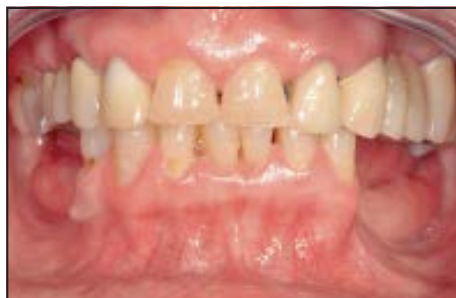Preliminary cone beam computed tomography (CBCT) scans of the atrophied arch were performed

to evaluate the 3D morphology of the hard tissue. The data were used to create a stereolithographic cast using specific epoxidic, thermosetting, and light-sensitive resins (3DIEEMME). This anatomical epoxy resin cast served as a framework for presurgical planning of the bone reconstruction procedure.

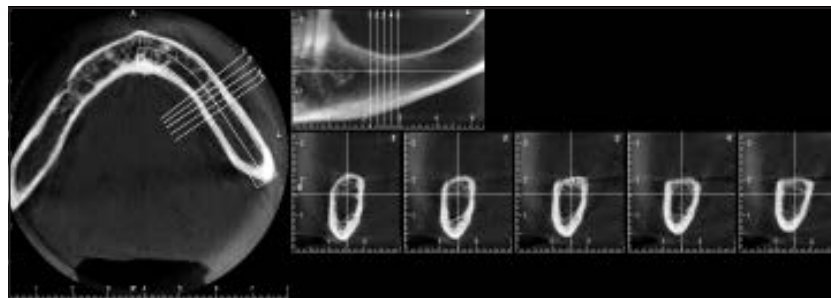
An osteosynthesis titanium plate was adapted to the cast to define the volume for the bone regeneration. The osteosynthesis plate used in the reconstructive stage was positioned at the planned distance from the native bone in order to constitute a physical barrier (ie, the “fence”) that would contain the biomaterial necessary for the regeneration, permitting vertical and/or horizontal augmentation.

At surgery, the incision was slightly positioned on the lingual side of the edentulous ridge with a vestibular bevel. This incision allowed for the complete exposure of the osseous ridge with a minimal elevation of the lingual flap. Furthermore, this incision maximized the conservation of the keratinized tissue on the vestibular aspect of the ridge. If required, a sinus floor elevation procedure was performed in the maxillary arch.

The osteosynthesis titanium plate was then fixed using specific miniscrews. When the plate was fixed and stable, the bone grafting phase began. In the six cases described, deproteinized bovine bone matrix (DBBM; Bio-Oss, Geistlich) was used in combination with the patient’s bone. The ratio between autologous bone and DBBM was approximately 50:50. The bone graft



**Fig 1** Case 1. Presurgical view of a 59-year-old nonsmoking female with an extremely atrophic alveolar crest on the left side of the mandible.



**Fig 2** Case 1. Presurgical cone beam computed tomography scans of the left side of the mandible.

was obtained from intraoral sites, preferably the mandibular area at the base of the ramus.

A semilunar incision in the alveolar mucosa approximately 1 cm distal to the third molar was used to gain access to the corpus ramus of the mandible and was extended along the bone crest, ending mesial and buccal to the first molar.<sup>29</sup> The osteotomy was performed with piezoelectric handpieces. Once the bone block was detached, the osteotomy cut edges were rounded off to prevent soft tissue trauma, and the mucosa was sutured.<sup>29</sup>

The harvested bone was then particulated using a manual milling machine (Hu-Friedy) and was mixed with DBBM and the patient's venous blood, resulting in a gelatinous consistency. To stimulate bone regeneration, micro-perforations were drilled into the residual bone crest to open marrow spaces. The biomaterial was then positioned to fill the entire space between the bone wall and the internal face of the plate.

The collagen resorbable membrane (Bio-Gide, Geistlich) was affixed by osteosynthesis titanium tacks to the lingual aspect of the

area (one tack at each membrane corner). After the membrane was reflected onto the vestibular side, two tacks were used to affix the membrane on the buccal side. The size of the membrane used was strictly dependent on the mesiodistal dimension of the edentulous area.

The creation of a perfect seal along the primary horizontal incision lines is fundamental to avoid the risk of dehiscence and possible exposure of the membrane surface and infection of the grafted bone. A flap extension technique (muscular dissection and/or perioplasty) fixed with a "double suture" was applied in order to avoid this type of complication.<sup>30</sup>

The implants (SPI-ELEMENT with INICELL surface, Thommen Medical) were inserted 6 months postsurgery and loaded 1 to 3 months after placement. Definitive prostheses were applied 3 to 6 months after loading.

The presence of complications was assessed during the entire procedure as well as 12 months after surgery, when the patients were asked to express their degree of satisfaction with the procedure via visual

analog scale (VAS) from 0 (greatly dissatisfied) to 10 (very satisfied). The questions addressed subjective problems with the procedure undertaken.

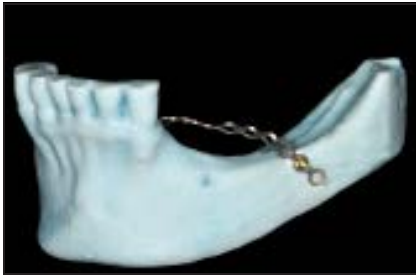The surgical procedures of two representative cases are shown in Figs 1 through 12.

### Bone graft analysis

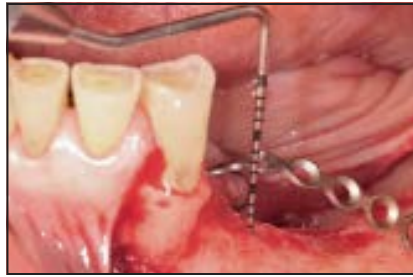Prior to surgery and at the 6-month follow-up before implant insertion, each patient underwent a CBCT scan of the treated arch. The dataset was exported in the Digital Imaging and Communications in Medicine (DICOM) format and processed with diagnostic and analysis software (3Diagnosys 4.0, 3DIEMME) in order to extract the bone surface in .stl format. Stereolithography (.stl) is a geometric file format compatible with the entire computer-aided-design (CAD) and reverse-engineering software packages suitable for a surface modification study between different bone reconstructions.

The presurgery and follow-up surfaces were imported in an industrial 3D inspection software

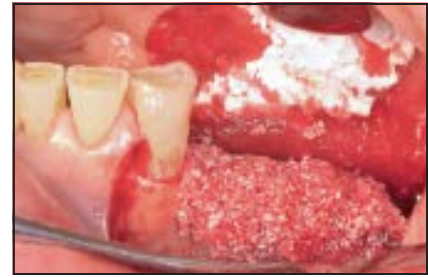



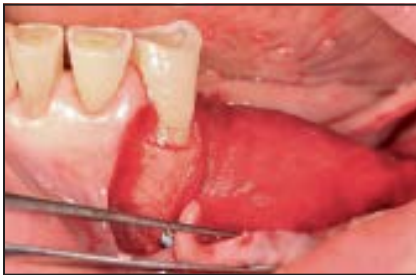**Fig 3** Case 1. Stereolithographic model with the osteosynthesis titanium plate.



**Fig 4** Case 1. Osteosynthesis titanium plate fixed at surgery.

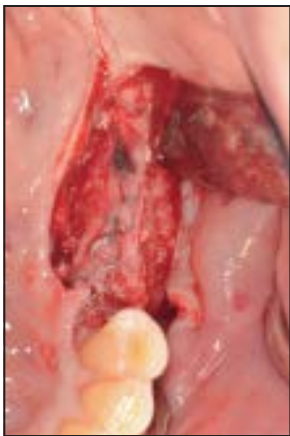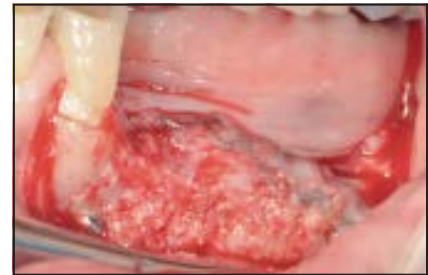


**Fig 5** Case 1. The space, confined by the osteosynthesis plate, was filled with the grafting material.

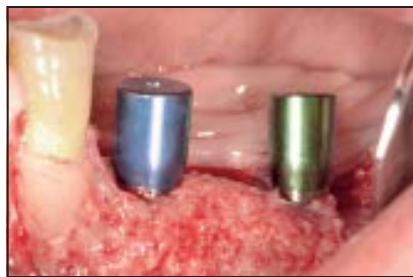

**Fig 6 (left)** Case 1. Membrane fixed with titanium tacks.

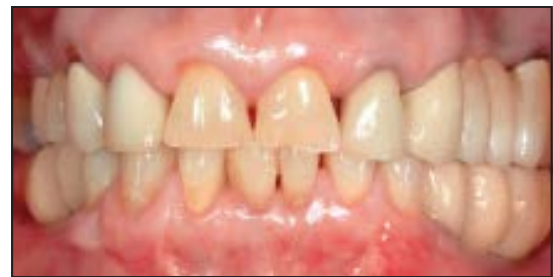**Fig 7 (right)** Case 1. Regenerated tissue at 6 months postsurgery.



**Fig 8** Case 1. Regenerated tissue at 6 months postsurgery. Occlusal view.



**Fig 9** Case 1. Two implants were inserted in the regenerated region at 6 months postsurgery.

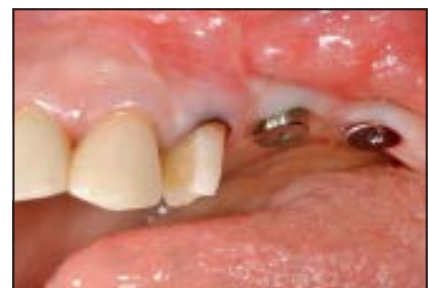

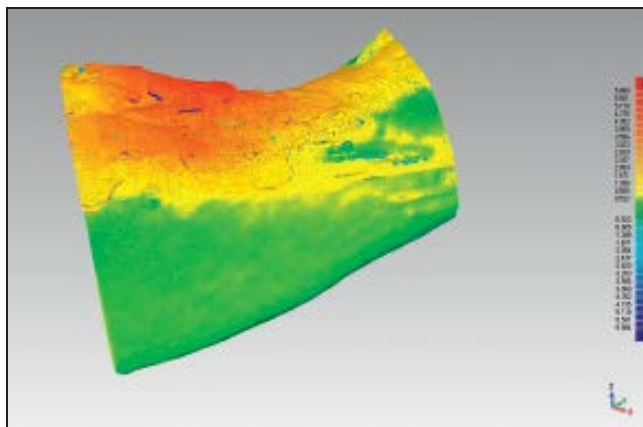
**Fig 10** Case 1. Provisional prosthesis 12 months postsurgery.



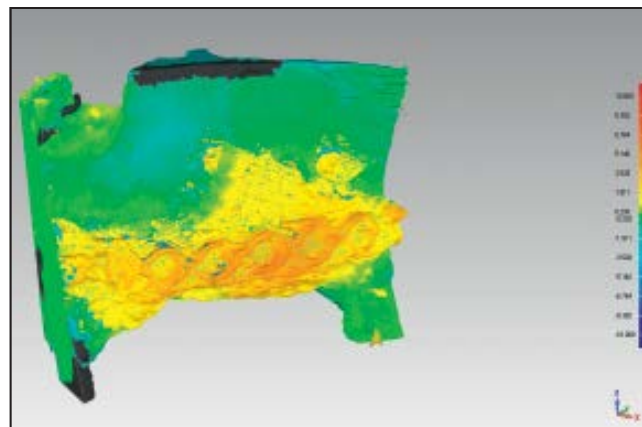
**Fig 11 (left)** Case 2. Stereolithographic model with the osteosynthesis titanium plate. The presurgical assessment confirmed an extremely atrophic edentulous alveolar crest in the maxillary region due to peri-implantitis that evolved into the complete destruction of the supporting bone.

**Fig 12 (right)** Case 2. Two implants inserted in the regenerated area 6 months postsurgery.





**Fig 13** Case 1. Color map. Yellow and red shades represent bone growth.



**Fig 14** Case 5. Color map. Yellow and red shades represent bone growth.

(Geomagic Qualify 12, Geomagic) and superimposed through a best-fit iterative algorithm, using the bone regions outside of the grafted areas as points of reference. After the superimposition, the software calculated the distance between the meshes and generated a color map corresponding to the difference between the presurgery surface (taken as a reference) and the follow-up surface, as well as the numeric values corresponding to this weighted color map. Two representative color maps are presented in Figs 13 and 14.

To calculate a global bone growth volume, the surface corresponding to the graft area was closed along the main patient directions (axial, coronal, and sagittal) in order to obtain a closed volume, and the difference between the presurgery and follow-up was calculated. In addition, the maximum linear augmentation in the vertical direction in millimeters was registered.

After 6 months, a CBCT scan was taken and the horizontal augmentation was measured at the implant positioned most mesially, 2 mm apical to the bone crest.

#### *Histologic evaluation*

In case 1, during the stage-two surgery for implant placement, bone core biopsy specimens corresponding to the regenerated bone areas were harvested using a trephine bur, with a 2-mm outer diameter, under copious irrigation. Bone biopsy specimens were immediately fixed in 10% buffered formalin solution (Sigma Chemical) at 4°C for 24 hours. The specimens were dehydrated in an ascending series of alcohols and embedded in a London White resin (London Resin). After acrylic resin polymerization, specimens were sectioned along their longitudinal axes with a high-precision diamond disk and ground

to approximately 40 mm with a specially designed grinding machine (Micromet, Remet). The non-decalcified ground sections were stained with acid fuchsin and toluidine-blue staining. The slides were observed under normal transmitted light with an optical microscope (Eclipse E800, Nikon).

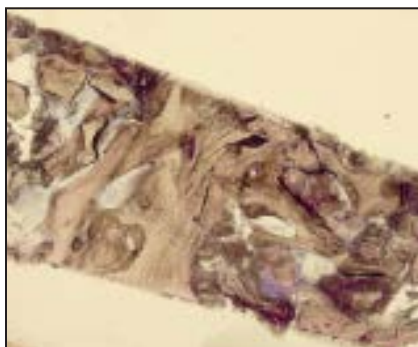
#### *Peri-implant bone level*

Peri-implant marginal bone levels were measured by periapical intra-oral radiographs taken with the parallel technique at implant placement and after 6 months (after a loading time of approximately 4 months). The digitized radiographs were examined using commercially available software (Imagine, Dental Trey). The radiographic measurement was taken from the implant-abutment junction to the most coronal point of bone-to-implant contact. The measurements were made parallel to

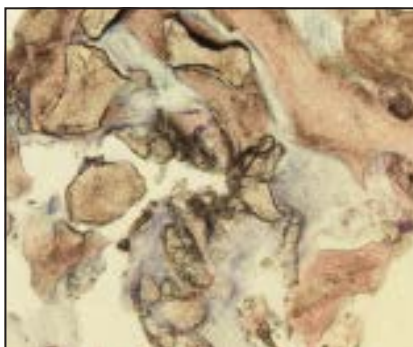
**Table 1** Patient characteristics before and after treatment

Patient	Age (y)	Sex	Smoker	T0 vol (mm <sup>3</sup> )	T1 vol (mm <sup>3</sup> )	Vol diff (mm <sup>3</sup> )	Max lin (mm)	VAS
1	59	F	No	1,928	2,940	1,012	5.87	10
2	62	F	No	943	1,601	658	8.48	10
3	56	M	No	3,296	4,526	1,230	9.10	10
4	65	F	No	4,672	5,526	854	4.87	10
5	36	M	No	2,198	2,579	381	5.85	10
6	20	F	No	1,990	3,573	1,583	6.34	9
Mean	49.7	–	–	2,504.5	3,457.5	953.0	6.75	9.8
SD	17.8	–	–	1,300.3	1,408.5	424.5	1.66	0.4

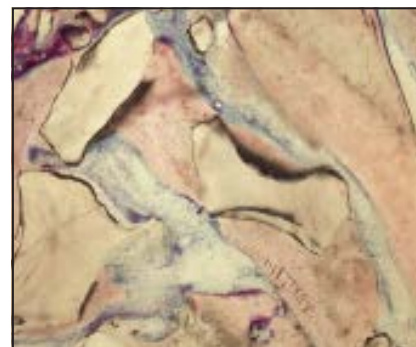
T0 vol = presurgery bone volume; T1 vol = bone volume at 6-month follow-up; vol diff = bone volume difference between T0 and T1; max lin = maximum vertical linear augmentation; VAS = visual analog scale from 0 (strongly dissatisfied) to 10 (very satisfied) administered 12 months postsurgery; F = female, M = male.



**Fig 15** Case 1. Low magnification view of the histologic appearance of the entire bone core biopsy specimen. (Toluidine-blue and acid fuchsin staining; original magnification  $\times 2$ ).



**Fig 16** Case 1. Histologic appearance of the regenerated bone area using particulated autologous bone mixed with deproteinized bovine bone matrix. (Toluidine-blue and acid fuchsin staining; original magnification  $\times 5$ ).



**Fig 17** Case 1. Higher magnification view showing residual grafted particles that were occasionally present and almost completely surrounded by newly formed bone. (Toluidine-blue and acid fuchsin staining; original magnification  $\times 10$ ).

the long axis of the implant fixture along the mesial and distal surface of the implants.

### Statistical analysis

Descriptive statistical analysis was performed at patient level for age, sex, smoking, VAS, volume, maximum linear vertical augmentation, and horizontal augmentation and at implant level for peri-implant marginal bone measures. Means and

SDs were calculated for quantitative variables and frequency for qualitative variables.

### Results

Six patients (2 men and 4 women, nonsmokers, mean age: 49.7 years) were included in this study.

Individual patient data, means, and SDs are reported in Table 1. Bone volume increased from 2,504 presurgically to 3,457 mm<sup>3</sup> at 6

months with a mean augmentation of 953 mm<sup>3</sup>. The mean maximum linear augmentation in the vertical direction was 6.75 mm. Mean horizontal augmentation was 9.23 mm (SD: 1.80 mm).

Representative histologic views of case 1 are shown in Figs 15 to 17. Results of the histologic analysis of bone core biopsy specimens obtained from the regenerated area after 6 months revealed the presence of a homogenous and compact bone substrate idoneous for

implant placement. The regenerated portion was mainly represented by areas of bone remodeling with spotted regions where grafted particles were detectable after 6 months (Figs 15 to 17). The overall appearance showed the presence of compact newly formed bone surrounded by marrow spaces containing newly formed vessels, indicating intense angiogenesis activity (Fig 17). All histologic sections showed no sign of inflammation.

At the reentry surgery, 13 implants were inserted (3 implants in case 3 and 2 implants in the other cases). The mean length of the implants was 10.2 mm (range: 6.5 to 14 mm), and the diameter was 4.5 mm. The mean insertion torque was 32.5 Ncm (range: 25 to 40 Ncm). At implant placement, marginal bone level was 0.94 mm (SD: 0.45 mm). After 6 months, the mean  $\pm$  SD marginal bone level was  $1.30 \pm 0.54$  mm with a marginal bone loss of  $0.36 \pm 0.31$  mm.

Twelve months after surgery, the patients were asked to express their degree of satisfaction with the procedure. VAS scores are reported in Table 1. All patients rated the maximum score except case 6.

During the entire procedure no complications were observed.

## Discussion

The technique described has been applied to atrophied edentulous regions as a two-stage procedure. The six cases presented showed positive outcomes, resulting in a substantial reconstruction of the alveolar

crest deficiencies and allowing for successful implant placement.

The mean bone growth was 953 mm<sup>3</sup> in volume and 6.75 mm in maximum vertical augmentation without complications. In addition, the patients perceived the procedure favorably.

A successful outcome of GBR requires the fulfillment of certain biologic principles: wound stabilization, exclusion of competing tissue, and space maintenance.<sup>31</sup> The use of osteosynthesis titanium plates with bone grafting and resorbable barriers for ridge augmentation has been described previously with excellent results.<sup>20</sup>

The original fence technique applied a resorbable osteosynthesis plate, made of poly-DL-lactic acid (PDLLA), which was fixed using specific bioresorbable PDLLA pins.<sup>25</sup> In this modified localized fence technique, a nonresorbable titanium osteosynthesis plate is used. The titanium osteosynthesis is thinner and narrower than the resorbable plate; hence, in a localized defect it can perfectly adapt to the residual ridge concavity. In addition, the cost of the procedure is reduced when treating a localized sextant, although this technique requires stereolithography and the use of specific devices that may increase the overall costs.

In the present study, the newly formed bone was well organized, and after 6 months, the histologic analyses revealed the presence of a homogenous and compact bone substrate mainly characterized by newly formed bone where spotted regions of residual grafted bone particles were detectable.

The fence technique seems to be a favorable option in cases of atrophied edentulous regions compared to alternative and more invasive solutions, such as the use of onlay bone grafts harvested from extraoral donor sites or the use of zygomatic implants. However, the clinical cases presented were carried out by a surgeon experienced in GBR, and it is unclear whether these results can be attained by less experienced operators.

## Conclusions

The results of these case reports are very promising. The fence technique has proven to be safe and reliable, although randomized controlled trials are needed to validate the effectiveness of this procedure.

## Acknowledgments

The authors express their deepest appreciation to Heather Dawe and Marco Bonfini for editing the manuscript. The authors reported no conflicts of interest related to this study.

## References

1. Esposito M, Grusovin MG, Felice P, Karatzopoulos G, Worthington HV, Coulthard P. Interventions for replacing missing teeth: Horizontal and vertical bone augmentation techniques for dental implant treatment. *Cochrane Database Syst Rev* 2009;(4):CD003607.
2. Chiapasco M, Romeo E, Casentini P, Rimondini L. Alveolar distraction osteogenesis vs. vertical guided bone regeneration for the correction of vertically deficient edentulous ridges: A 1–3-year prospective study on humans. *Clin Oral Implants Res* 2004;15:82–95.



3. Cannizzaro G, Leone M, Consolo U, et al. Augmentation of the posterior atrophic edentulous maxilla with implants placed in the ulna: A prospective single-blind controlled clinical trial. *Int J Oral Maxillofac Implants* 2007;22:280–288.
4. Chiapasco M, Zaniboni M, Rimondini L. Autogenous onlay bone grafts vs alveolar distraction osteogenesis for the correction of vertically deficient edentulous ridges: A 2–4-year prospective study on humans. *Clin Oral Implants Res* 2007;18:432–440.
5. Bianchi A, Felice P, Lizio G, Marchetti C. Alveolar distraction osteogenesis versus inlay bone grafting in posterior mandibular atrophy: A prospective study. *Oral Surg Oral Med Oral Pathol Oral Radiol Endod* 2008;105:282–292.
6. Felice P, Marchetti C, Piattelli A, et al. Vertical ridge augmentation of the atrophic posterior mandible with interpositional block grafts: Bone from the iliac crest versus bovine anorganic bone. *Eur J Oral Implantol* 2008;1:183–198.
7. Fontana F, Santoro F, Maiorana C, Iezzi G, Piattelli A, Simion M. Clinical and histologic evaluation of allogeneic bone matrix versus autogenous bone chips associated with titanium-reinforced e-PTFE membrane for vertical ridge augmentation: A prospective pilot study. *Int J Oral Maxillofac Implants* 2008;23:1003–1012.
8. Rocchietta I, Fontana F, Simion M. Clinical outcomes of vertical bone augmentation to enable dental implant placement: A systematic review. *J Clin Periodontol* 2008;35(suppl 8):203–215.
9. Nystrom E, Nilson H, Gunne J, Lundgren S. A 9–14 year follow-up of onlay bone grafting in the atrophic maxilla. *Int J Oral Maxillofac Surg* 2009;38:111–116.
10. Cricchio G, Lundgren S. Donor site morbidity in two different approaches to anterior iliac crest bone harvesting. *Clin Implant Dent Relat Res* 2003;5:161–169.
11. Kourkouta S, Dedi KD, Reside G, Kontogeorgakos V. Heterotopic ossification as a complication of iliac crest bone harvesting in a case of implant therapy. *Int J Oral Maxillofac Implants* 2009;24:353–358.
12. Szabó G, Huys L, Coulthard P, et al. A prospective multicenter randomised clinical trial of autogenous bone versus beta-tricalcium phosphate graft alone for bilateral sinus elevation: Histologic and histomorphometric evaluation. *Int J Oral Maxillofac Implants* 2005;20:371–381.
13. Cordaro L, Amadé DS, Cordaro M. Clinical results of alveolar ridge augmentation with mandibular block bone grafts in partially edentulous patients prior to implant placement. *Clin Oral Implants Res* 2002;13:103–111.
14. Felice P, Marchetti C, Iezzi G, et al. Vertical ridge augmentation of the atrophic posterior mandible with interpositional block grafts: Bone from the iliac crest vs bovine anorganic bone. Clinical and histological results up to one year after loading from a randomized-controlled clinical trial. *Clin Oral Implants Res* 2009;20:1386–1393.
15. Cordaro L, Torsello F, Miuccio MT, di Torresanto VM, Eliopoulos D. Mandibular bone harvesting for alveolar reconstruction and implant placement: Subjective and objective cross-sectional evaluation of donor and recipient site up to 4 years. *Clin Oral Implants Res* 2011;22:1320–1326.
16. Clementini M, Morlupi A, Canullo L, Agrestini C, Barlattani A. Success rate of dental implants inserted in horizontal and vertical guided bone regenerated areas: A systematic review. *Int J Oral Maxillofac Surg* 2012;41:847–852.
17. Simion M, Trisi P, Piattelli A. Vertical ridge augmentation using a membrane technique associated with osseointegrated implants. *Int J Periodontics Restorative Dent* 1994;14:496–511.
18. Zitzmann NU, Naef R, Schärer P. Resorbable versus nonresorbable membranes in combination with Bio-Oss for guided bone regeneration. *Int J Oral Maxillofac Implants* 1997;12:844–852.
19. Simion M, Jovanovic SA, Tinti C, Benfenati SP. Long-term evaluation of osseointegrated implants inserted at the time or after vertical ridge augmentation. A retrospective study on 123 implants with 1–5 year follow-up. *Clin Oral Implants Res* 2001;12:35–45.
20. Merli M, Bernardelli F, Esposito M. Horizontal and vertical ridge augmentation: A novel approach using osteosynthesis microplates, bone grafts, and resorbable barriers. *Int J Periodontics Restorative Dent* 2006;26:581–587.
21. Merli M, Migani M, Esposito M. Vertical ridge augmentation with autogenous bone grafts: Resorbable barriers supported by osteosynthesis plates versus titanium-reinforced barriers. A preliminary report of a blinded, randomized controlled clinical trial. *Int J Oral Maxillofac Implants* 2007;22:373–382.
22. Merli M, Lombardini F, Esposito M. Vertical ridge augmentation with autogenous bone grafts 3 years after loading: Resorbable barriers versus titanium-reinforced barriers. A randomized controlled clinical trial. *Int J Oral Maxillofac Implants* 2010;25:801–807.
23. Cordaro L, Torsello F, Morcavallo S, di Torresanto VM. Effect of bovine bone and collagen membranes on healing of mandibular bone blocks: A prospective randomized controlled study. *Clin Oral Implants Res* 2011;22:1145–1150.
24. Urban IA, Jovanovic SA, Lozada JL. Vertical ridge augmentation using guided bone regeneration (GBR) in three clinical scenarios prior to implant placement: A retrospective study of 35 patients 12 to 72 months after loading. *Int J Oral Maxillofac Implants* 2009;24:502–510.
25. Merli M, Moscatelli M, Mariotti G, Rotundo R, Nieri M. Autogenous bone versus deproteinised bovine bone matrix in 1-stage lateral sinus floor elevation in the severely atrophied maxilla: A randomised controlled trial. *Eur J Oral Implantol* 2013;6:27–37.
26. Renouard F, Nisand D. Impact of implant length and diameter on survival rates. *Clin Oral Implants Res* 2006;17(suppl 2):35–51.
27. Ridell A, Gröndahl K, Sennerby L. Placement of Brånemark implants in the maxillary tuber region: Anatomical considerations, surgical technique and long-term results. *Clin Oral Implants Res* 2009;20:94–98.
28. Felice P, Soardi E, Pellegrino G, et al. Treatment of the atrophic edentulous maxilla: Short implants versus bone augmentation for placing longer implants. Five-month post-loading results of a pilot randomised controlled trial. *Eur J Oral Implantol* 2011;4:191–202.
29. Merli M. Implant Therapy. The Integrated Treatment Plan. Vol 1: Diagnosis and Surgical Therapy. Milan: Quintessenza, 2013;369–371.
30. Triaca A, Minoretti R, Merli M, Merz B. Periosteoplasty for soft tissue closure and augmentation in preprosthetic surgery: A surgical report. *Int J Oral Maxillofac Implants* 2001;16:851–856.
31. Kostopoulos L, Karring T. Guided bone regeneration in mandibular defects in rats using a bioresorbable polymer. *Clin Oral Implants Res* 1994;5:66–74.