

DENTAL TECHNIQUE

Sealing maxillary titanium obturators with removable flexible caps



Bernd Reitemeier, Dr med dent habil,^a Wolfgang Schaal,^b Annette Wolf, Dr med dent,^c and Michael Walter, Dr med dent^d

Obturator prostheses are commonly provided by maxillofacial prosthodontists. As changes may occur continuously in the defect area after resection, the peripheral seal of the obturator prosthesis is frequently unstable.¹ Consequently, food and liquid may leak from the nasal opening during eating.² The patient's phonetic functionality can be adversely affected and severely impaired^{3,4} and changes due to cicatricial contraction are frequently observed.⁵ Extensive modifications of the obturator and renewal of the entire prosthesis are repeatedly required.

Various materials and methods of attaching the obturator part to the prosthesis have been suggested to improve the functionality of obturator prostheses.⁶ It is particularly important that obturator prostheses for the maxilla are lightweight.⁷ Using biocompatible titanium is practical to reduce weight, as indicated by Fritzemeier and Kruchen.⁸ They designed a hollow titanium obturator with a wall thickness of 0.3 to 0.7 mm. Habib and Driscoll⁹ reported a weight reduction of up to 30% when titanium was used. However, the rigidity of titanium prevents using undercuts for improving retention. Should contractions occur, these frequently lead to sore spots and ulceration.⁵ Necessary adjustments may result in the perforation of a metallic hollow obturator. Repairs are complicated or impossible. The following procedure is proposed to prevent these problems. Figure 1 shows the initial clinical situation.

ABSTRACT

Maxillary obturator prostheses with hollow metal obturators can be made of titanium to reduce weight. To prevent perforation of the hollow obturator during modifications, the obturator is slightly undersized and covered with a replaceable cap. This cap is made of a soft copolymer to facilitate uncomplicated modifications in the resection area and to improve function. (*J Prosthet Dent* 2016;115:381-383)

TECHNIQUE

1. Make a definitive cast. Use a half round wax profile (casting wax 4.0×2.0 mm, 111-314-00; Dentaaurum) to preform a circular retention groove at the obturator part.
2. After duplication, wax the framework using conventional casting wax (Fig. 2).
3. Fabricate the framework and a lid for closing the hollow obturator in titanium. Use a vacuum pressure casting system for titanium casting (Dor-A-Matic Ti; Schütz Dental). Use Class 1 unalloyed pure titanium and a sufficient amount of casting material (more than 30 g).
4. Remove the investment material and check evaluate the quality of the cast regarding voids using an x-ray device with 60 kV and 0.01 mAs (Heliodent; Sirona Dental Systems).
5. Polish the metal parts (Fig. 3).
6. Close the hollow obturator with the cast titanium lid by laser welding (Connexion; Degussa).
7. Determine the maxillomandibular relationship in the usual manner.
8. Conduct a trial placement on the patient.

^aProfessor, Department of Prosthetic Dentistry, University Hospital, Dresden University of Technology, Dresden, Germany.

^bDental Technician, Department of Prosthetic Dentistry, University Hospital, Dresden University of Technology, Dresden, Germany.

^cStaff Dentist, Department of Prosthetic Dentistry, University Hospital, Dresden University of Technology, Dresden, Germany.

^dProfessor and Head, Department of Prosthetic Dentistry, University Hospital, Dresden University of Technology, Dresden, Germany.

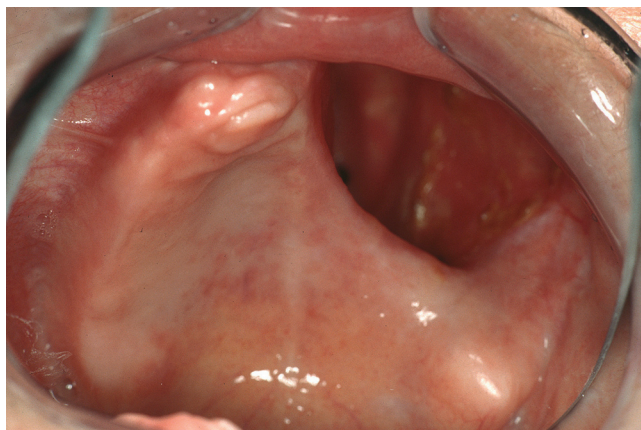

Figure 1. Maxillary defect after extensive tumor surgery.

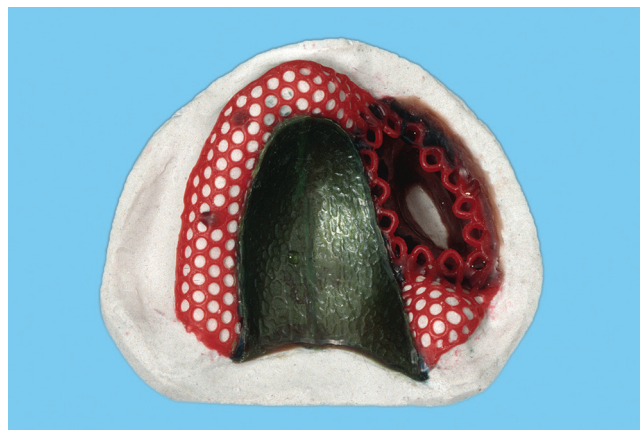


Figure 2. Waxed framework.



Figure 3. Polished titanium framework. Note circular retention groove resulting from use of half round wax profile.

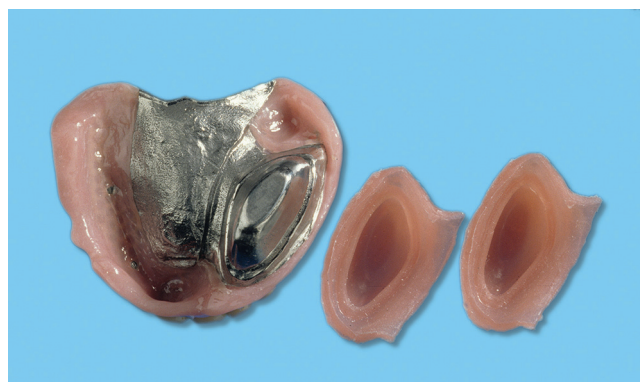

Figure 4. Obturator prosthesis with 2 flexible caps from intaglio. Hollow obturator completed with cast titanium lid.

9. Process the prosthesis as usual in a hard denture base resin (Paladon; Heraeus Kulzer GmbH).
10. Make an impression of the resection cavity with a condensation silicone (Optosil P Plus; Heraeus Kulzer GmbH).
11. Pour the cast
12. Shape the obturator cap in modeling wax.
13. Process the obturator cap in a soft copolymer (Flexor; Schütz Dental). The thickness should be approximately 5 mm (Figs. 4, 5).

DISCUSSION

In contrast with solid or hollow obturators made exclusively of denture base resin,^{5,9,10} the use of titanium facilitates the fabrication of stable and biocompatible obturator prostheses. The biggest advantage is weight reduction because of the low density of titanium. A further advantage is the option of quality control by inspecting the titanium cast for voids using an x-ray device. Soft tissue changes in the resected area as cicatrices, tissue shrinkages, and neoformations can be easily compensated with corrections on the replaceable cap

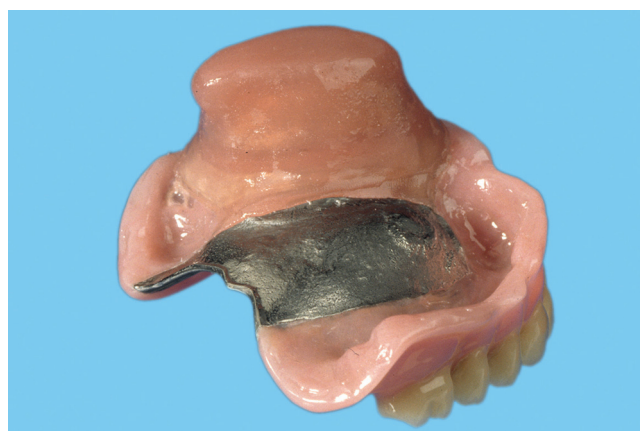

Figure 5. Obturator prosthesis with flexible cap attached. Interface between hard denture base resin and soft cap is clearly visible.

made of a soft copolymer. This material exhibits a high tensile strength (more than 4 MPa) and good elasticity,¹¹ with a Shore hardness of 39 and a water absorption of 0. A replacement maxillary obturator prosthesis is required considerably less frequently than with other methods

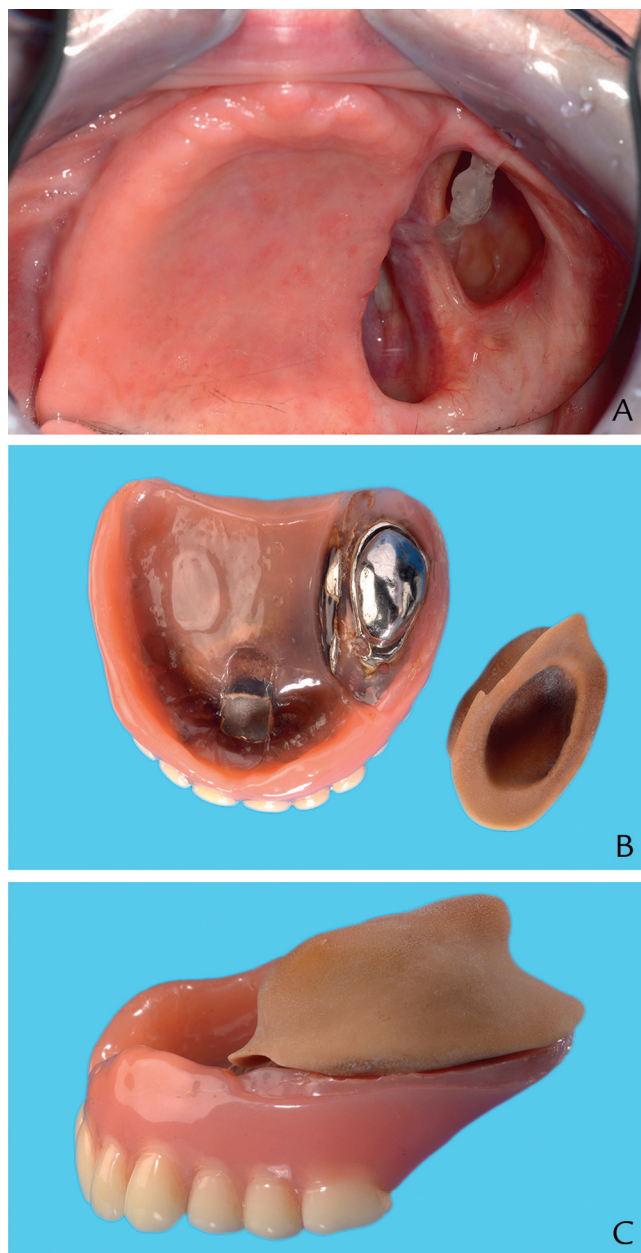


Figure 6. Obturator prosthesis after 19 years of function. One relining. In this prosthesis, flexible cap is still original. A, Defect. B, Denture base with (discolored) flexible cap detached. C, Denture and cap assembled.

(Fig. 6). Patients can remove the flexible cap themselves and minimize bacterial contamination by boiling the cap (for example, immersing it in tap water at a rolling boil for 10 minutes). In order to prevent the patient from being without a functioning prosthesis, an additional second cap is fabricated. During function, the removable cap is securely fixed through the circular retention groove in the

titanium part of the obturator. Fabricating the cap from the soft copolymer permits the extension in undercuts of the resection area. They can be frequently found in the area of the former facial and posterior walls of the maxillary sinus. This enhances the anchoring of maxillary obturator prostheses, particularly in edentulous patients. The improved retention and better sealing between the resection cavity and the obturator prosthesis also considerably improves the patient's masticatory function, phonetic functionality and quality of life.^{4,12} When indicated, a part of the flexible cap can be individually extended to support the cheek. Further improvements in retention and stability of obturator prostheses can be achieved by using intraoral implants.¹³

REFERENCES

1. Wang RR, Hirsch RF. Refining hollow obturator base using light-activated resin. *J Prosthet Dent* 1997;78:327-9.
2. Reitemeier B, Unger M, Richter G, Ender B, Range U, Markwardt J. Clinical test of masticatory efficacy in patients with maxillary/ mandibular defects due to tumors. *Onkologie* 2012;35:170-4.
3. Rieger J, Wolfaardt J, Seikaly H, Jha N. Speech outcomes in patients rehabilitated with maxillary obturator prostheses after maxillectomy: a prospective study. *Int J Prosthodont* 2002;15:139-44.
4. Müller R, Höhle A, Wolf A, Markwardt J, Schulz MC, Range U, et al. Evaluation of selected speech parameters after prosthesis supply in patients with maxillary or mandibular defects. *Onkologie* 2013;36:547-52.
5. Jacob RF. Clinical management of the edentulous maxillectomy patient. In: Taylor TD, editor. *Clinical maxillofacial prosthetics*. Chicago: Quintessence Publishing; 2000. p. 85-102.
6. Parr GR, Gardner LK. The evolution of the obturator framework design. *J Prosthet Dent* 2003;89:608-10.
7. Wu YL, Schaaf NG. Comparison of weight reduction in different designs of solid and hollow obturator prostheses. *J Prosthet Dent* 1989;62:214-7.
8. Fritzemeier CU, Kruchen LC. The temporary and definitive compensation of maxillary defects. In: Schwipperf V, editor. *Proceedings of the Congress of International Association of Surgery Prosthetics and Epithetics*. Münster: International Association of Surgery Prosthetics and Epithetics; 2006. p. 106-17.
9. Habib BH, Driscoll CF. Fabrication of a closed hollow obturator. *J Prosthet Dent* 2004;91:383-5.
10. McCord JF, Michelinakis G. Systematic review of the evidence supporting intra-oral maxillofacial prosthodontic care. *Eur J Prosthodont Rest Dent* 2004;12:129-35.
11. Reitemeier B, Schmidt A, Richter G, Schowtka L, Techritz K. Results of the experimental study of Elasto-Synsil 30 and Episil E. *J Facial Somato Prosthet* 1998;4:119-22.
12. Knipfer C, Riemann M, Bocklet T, Noeth E, Schuster M, Sokol B, et al. Speech intelligibility enhancement after maxillary denture treatment and its impact on quality of life. *Int J Prosthodont* 2014;27:61-9.
13. Parel SM, Branemark PI, Ohnells LO, Svensson B. Remote implant anchorage for the rehabilitation of maxillary defects. *J Prosthet Dent* 2001;86:377-81.

Corresponding author:

Dr Michael Walter
Department of Prosthetic Dentistry
University Hospital
Dresden University of Technology
Fetscherstrasse 74
D-01307 Dresden
GERMANY
Email: Michael.Walter@uniklinikum-dresden.de

Copyright © 2016 by the Editorial Council for *The Journal of Prosthetic Dentistry*.