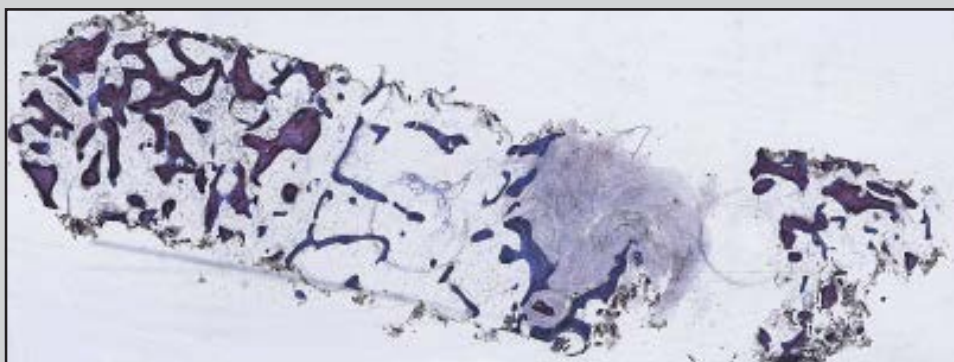
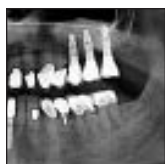
Fate of a Bovine-Derived Xenograft in Maxillary Sinus Floor Elevation After 14 Years: Histologic and Radiologic Analysis



Mustafa Ayna, DDS PhD, MSc¹

Yahya Açı, Prof Dr Rer Nat²

Aydin Gulses, DDS PhD³

This report assesses the results following sinus floor augmentation performed 14 years previously in which bovine bone xenograft material was used without implant insertion. After sinus floor augmentation, using a 20:80 mixture of autogenous bone and inorganic bovine bone material (Bio-Oss), bone biopsy specimens were taken from the grafted site, processed with Donath's sawing and grinding technique, stained with toluidine blue, and mounted on high-sensitivity plates for histology and microradiography. Histologic and microradiographic analysis showed the ingrowth of newly formed bone into the graft with interspersed residual Bio-Oss granules. The percentage of Bio-Oss and newly formed bone was 10.18% and 9.32%, respectively, within a total surface area of 70.61 mm² at the site of the corresponding missing first molar, and the percentage of Bio-Oss and newly formed bone was 11.47% and 14.96%, respectively, within a total surface area of 63.92 mm² at the corresponding missing second molar. The newly formed bone was vital without signs of resorption. This study produced strong evidence that newly formed bone was distributed throughout the bone substitute material around all of its granules and that the grafted site consisted of vital bone even in its central parts. The differences in degradation rate and/or whether the effect of bone graft substitutes alone and/or in combination with other types, shapes, and sizes of graft materials needs further clinical investigation, especially in regard to long-term changes. (Int J Periodontics Restorative Dent 2015;35:541–547. doi: 10.11607/prd.2135)

¹Lecturer, Ruhr University Bochum, Bochum, Germany, and Danube University Krems, Krems, Austria.

²Professor, Department of Oral and Maxillofacial Surgery, Christian-Albrechts-University, Kiel, Germany.

³Associate Professor, Center for Dentistry and Oral Health, Mevki Military Hospital, Ankara, Turkey.

Correspondence to: Dr Aydin Gulses, Mevki Military Hospital, 06130 Diskapi Altindag, Ankara, Turkey; fax: +903123114609; email: aydingulses@gmail.com.

©2015 by Quintessence Publishing Co Inc.

Decreases in height and width of the residual crest following tooth extraction usually necessitate the use of additional augmentation techniques prior to endosseous dental implant placement. In the posterior maxilla, pneumatization of the maxillary sinus often results in an additional loss of residual bone volume, and various sinus floor augmentation techniques with different grafting materials are usually needed.^{1–5}

Among these grafting materials, different biocompatible and osteoconductive bone substitutes were developed and successfully marketed by various manufacturers in the past 30 years to reduce the need for autogenous bone, which is accepted as the gold standard, owing to its outstanding biologic behavior and high survival rates.⁶

The healing period following maxillary sinus bone grafting depends on the amount of pneumatization, residual bone volume, patient-related factors, and type of graft material used. If autogenous bone is used, the healing time can be shortened (by approximately 4 months). However, in cases when bone substitutes are used, longer healing periods would be prudent.^{2–4}

There are numerous articles in the literature evaluating the survival rates of implants placed in grafted maxillary sinuses. A systematic literature review confirmed

the positive early results reported for xenografts.⁷ In addition, the survival rates of implants placed in sinuses grafted with 100% inorganic bovine bone xenografts were found to be higher than those in grafts of 100% bone material harvested from the iliac crest (95.6% and 88.0%, respectively). However, in sinuses grafted with 100% allografts, the survival rates were relatively poor (81.0%).⁸

Bovine bone xenograft is a reliable bone graft substitute and reportedly exhibits high survival rates in maxillary sinus augmentation procedures.^{9–14} Bovine bone graft substitutes promote both the formation and ingrowth of newly formed bone and blood vessels at the grafted site. The trabecular bone serves as a scaffold for osteoblasts and promotes osteoblast differentiation as well as matrix synthesis.¹⁵ Bio-Oss (Geistlich) is a well-established deproteinized bovine bone xenograft with high osteoconductive potential.^{16,17} Its high-porosity structure provides an extensive internal surface area of 79.7 m²/g, which is similar to the natural bone contact surface area.¹⁸ In addition, Bio-Oss has a calcium phosphate index of 2.03, which precisely matches the index of natural human bone, ie, 2.03.¹⁹

Despite the increasing numbers of articles that have evaluated different bone graft materials in implant surgery, the clinical relevance of factors such as differences in degradation rate and/or whether the effect of bone graft substitutes alone and/or in combination with other types, shapes,

and sizes of graft materials needs further clinical investigation, especially with respect to long-term changes.

The aim of this report was to assess the results following sinus floor augmentation performed 14 years ago with Bio-Oss bone graft material.

Method and materials

In 1997, a 51-year-old healthy male patient presented with complaints of difficulty chewing due to his removable maxillary partial denture. He wanted a fixed restoration, so an implant-supported prosthesis was proposed. However, the radiographic examination revealed high-grade bone loss in the left posterior maxilla; therefore, sinus floor elevation with bone grafting prior to implant placement was planned.

Autogenous bone harvested from the retromolar mandible combined with a granular bone substitute with a granule size of 0.25 to 1 mm (Bio-Oss) was selected for grafting.

A palatal crestal incision was made, mesial and distal releasing incisions were performed, and a full-thickness mucoperiosteal flap was elevated. The lateral sinus wall was exposed and a 3 × 2-cm cortical bone flap was raised via a diamond round bur without damaging the sinus membrane. The bone flap was carefully released from the sinus wall and pushed inward and upward. The sinus membrane remained intact, and the sinus floor was augmented with a material

consisting of a 20:80 mixture of autogenous bone and granular bone substitute. The grafted sinus floor was covered with a Bio-Gide membrane (Geistlich) and secured with three titanium screws (Fig 1). The surgical field was primarily closed via 3-0 silk sutures.

Because the patient spent a long time abroad, implant placement was delayed for 14 years. In 2011, diagnostic computed tomography scans (CT) were obtained (Fig 2). Three implants were placed (Nobel Replace 4.3 × 13.0 mm, Nobel Biocare) at the grafted site (Fig 3). During implant insertion, bone was harvested from the originally grafted sites with a trephine bur for histologic examination.

Sample processing, sawing, and grinding

The samples were placed in 10% formalin for 10 days. Using an automatic processing station (Pool of Scientific Instruments [PSI]), the samples were embedded in methacrylate prior to sawing and grinding. The processing station was programmed for dehydration in an ascending series of alcohol, defatting in acetone and embedding in methacrylate.

Sawing and grinding were performed,^{20,21} and the samples were placed in glass vessels filled with a monomeric resin solution and incubated at 37°C to 40°C for 2 to 4 days for resin impregnation. The samples were precut with a band saw (Exakt), and disks of about 100 µm were obtained via an oscillat-

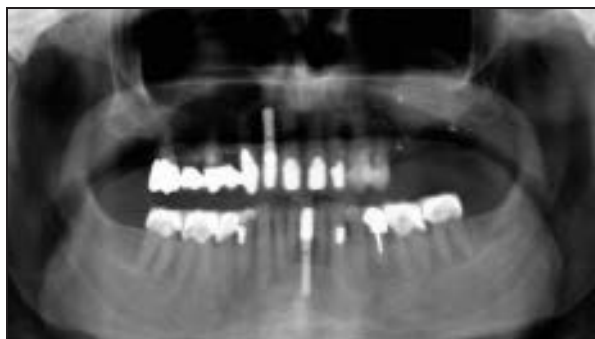

Fig 1 Panoramic radiograph of the patient 14 years after the grafting procedure.

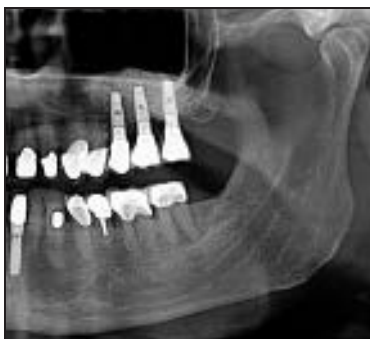

Fig 2 Implants were placed in maxillary left second premolar and first and second molars, and single crowns were cemented onto them.

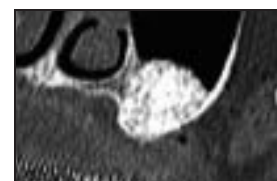

Fig 3 Computed tomography image of the grafted site. Note that the sinus is well pneumatized and the graft is stable.

ing diamond saw (Exakt), grounded with the Saphir 360 E grinder (ATM), and highly polished with silicon carbide paper (grades 500, 1,200, 2,400, and 4,000).

Staining

Stainings were made with toluidine. The ground surface was decalcified with 0.1% formic acid, and 20% methanol was applied for better cell and soft tissue staining. The samples were rinsed in distilled water and stained in a toluidine blue solution for 2 minutes.

In this process, hard tissue either did not stain or at best assumed a light blue color, whereas cells and their nuclei, osteoid, cement lines, and collagen fibers stained blue, and mast cell granules, cartilage matrix, and early wound healing sites metachromatically stained red violet.

Microradiography

The samples were glued onto film-coated, light-sensitive glass high-resolution plates (HRP; Type 1A, Imtek)—depending on their thickness—and exposed to 18 kV and 5 mA for 8 to 10 minutes in the microradiography chamber (Faxitron X-ray Systems 43855A, Hewlett Packard). The films were developed with an HRP developer and fixed in an A3000 fixation bath (both by Kodak). After drying, the sensitive film layer was covered with a cover plate and mounted with Eukitt. The microradiographs were morphometrically evaluated using a digital image analyzer (Q500MC, Leica). A measuring frame was placed on invariably identifiable screw holes, and the surface area of newly formed bone was measured.

The microradiographs provided information regarding the mineralization of the bone formed

following the augmentation procedure, which is less well mineralized and appears relatively darker compared to the original, mature mineralized bone. Information was obtained regarding the structure and extent of the newly formed bone.

Results

Histologic analysis of ground sections and three-dimensional (3D) radiography produced the following evidence:

- 3D radiography of the grafted site showed that the original bone at the prospective implant site was stable 14 years postgrafting without signs of resorption (see Fig 2).
- No irregularities or perforations were seen at the surface facing the maxillary sinus.

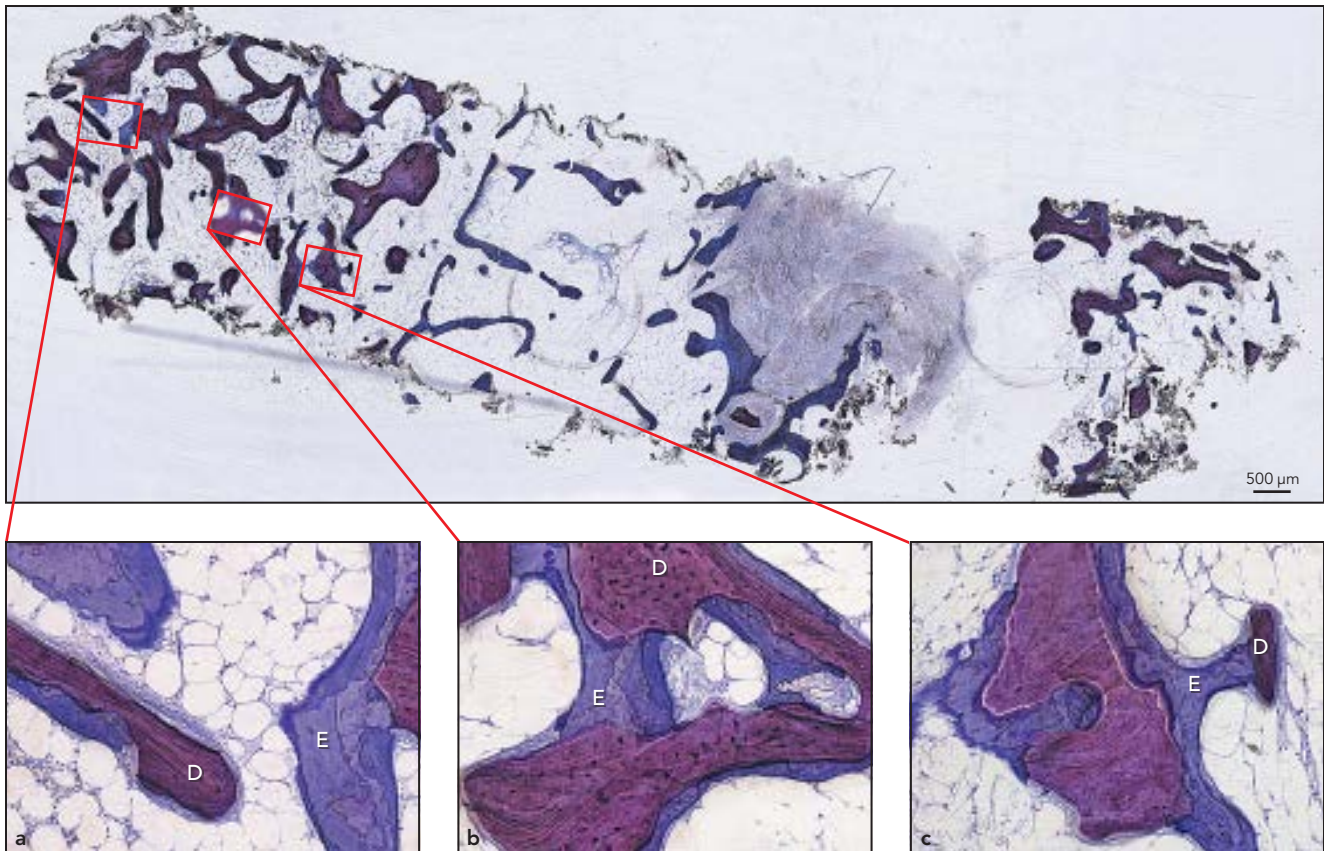


Fig 4 Overview of intact biopsy specimen taken at the first molar. Note the maturing vital bone with well-developed trabeculae and fibrous bone with nonresorbed Bio-Oss granules. (a, b) Detailed view of biopsy specimen. Note that the grafting material (D) is completely embedded in bone (E). The newly formed bone uses Bio-Oss as a scaffold for interlinking. (c) Dense mature lamellar bone (E) has ensheathed a large Bio-Oss granule (D) and sends a trabecular bridge to a smaller Bio-Oss granule.

- Histologic analysis of the toluidine blue-stained samples showed that nonresorbed residues of the Bio-Oss granules were still present 14 years after sinus floor elevation (Fig 4).
- No signs of resorption were detected even after the long postgrafting time, and the bone was clear of inflammation. The trabeculae at the examined site were separated by large voids (see Fig 4).
- Bio-Oss acted as a scaffold, and mature fibrous bone formed trabeculae, which assembled to an interlinked trabecular structure (see Fig 4).
- The histologic examination revealed that the grafted site consisted of vital bone even in its central parts. The Bio-Oss granules were embedded in this bone tissue without causing any irritations but failed to show signs of resorption histologically 14 years postgrafting.
- Microradiography confirmed the high percentage of Bio-Oss (10.18%) at the site of the corresponding missing maxillary left first molar; while the amount of newly formed bone was slightly lower (9.32%) (Fig 5).
- At the site of the corresponding maxillary left second molar, newly formed bone exceeded the amount of Bio-Oss (14.96% and 11.47%, respectively; Fig 6).

Fig 5 Microradiograph of the first molar showing 9.32% natural bone (E) and 10.18% Bio-Oss (D) within a total surface area of 70.61 mm².


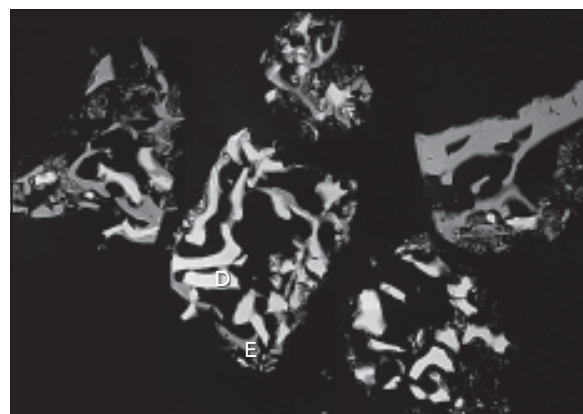


Fig 6 Microradiograph of the second molar showing 14.96% natural bone (E) and 11.47% Bio-Oss (D) within a total surface area of 63.92 mm².



Discussion

Bone regeneration in the maxillary sinus grafted with bovine bone xenograft was studied qualitatively and quantitatively at variable time points postgrafting.^{22,23} According to the literature, the sinus graft incorporation could be estimated at about 1.0 mm per month with deproteinized bovine bone xenograft. The present case study aimed to clarify the percentage of vital bone and inorganic bovine bone material 14 years following the sinus grafting procedure.

The amount of vital bone formed in the sinus after a certain time is a variable for the compara-

tive assessment of the healing and osteoconduction potential of grafting or bone substitute materials. It also has been reported that the graft maturation could be determined by assessing the vital new bone formation.^{24,25} Using inorganic bovine bone material with and without autogenous bone for sinus grafting, Froum et al evaluated the amount of vital bone and reported a mean volume of 24% after 6 to 9 months and 33% after 12 to 15 months.²⁶ Valentini et al examined maxillary sinuses grafted with 100% inorganic bovine bone material and found that vital bone represented 18.3% mean volume at the end of 6 months and 26.6% at the end of

12 months.²⁷ In the current study, the histologic examination revealed that the grafted site consisted of vital bone even in its central parts. In addition, a high percentage of Bio-Oss (10.18%) was found at the site of the corresponding missing maxillary first molar, whereas the amount of newly formed bone was slightly lower (9.32%). At the site of the corresponding maxillary second molar, newly formed bone exceeded the amount of Bio-Oss (14.96% and 11.47%, respectively).

In a histologic study performed by Artzi et al, the amount of newly formed bone was found to vary significantly as a function of the graft location: In the cranial parts

of the graft, increasingly less new bone was formed, whereas more new bone was present in the parts close to the sinus membrane.⁸ This was not confirmed by the samples evaluated for the present study. Conversely, newly formed bone was distributed throughout the bone substitute material around all of its granules.

A histologic long-term study over 11 years failed to show any statistically significant changes in the particle size of inorganic bovine bone material and showed a 17% increase of a mean bovine bone matrix.²⁸ In another 11-year study, little new bone had formed and bovine bone matrix was found to have resisted resorption.²³ As the biopsy specimen material available for these two studies was limited, the evidence obtained on the distribution of newly formed bone and its ingrowth into the graft is bound to be inconclusive. In addition, the percentage of new bone should be reviewed critically; thus, normal nongrafted local bone also could be present at the biopsy specimen site.^{23,28} For the current study, two samples of about 70 mm² in size were available. These can be expected to provide an adequate cross section of the sinus graft.

Schulten et al²⁹ suggested that graft materials with a very low resorption rate will not remodel and, therefore, will not functionally adapt to surrounding bone, which might result in negative mechanical cues. Slow or even a lack of resorption of graft material prevents its replacement by new bone, which may hamper proper and timely bone-to-

dental implant interface formation. This may result in lower implant survival. It also has been stated that Bio-Oss degrades very slowly³⁰ and no clinical signs of resorption are seen up to 6 years postgrafting.²¹ The current study showed that nonresorbed residues of Bio-Oss granules were still present 14 years after sinus floor elevation. This might be attributed to a slow osteoclast-mediated resorption rather than spontaneous resorption.

Conclusions

This study produced strong evidence showing that newly formed bone was distributed throughout the bone substitute material around all of its granules and that the grafted site consisted of vital bone even in its central parts. In addition, Bio-Oss granules had not been completely resorbed, even after 14 years in situ.

In the authors' opinion, the differences in degradation rate and/or whether the effect of bone graft substitutes alone and/or in combination with other types, shapes, and sizes of graft materials needs further clinical investigation, especially with respect to long-term changes.

Acknowledgments

The authors reported no conflicts of interest related to this study.

References

1. Jensen OT, Schulman LB, Block MS, Iacono VJ. Report of the Sinus Consensus Conference of 1996. *Int J Oral Maxillofac Implants* 1998;13:11–45.
2. Lazzara RJ. The sinus elevation procedure in endosseous implant therapy. *Curr Opin Periodontol* 1996;3:178–183.
3. Brånemark PL, Zarb GA, Albrektsson T. *Tissue-Integrated Prostheses*. Chicago: Quintessence, 1985:241–282.
4. Misch CE, Judy KW. Classification of partially edentulous arches for implant dentistry. *Int J Oral Implantol* 1987;4:7–13.
5. Froum SJ, Wallace SS, Cho SC, Elian N, Tarnow DP. Histomorphometric comparison of a biphasic bone ceramic to anorganic bovine bone for sinus augmentation: 6- to 8-month postsurgical assessment of vital bone formation. A pilot study. *Int J Periodontics Restorative Dent* 2008;28:273–281.
6. Rueger JM. Bone substitutes. State of the art and: What lies ahead [in German]? *Unfallchirurg* 1996;99:228–236.
7. Somanathan RV, Simůnek A. Evaluation of the success of beta-tricalciumphosphate and deproteinized bovine bone in maxillary sinus augmentation using histomorphometry: A review. *Acta Medica (Hradec Kralove)* 2006;49:87–89.
8. Artzi Z, Kozlovsky A, Nemcovsky CE. The amount of newly formed bone in sinus grafting procedures depends on tissue depth as well as the type and residual amount of the grafted material. *J Clin Periodontol* 2005;32:193–199.
9. Lange GL, Overman JR, Farré-Guasch E, et al. A histomorphometric and micro-computed tomography study of bone regeneration in the maxillary sinus comparing biphasic calcium phosphate and deproteinized cancellous bovine bone in a human split-mouth model. *Orl Surg Oral Med Oral Pathol Oral Radiol* 2014; 117:8–22.
10. Froum SJ, Wallace SS, Elian N, Cho SC, Tarnow DP. Comparison of mineralized cancellous allograft (Puros) and anorganic bovine bone matrix (Bio-Oss) for sinus augmentation: Histomorphometry at 26 to 32 weeks after grafting. *Int J Periodontics Restorative Dent* 2006; 26:543–551.
11. Gapski R, Neiva R, Oh TJ, Wang HL. Histologic analyses of human mineralized bone grafting material in sinus elevation procedures: A case series. *Int J Periodontics Restorative Dent* 2006;26: 59–69.

12. Cammack GV 2nd, Nevins M, Clem DS 3rd, Hatch JP, Mellonig JT. Histologic evaluation of mineralized and demineralized freeze-dried bone allograft for ridge and sinus augmentations. *Int J Periodontics Restorative Dent* 2005;25:231–237.
13. John HD, Wenz B. Histomorphometric analysis of natural bone mineral for maxillary sinus augmentation. *Int J Oral Maxillofac Implants* 2004;19:199–207.
14. Fugazzotto PA. GBR using bovine bone matrix and resorbable and nonresorbable membranes. Part 1: Histologic results. *Int J Periodontics Restorative Dent* 2003;23:361–369.
15. Tapety FI, Amizuka N, Uoschima K, Nomura S, Maeda T. A histological evaluation of the involvement of Bio-Oss in osteoblastic differentiation and matrix synthesis. *Clin Oral Implants Res* 2004;15:315–324.
16. Behrens B, Wolf E, Bruns J. In vitro culture of human autologous osteoblast cells on natural bone mineral [in German]. *Orthopade* 2000;29:129–134.
17. Hjørting Hansen E. Bone grafting to the jaws with special reference to reconstructive preprosthetic surgery. A historical review. *Mund Kiefer Gesichtschir* 2002;6:6–14.
18. Weibrich G, Trettn R, Gnoth SH, Götz H, Duschner H, Wagner W. Determining the size of the specific surface of bone substitutes with gas adsorption [in German]. *Mund Kiefer Gesichtschir* 2000;4:148–152.
19. Reynolds MA, Aichelmann-Reidy ME, Branch-Mays GL, Gunsolley JC. The efficacy of bone replacement grafts in the treatment of periodontal osseous defects. A systematic review. *Ann Periodontol* 2003;8:227–265.
20. Donath K, Breuner G. A method for the study of undecalcified bones and teeth with attached soft tissues. The Säge-Schliff (sawing and grinding) technique. *J Oral Pathol* 1982;11:318–326.
21. Schlegel A, Donath K. BIO-OSS—A resorbable bone substitute? *J Long Term Eff Med Implants* 1998;8:201–209.
22. Tadjoein ES, de Lange GL, Bronckers AL, Lyaruu DM, Burger EH. Deproteinized cancellous bovine bone (Bio-Oss) as bone substitute for sinus floor elevation. A retrospective, histomorphometrical study of five cases. *J Clin Periodontol* 2003;30:261–270.
23. Edinger DH, Acil Y. Histological long time results of a sinus lift over 11 years—A clinical case report. *Osteologie* 2010;19:261–265.
24. Lee YM, Shin SY, Kim JY, Kye SB, Ku Y, Rhyu IC. Bone reaction to bovine hydroxyapatite for maxillary sinus floor augmentation: Histologic results in humans. *Int J Periodontics Restorative Dent* 2006;26:471–481.
25. Skoglund A, Hising P, Young C. A clinical and histologic examination in humans of the osseous response to implanted natural bone mineral. *Int J Oral Maxillofac Implants* 1997;12:194–199.
26. Froum SJ, Tarnow DP, Wallace SS, Rohrer MD, Cho SC. Sinus floor elevation using anorganic bovine bone matrix (OsteoGraf/N) with and without autogenous bone: A clinical, histologic, radiographic, and histomorphometric analysis—Part 2 of an ongoing prospective study. *Int J Periodontics Restorative Dent* 1998;18:528–543.
27. Valentini P, Abensur D, Wenz B, Peetz B, Schenk R. Sinus grafting with porous bone mineral (Bio-Oss) for implant placement: A 5-year study on 15 patients. *Int J Periodontics Restorative Dent* 2000;20:245–253.
28. Mordenfeld A, Hallman M, Johansson CB, Albrektsson T. Histological and histomorphometrical analyses of biopsies harvested 11 years after maxillary sinus floor augmentation with deproteinized bovine and autogenous bone. *Clin Oral Implants Res* 21;2010;961–970.
29. Schulten EA, Prins HJ, Overman JR, Helder MN, ten Bruggenkate CM, Klein-Nulend J. A novel approach revealing the effect of a collagenous membrane on osteoconduction in maxillary sinus floor elevation with β -tricalcium phosphate. *Eur Cell Mater* 2013;25:215–228.
30. Meijndert L, Raghoobar GM, Schüpbach P, Meijer HJ, Vissink A. Bone quality at the implant site after reconstruction of a local defect of the maxillary anterior ridge with chin bone or deproteinised cancellous bovine bone. *Int J Oral Maxillofac Surg* 2005;34:877–884.