

CLINICAL SCIENCE

Veneered zirconia crowns as abutment teeth for partial removable dental prostheses: A clinical 4-year retrospective study



Juha Pihlaja, DDS,^a Ritva Näpänkangas, DDS, PhD,^b Ritva Kuoppala, DDS,^c and Aune Raustia, DDS, PhD^d

Demands for highly esthetic and more biocompatible materials have increased the use of ceramic restorations in fixed prosthodontics.¹ Because of its adequate mechanical properties, zirconia has a wide range of applications in restorative dentistry.²⁻⁴ For this reason, zirconia could also serve as an alternative to metal ceramics in abutment teeth for partial removable dental prostheses (RDPs) with a metal framework.⁵

The survival rate of abutment teeth is lower than that of nonabutment teeth.^{6,7} Risk factors for loss of an abutment tooth have included a low number of residual teeth, which increases the occlusal load on the abutment tooth, a crown-root ratio (>1:1), an endodontically treated tooth, and a pocket depth greater than 5 mm.⁷ RDPs are also associated with caries and periodontal diseases,⁸ although RDPs designed according to hygienic principles have been clinically successful.⁹

Direct and indirect retainer elements may have more damaging periodontal effects when compared with

ABSTRACT

Statement of problem. The mechanical properties of zirconia suggest that it might serve as a material for abutment crowns for partial removable dental prostheses (RDPs). Only limited clinical evidence is available for the use of ceramics as abutment crowns.

Purpose. The purpose of this retrospective clinical study was to evaluate the outcome of veneered zirconia single crowns in abutment teeth for RDPs in participants treated by predoctoral students.

Material and methods. Thirty-seven veneered zirconia single crowns in 17 participants (9 men and 8 women; mean age 62.5 years) were prepared as abutment teeth for a clasp-retained RDP with a metal framework: 22 crowns with an occlusal rest seat and 15 crowns with both an occlusal rest seat and retentive clasps. The mean follow-up time was 4.2 years (2.9 to 5.4 years). In a clinical examination, the anatomic form of the crown, marginal fidelity (the border between the crown and the tooth was felt with an explorer), wear of the ceramic surface in the rest seat, and fracture of the veneering porcelain were examined and assessed as good, acceptable, or unacceptable. The retention and stability of the RDPs were recorded as good, moderate, or poor.

Results. The complications found were fracture of the veneering porcelain (11%) and fracture of the occlusal rest seat (3%). Wear of porcelain at the occlusal contact point was found in 24% of the zirconia single crowns. Wear of the ceramic surfaces of the rest seats for the RDPs was not found. The retention was good in all RDPs. The stability was good in 73% and moderate in 23% of the RDPs.

Conclusions. Veneered zirconia single crowns are suitable in abutment teeth for RDPs with a metal framework. Fracture in the veneering porcelain remains a problem with veneered zirconia, although the zirconia surface in the rest seats for RDPs showed no wear. (J Prosthet Dent 2015;114:633-636)

nonabutment elements.¹⁰ Properly balanced and distributed forces of an RDP on an abutment tooth can enhance the longevity of both the oral structures and the RDP.^{9,11} An occlusal rest seat for an RDP provides vertical support and allows occlusal forces to be transmitted through the long axis of the abutment tooth.^{11,12} Furthermore, the proper form of the abutment tooth and rest seat allows for

^aResearch Assistant, Department of Prosthetic Dentistry and Stomatognathic Physiology, Institute of Dentistry, University of Oulu, Oulu, Finland.

^bSenior Lecturer, Department of Prosthetic Dentistry and Stomatognathic Physiology, Institute of Dentistry, University of Oulu, Oulu, Finland.

^cSenior Lecturer, Department of Prosthetic Dentistry and Stomatognathic Physiology, Institute of Dentistry, University of Oulu, Oulu, Finland.

^dProfessor, Department of Prosthetic Dentistry and Stomatognathic Physiology, Institute of Dentistry, University of Oulu, Oulu, Finland.

Clinical Implications

As an alternative to metal ceramics, veneered zirconia single crowns can be used in abutment teeth for clasp-retained partial RDPs.

appropriate masticatory force transmission, retention, and stability of supporting structures.^{11,13,14} Rest seats have proved to be stable when prepared from enamel, composite resin, or amalgam.¹⁴

Wrought clasps may influence wear in abutment teeth.^{10,15} In an *in vitro* study, clasps caused more wear in composite resin surfaces than in enamel or ceramic surfaces.¹⁶ The fabrication of ceramic crowns for RDPs has been described in 1 study in which rest seats and guide planes were made of densely sintered aluminum oxide and retentive areas were made of veneering porcelain.¹⁷ To our knowledge, no studies of zirconia used as a material in abutment teeth for RDPs have been published. The hypothesis of this study was that veneered zirconia single crowns can be successfully used in abutment teeth for RDPs with a metal framework. The purpose of this retrospective clinical follow-up study was to evaluate the outcome of veneered zirconia single crowns in abutment teeth for RDPs in participants treated by predoctoral students.

MATERIAL AND METHODS

The study protocol was approved by the Ethical Committee of the Northern Ostrobothnia Hospital District (100/2013). Altogether 17 participants treated with a veneered zirconia single crown in an abutment tooth for an RDP attended the clinical follow-up study between February and April 2013. The participants were treated between 2007 and 2010 by predoctoral dental students at the Institute of Dentistry, University of Oulu. There were 9 men and 8 women; their mean age was 62.5 years (47 to 75 years). The mean follow-up time was 4.2 years (2.9 to 5.4 years). Altogether 37 veneered zirconia single crowns were prepared for an abutment tooth for a clasp-retained RDP with a metal framework: 22 crowns with an occlusal rest seat and 15 crowns with both an occlusal rest seat and retentive clasps (Table 1). The opposing dentition was natural teeth in 57%, fixed prostheses in 19%, a complete removable dental prosthesis in 19%, and an RDP in 5% of the participants.

All the participants underwent an oral hygiene program before prosthetic treatment. The preparation of the abutment tooth for the crown was done in accordance with international treatment guidelines, taking into account adequate occlusal clearance and the space needed for the guide plane and occlusal rest seat for the RDP with a metal framework.^{11,18} Composite resin (Z250; 3M ESPE) was used for foundation restorations when

needed, and a fiber post (RelyX; 3M ESPE) was used in endodontically treated teeth. The restorations were bonded with dual-polymerizing, self-adhesive universal resin cement (RelyX Unicem; 3M ESPE) according to the manufacturer's instructions. The zirconia frameworks in the single crowns were fabricated from Zirkonzahn Zirconia (Zirkonzahn). The frameworks were fabricated by manual milling, the minimal thickness of the framework was 0.4 mm, and the veneering porcelain (GC Initial Zr; GC Europe) was layered onto the frameworks. The rest seats were located on the zirconia framework, and the veneering porcelain originated near the incisal or occlusal edge of the single crown (Figs. 1, 2). All the treatment procedures were performed under the supervision of clinical instructors specialized in prosthetic dentistry.

The RDPs with a metal framework were produced according to a standardized protocol.¹⁹ The material for the frameworks was a cobalt-chromium alloy (Wironit extra-hard; Bego) and the denture bases were acrylic resin (ProBase 36 P-V; Ivoclar Vivadent AG). Dental rests were used as supporting structures on the palatal or lingual side of the abutment teeth and at the incisal edges, if needed. In the mandible, the bar connector was located to the lingual of the mandibular teeth. In the maxilla, the major connectors were a palatal plate and/or a palatal bar. Cast clasps were used as retaining structures in the abutment teeth.

The clinical follow-up examinations were carried out by the same prosthodontist (R.N.). The anatomic form of the crown, marginal fidelity (the border between the crown and the tooth was felt with a probe), wear of the ceramic surface in the rest seat, and fracture of the veneering porcelain were examined and assessed as good, acceptable, or unacceptable. The retention and stability of the RDPs were recorded as good, moderate, or poor. Retention was evaluated by trying to displace the RDP against vertical forces. Retention was assessed as good if the RDP resisted displacement, moderate if only minor displacement was noticed, and poor if the RDP loosened easily. Stability was evaluated by applying rotational and horizontal forces directed posteriorly, anteriorly, and transversally to the RDP. Stability was assessed as good if the RDP remained steady, firm, and constant in position, moderate if pushing the RDP in the occlusal or lateral direction caused swinging or loosening, and poor if the RDP did not remain in position when occlusal or lateral stresses were applied.¹⁹

RESULTS

The complications found in veneered zirconia single crowns made for an abutment tooth for an RDP were fracture of the veneering porcelain (11%) and fracture of the occlusal rest seat (3%) (Tables 1, 2; Fig. 3). Wear of the ceramic surfaces of the rest seats for the RDPs was not found in any crowns.

Table 1. Opposing dentition, Kennedy classification, and zirconia single crowns in participants with RDPs

Participant Number	Opposing Arch	Kennedy (maxillary)	Kennedy (mandibular)	Veneered Zirconia Single Crowns	Complications
1	Complete denture		I	Bilateral occlusal rest seat and clasp	
2	Own teeth		II	Unilateral occlusal rest seat	
3	Complete denture		I	Unilateral occlusal rest seat and clasp	
4	Own teeth	I		Unilateral occlusal rest seat and clasp	
5		I	II	Unilateral occlusal rest seat and clasp (maxillary)	
6	Complete denture		I	Unilateral occlusal rest seat and clasp	
7		I	I	Bilateral occlusal rest seat and clasp (maxillary) 3 more teeth with occlusal rest seat (maxillary)	Porcelain fracture (3 teeth)
8		II	III	Unilateral occlusal rest seat and clasp (mandibular)	Porcelain fracture
9	Own teeth	I		Bilateral occlusal rest seat	
10	Removable partial denture		I	Bilateral occlusal rest seat and clasp	
11	Complete denture		I	Bilateral occlusal rest seat and clasp	
12	Own teeth	I		Unilateral occlusal rest seat and clasp	
13	Complete denture		I	Bilateral occlusal rest seat and clasp	
14		I	I	2 teeth with occlusal rest seat (maxillary) Unilateral occlusal rest seat and clasp (mandibular)	
15	Own teeth	III		Bilateral occlusal rest seat and clasp 2 more teeth with occlusal rest seat	Fracture in occlusal rest seat
16		I	I	Bilateral occlusal rest seat and clasp (mandibular)	
17		I	I	Bilateral occlusal rest seat and clasp (mandibular) 5 more teeth with occlusal rest seat (mandibular)	

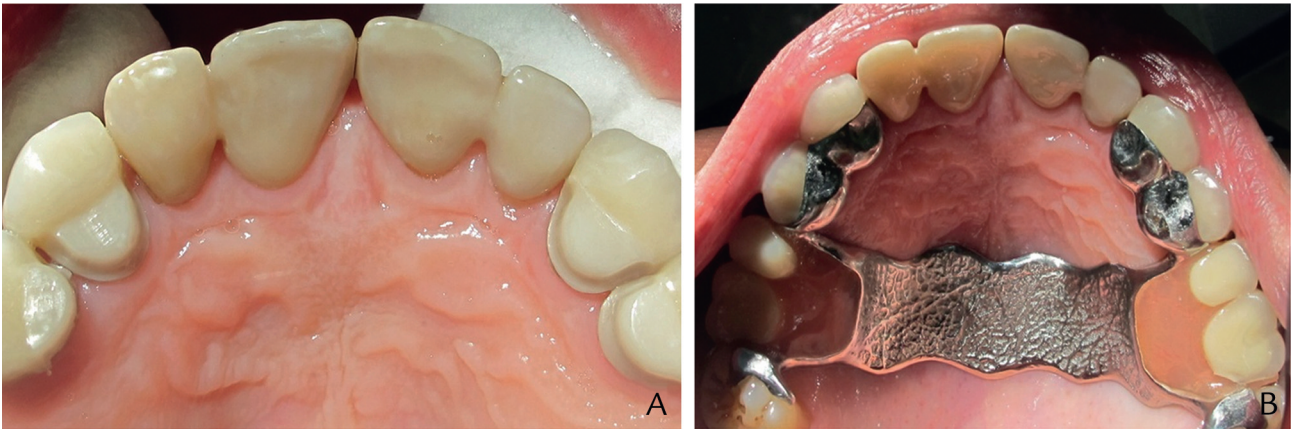


Figure 1. Zirconia single crowns with occlusal rest seats prepared as abutment teeth for RDP in maxillary canines and premolars. Rest seats located in zirconia surface and veneering porcelain originated near occlusal edge of crown. RDP was retained with cast clasps in maxillary premolars and in molars (Kennedy III).

Retention was good in all RDPs. The stability was good in 73% and moderate in 23% of the RDPs.

DISCUSSION

The veneered zirconia single crowns were suitable for use for RDP abutment teeth. The most prevalent complication was fracture in the veneering porcelain (11%), which has been previously reported with zirconia restorations.²⁰⁻²³ However, in all crowns, the zirconia surface of the rest seat toward the metal framework of the RDP was shiny and smooth as felt with an explorer, and no wear was seen. In 1 crown the zirconia occlusal rest seat was fractured, perhaps due to the participant’s bruxism. The

RDP causes stress on the abutment tooth and on the veneering porcelain surface. The special considerations and extra space needed for occlusal rest seats must be taken into account in preparing the design of abutment teeth for RDPs. Technically, the abutment crowns for RDPs were shaped to provide occlusal rest seats, guide planes, and retentive areas for clasps¹³; for this reason, metal ceramic crowns have traditionally been the solution of choice for RDP abutments.³ In this study the occlusal rest seats were excessively contoured in many crowns; in the fractured crown, the margin of the crown was not below the preparation margin. In all crowns, the occlusal rest seat was pure zirconia and the ceramic veneer was located near the incisal edge of the crown.

Table 2. Clinical assessment of 37 zirconia single crowns as abutment tooth for RDP

Clinical Assessment	Good (%)	Acceptable (%)	Unacceptable (%)
Fracture of porcelain	86	14	0
Anatomical form	87	13	0
Marginal fidelity	95	5	0
Wear of ceramic surface in rest seat	100	0	0

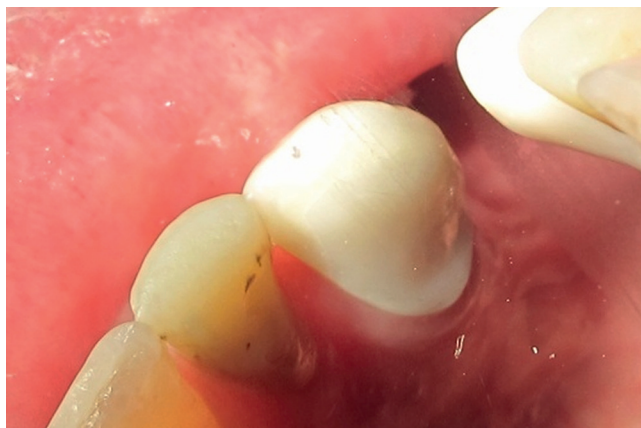

Figure 2. Design of occlusal rest seat in zirconia single crowns as abutment tooth for RDP is more round than in metal ones.

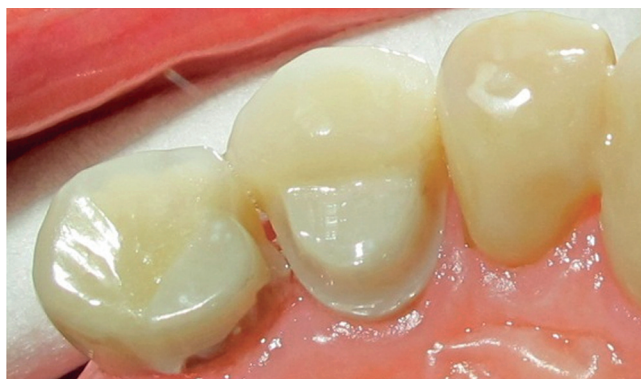

Figure 3. Fracture of zirconia occlusal rest seat in maxillary premolar RDP abutment tooth.

Zirconia has changed traditional treatment concepts in single crowns and RDPs. The improved esthetics support the use of zirconia, despite the metal RDP framework. The material properties of ceramics make the design of the occlusal rest seat more rounded than in metal ones, which may reduce resistance form. However, in this study, the retention and stability were recorded as good in most of the RDPs with a metal framework.

CONCLUSION

Veneered zirconia single crowns are suitable for use in abutment teeth for partial RDPs with a metal framework. Fracture in the veneering porcelain remains a problem with veneered zirconia, although the zirconia surface in

rest seats for RDPs showed no wear. This will encourage the use of zirconia instead of metal ceramics, but more follow-up studies are needed to determine the survival and success of zirconia crowns in these treatments.

REFERENCES

1. Raigrodski AJ. Contemporary materials and technologies for all-ceramic fixed partial dentures: a review of the literature. *J Prosthet Dent* 2004;92:557-62.
2. Manicone PF, Rossi Iommetti P, Raffaelli L. An overview of zirconia ceramics: basic properties and clinical applications. *J Dent* 2007;35:819-26.
3. Batson ER, Cooper LF, Duquum I, Mendonça G. Clinical outcomes of three different crown systems with CAD/CAM technology. *J Prosthet Dent* 2014;112:770-7.
4. Flinn BD, Raigrodski AJ, Singh A, Mancil LA. Effect of hydrothermal degradation on three types of zirconias for dental application. *J Prosthet Dent* 2014;112:1377-84.
5. Carracho JF, Razzoog ME. Removable partial denture abutments restored with all-ceramic surveyed crowns. *Quintessence Int* 2006;37:283-8.
6. Hirotsu T, Yoshihara A, Ogawa H, Miyazaki H. Tooth-related risk factors for tooth loss in community-dwelling elderly people. *Community Dent Oral Epidemiol* 2012;40:154-63.
7. Tada S, Ikebe K, Matsuda K, Maeda Y. Multifactorial risk assessment for survival of abutments of removable partial dentures based on practice-based longitudinal study. *J Dent* 2013;41:1175-80.
8. Preshaw PM, Walls AWG, Jakubovics NS, Moynihan PJ, Jepson NJA, Loewy Z. Association of removable partial denture use with oral and systemic health. *J Dent* 2011;39:711-9.
9. Rehmann P, Orbach K, Ferger P, Wöstmann B. Treatment outcomes with removable partial dentures: a retrospective analysis. *Int J Prosthodont* 2013;26:147-50.
10. de Amaral BA, Barreto AO, Gomes Seabra E, Roncalli AG, da Fonte Porto Carreiro A, de Almeida EO. A clinical follow-up study of the periodontal conditions of RPD abutment and non-abutment teeth. *J Oral Rehabil* 2010;37:545-52.
11. Rudd RW, Bange AA, Rudd KD, Rudd RM. Preparing teeth to receive a removable partial denture. *J Prosthet Dent* 1999;82:536-49.
12. Luk NK, Wu VH, Liang BM, Chen YM, Yip KH, Smales RJ. Mathematical analysis of occlusal rest design for cast removable partial dentures. *Eur J Prosthodont Restor Dent* 2007;15:29-32.
13. Burns DR, Unger JW. The construction of crowns for removable partial denture abutment teeth. *Quintessence Int* 1994;25:471-5.
14. de Aquino AR, Barreto AO, de Aquino LM, Ferreira AM, Carreiro A. Longitudinal clinical evaluation of undercut areas and rest seats of abutment teeth in removable partial denture treatment. *J Prosthodont* 2011;20:639-42.
15. Kasperski J, Chladek G, Plonka L. The analysis of the effect of wrought wire clasps on the conditions of abutment teeth. *Acta Bioeng Biomech* 2013;15:27-33.
16. Helal MA, Baraka OA, Sanad ME, Ludwig K, Kern M. Effects of long-term simulated RPD clasp attachment/detachment on retention loss and wear for two clasp types and three abutment material surfaces. *J Prosthodont* 2012;21:370-7.
17. Kancyp S, Sierraalta M, Razzoog ME. All-ceramic surveyed crowns for removable partial denture abutments. *J Prosthet Dent* 2000;84:400-2.
18. Shillingburg HT, Staher DA, Wilson EL, Cain JR, Mitchell DL, Blanco LJ, et al. Fundamentals of fixed prosthodontics. 4th ed. Chicago: Quintessence Publishing; 2012. p. 131-48. 161-2.
19. Molin Thorén M, Gunne J, editors. Textbook of removable prosthodontics – the Scandinavian approach. Copenhagen: Munksgaard Denmark; 2012. p. 169-216.
20. Raigrodski AJ, Hillstead MB, Meng GK, Chung KH. Survival and complications of zirconia-based fixed dental prostheses: a systematic review. *J Prosthet Dent* 2012;107:170-7.
21. Pihlaja J, Nääpänkangas R, Raustia A. Early complications and short-term failures of zirconia single crowns and partial fixed dental prostheses. *J Prosthet Dent* 2014;112:778-83.
22. Ramos CM, Cesar PF, Lia Mondelli RF, Tabata AS, de Souza Santos J, Sanches Borges AF. Bond strength and Raman analysis of the zirconia-feldspathic porcelain interface. *J Prosthet Dent* 2014;112:886-94.
23. Nishigori A, Yoshida T, Bottino MC, Platt JA. Influence of zirconia surface treatment on veneering porcelain shear bond strength after cyclic loading. *J Prosthet Dent* 2014;112:1392-8.

Corresponding author:

Dr Juha Pihlaja
University of Oulu
Box 5281, FIN-90014 Oulu
FINLAND
Email: juha.t.pihlaja@gmail.com

Copyright © 2015 by the Editorial Council for *The Journal of Prosthetic Dentistry*.