

A Collapsible Partial Denture for a Patient with Limited Mouth Opening Induced by Scleroderma: A Clinical Report

Ayşe Gözde Türk, DDS, PhD & Mübin Ulusoy, DDS, PhD

Prosthodontics Department, Faculty of Dentistry, Ege University, İzmir, Turkey

Keywords

Microstomia; scleroderma; collapsible partial denture; hinge attachment.

Correspondence

Ayşe Gözde Türk, Faculty of Dentistry,
Department of Prosthodontics, Ege
University, Bornova, İzmir 35100, Turkey.
E-mail: agturk@gmail.com

*The authors have no funding, financial
relationships, or conflicts of interest to
disclose.*

Accepted April 15, 2014

doi: 10.1111/jopr.12220

Abstract

A limited opening of the mouth is defined as microstomia. Microstomia is caused by burns, postoperative head and neck trauma, radiotherapy, or scleroderma. The prosthetic treatment of microstomia presents particular challenges, and patients often complain of an inability to insert or remove the prosthesis. The cause and severity of microstomia can influence the approach to treatment. Different treatment methods have been suggested, including the fabrication of two-piece partial dentures. This clinical report describes the construction of a sectional impression tray and a collapsed partial denture using a hinge attachment for a patient with microstomia.

A limited oral opening can be caused by scleroderma, burns, surgical treatment of orofacial cancers, head and neck radiation, reconstructive lip surgery, and trauma.¹ Scleroderma is a disease that causes fibrosis by affecting the connective tissue and the blood vessels; it is believed to stem from a disorder of the immune system.² In the later phases of sclerosis, the facial skin and oral mucosa become thin and taut, and wrinkles disappear, resulting in a mask-like appearance and a reduced oral opening.^{3,4}

Patients with microstomia often complain of an inability to insert or remove prostheses.⁵ Several treatment options have been reported, including surgical commisurotomy^{6,7} and static and dynamic opening devices called microstomia orthoses.^{4,8-10} Surgical enlargement must be considered carefully because if the operation is not sufficient, a scar may result,¹ and can further reduce the oral opening.⁷ In previous reports flexible^{3,11,12} and sectioned impression trays,^{1,5,6,13-16} were used to make preliminary impressions, and sectional custom trays were used for final impressions.^{1,3,5,11,13,17,18} Sectional and collapsible dentures have been reported, and different connecting mechanisms have been described for microstomia patients including hinges,^{1-3,5,13,15} pins,¹⁶ swinglock attachments,^{1,15} stud attachments,^{2,19} telescopic systems,^{1,3} clasp retainers,¹⁸ and magnetic attachments.^{4,5}

This clinical report describes the prosthodontic treatment using a hinge attachment of a partially edentulous patient with microstomia induced by scleroderma.

Clinical report

A 56-year-old partially edentulous woman with microstomia induced by scleroderma presented to the Department of Prosthodontics at Ege University, School of Dentistry, İzmir, Turkey. Oral examination revealed a limited maximal mouth opening (MMO) measuring about 23 mm, as this distance is between the incisal edge of the upper and lower first incisors,^{20,21} with a partial edentulous mandibular arch (Fig 1). Severe microstomia (MMO \leq 30 mm) was diagnosed according to the criteria provided by Naylor et al.²¹ The circumference of her mouth measured approximately 95 mm via a method described by Wood et al.²² The level of oral hygiene was good, and the remaining teeth were free of caries. She had not used a denture before, and her chief complaint was not chewing properly. Without surgery it is very difficult to provide prosthetic treatment for patients with microstomia, especially when the mouth circumference length is less than 160 mm, because the smallest diameter of a fully retentive denture may be larger than the greatest diameter of the mouth opening.¹ Several treatment options were considered, including nonsurgical mouth-stretching exercises,^{20,21} microstomia orthoses,⁸⁻¹⁰ and surgical commissural enlargement^{6,7} to expand mouth circumference, and implant treatment to make fixed partial dentures. The patient did not agree to any long-term exercises or surgical treatment, so the decision was made to fabricate a collapsible removable partial denture (RPD).

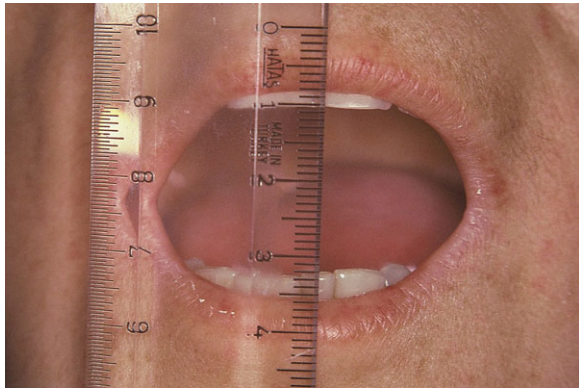


Figure 1 Extraoral view of patient with a limited maximal mouth opening of 23 mm.

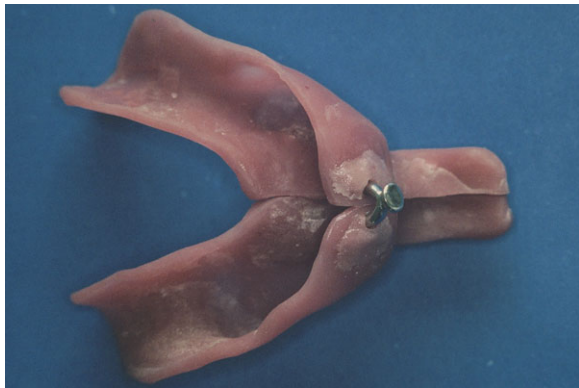


Figure 2 Custom impression tray was sectioned, and holes were prepared for pin stabilization.

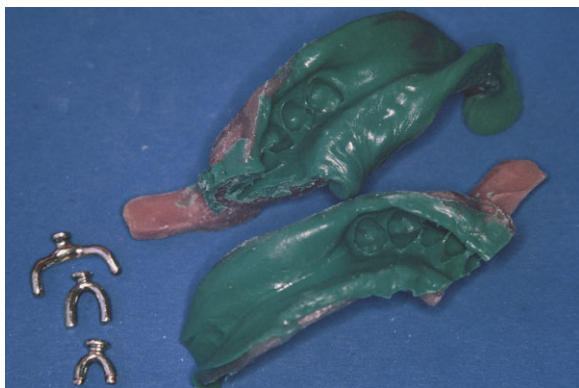


Figure 3 The pins were detached, and the sectioned impression trays were removed from the mouth separately.

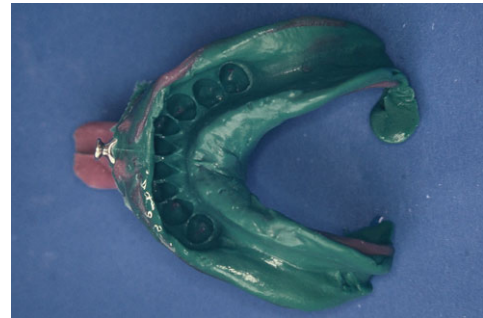


Figure 4 The pins were fitted to connect the trays.




Figure 5 A prefabricated hinge attachment (Microhinge A3) was used to fabricate a collapsible RPD.

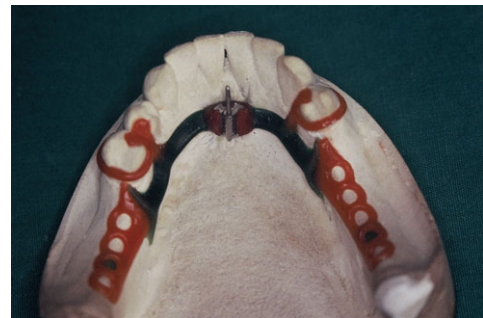

Figure 6 A phosphate-bonded refractory cast and wax pattern of the framework (note the hinge attachment on the lingual midline).

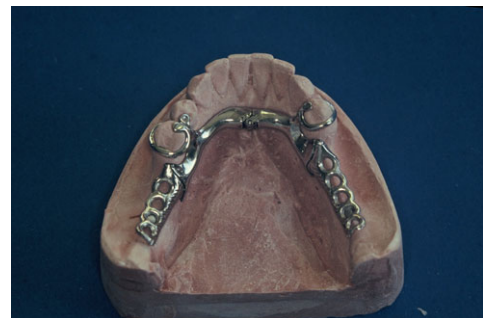

Figure 7 Cast Co-Cr framework on the master cast.

Prior to impression procedures, oral structures were evaluated for any requirement of tooth recontouring. The remaining teeth, which were planned to receive retainers, had naturally occurring undercuts and guide planes on the enamel surface. To permit sufficient bulk without occlusal interference, the occlusal rest seats were prepared with a diamond round bur like a spoon shape on mesial marginal ridges toward the center of the left second and the right first premolars and on the distal marginal ridge toward the center of the left first premolar tooth.

Impression procedures

Limited oral access made it impossible to make primary impressions using a stock impression tray. Therefore, sectioning a mandibular stock-perforated impression tray into halves from the midline to insert into the mouth for both dental arches was planned. First, the right half tray with irreversible hydrocolloid (Zelgan 2002; Dentsply DeTrey GmbH, Konstanz, Germany) was inserted in the mouth. After removal of the impression, the excess material was cut from the midline, then the right impression was again placed in the mouth. The left half tray with irreversible hydrocolloid (Zelgan 2002) was inserted, and care was taken that both joint surfaces came into contact. First the left impression, then the right one were removed from the mouth, because they were not adhered. The right and left impressions were reassembled with the handles of the trays using sticky wax (Kerr Corporation, Orange, CA). Dental stone (Moldano; Bayer Dental, Leverkusen, Germany) was poured into the reassembled impressions. Finally, a one-piece preliminary cast was fabricated. Using the preliminary cast, a custom impression tray was fabricated with autopolymerizing acrylic resin (Meliodent; Bayer UK Ltd, Newbury, UK). Using a thin cutting disc, the tray was sectioned along the midline from the posterior border to the anterior border of the handle. Three custom-made stainless steel pins were cast with diameters of 4, 6, and 10 mm, and holes were prepared according to the dimensions of the pins, along the cutting surfaces of sectioned trays to stabilize the trays with accurate fit (Fig 2). Since continuous insertion and removal of the sectional trays with modeling compound was uncomfortable for the patient, border molding could not be done. The impression tray was filled with low-viscosity elastomeric impression material (Coltex; Coltene Whaledent, Alsätten, Switzerland) and inserted into the patient's mouth in two pieces. After placement, these pieces were stabilized with three stainless steel pins. After the impression material set, the pins were detached, and the left and right pieces of the impression tray were removed separately from the mouth by fracturing the impression material (Fig 3). Then the pins were carefully fitted (Fig 4), and type IV dental stone was poured (Moldano).

RPD design

The master cast was carefully examined, and a mandibular RPD was designed. Because the measurement between the lingual free gingival margin and the floor of the mouth was approximately 10 mm, a lingual bar was selected as a major connector. Hinge attachment has been reported to enhance the ease of insertion and removal.¹⁵ A prefabricated hinge attachment of 5.5 mm in height, 6 mm in width, and 1.9 mm in thickness (Microhinge A3; Artiglio, Parma, Italy) was used to connect

the two segments of the denture (Fig 5). The wax pattern of the framework was fabricated on a phosphate-bonded refractory cast (Wirowest; Bego, Bremen, Germany) with the hinge attachment on the lingual midline (Fig 6). Cast clasps were planned, since rigid direct retainers are associated with less mobility of the abutment teeth and less force on the residual ridge than wrought-wire retainers.²³ Back-action clasps with mesial rests were used on premolar teeth bilaterally to provide more retention and stability from their long arms.²⁴ It has also been found that back-action clasps can maintain their retentive force for a longer period.²⁴ Mesial rests were used to reduce stress on the abutment teeth in the distal-extension RPD. In addition, because of the limited mouth opening, the guide planes were not planned on the distal surface of the abutments. The mesiolingually oriented minor connectors and mesial rests are designed to guide the RPD insertion and removal more anteriorly. Distal auxiliary rest on the first left premolar tooth was planned as an indirect retainer to prevent the rotation of the RPD, because it was placed anterior to the rotation axis of the RPD.

RPD fabrication and delivery

The entire wax pattern was invested, cast with Co-Cr alloy (Wironit; Bego), desprued, and polished, then returned to the master cast (Fig 7). The RPD framework fit was evaluated in the mouth. The maxillomandibular relationship was recorded with wax rims on the metal framework. Then the master cast was mounted on an articulator to arrange artificial teeth. After completing the tooth arrangement, the wax denture was evaluated in the mouth. The denture was processed in heat-polymerized polymethyl methacrylate (Meliodent) according to the manufacturer's instructions. Then it was flaked, trimmed, and polished. The RPD was completed with conventional techniques and delivered (Fig 8A, B).^{1,13,15} The patient was given home-care instructions on the operation of insertion and removal of the prosthesis (Fig 9A, B).

Discussion

Microstomia is a common postoperative complication of head and neck trauma, scleroderma, and resection of facial and oral neoplasms.¹⁵ Although patients with microstomia presenting for prosthetic rehabilitation pose a challenge to the clinician, the treatment can be conservatively managed by modifying clinical and laboratory procedures. The overall bulk and the height of the impression trays make the recording of impressions difficult, because the paths of insertion and removal of impressions are compromised by the lack of clearance. The use of sectional impressions that can be recorded in two or more parts and then relocated outside the mouth is a useful technique to adapt for such patients.²⁵ Although reseating the first half of the cast on the second half of the impression would be more accurate than the method described by Suzuki et al,¹ we used sectional impressions for the preliminary impression. The stock trays were relocated with sticky wax that would be more accurate than methods used by various authors who have used silicone impression material with finger pressure or approximated the half casts to form a preliminary cast.^{13,25,26} The custom trays

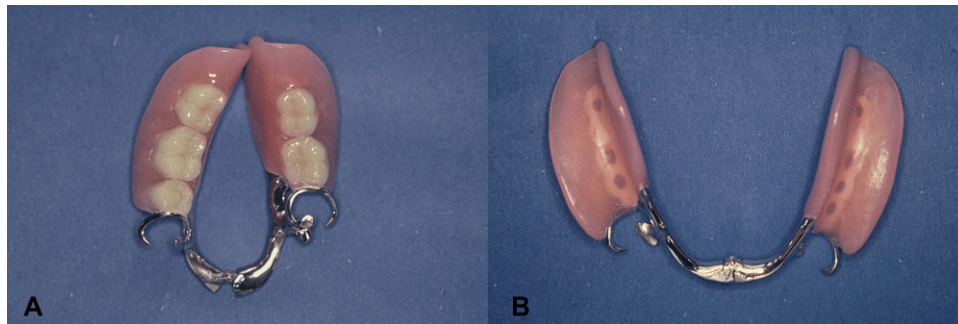


Figure 8 A: Collapsible RPD was completed. B: Lingual view of the RPD.

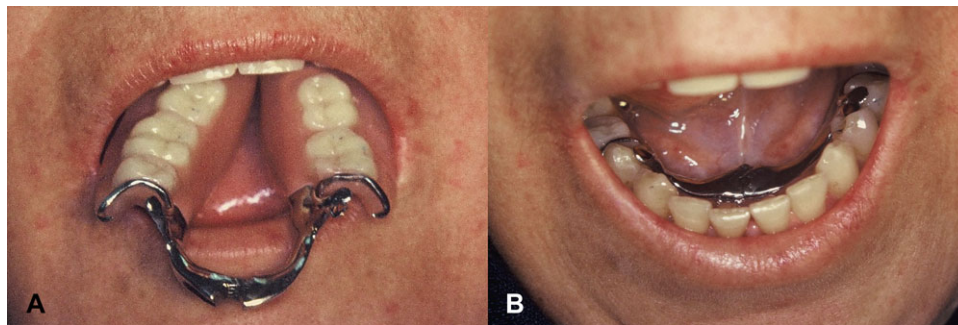


Figure 9 A: RPD was collapsed for insertion to the patient's mouth. B: Intraoral view of the RPD.

can be connected using pins,²⁵ stepped butt joints,³ and resin blocks with indexing technique²⁷ to facilitate relocation. In this report, pins were used to relocate the impression tray outside the mouth.

The construction of complete or partial dentures with limited oral opening has been studied by various authors. Some of these prostheses are sectional, magnetic, or collapsed. Although in the literature, a sectional prosthesis that could be introduced separately and assembled intraorally has been the general solution to the insertion of the definitive prosthesis,^{1-3,5,13,17-19} joining the pieces of a sectional denture base intraorally could be problematic, because most of these patients had hand deformities.^{2,3,11,13} Wahle et al reported that the simplified hinge-lock assembly used to join the mandibular sectional dentures did not appear to impart structural durability and stability while the denture was in function.¹⁵ In this report, the back-action clasp retainers and mesial rests were used to stabilize the denture. The advantages of this design include ease of insertion and removal of the RPD due to the hinge mechanism of the lingual bar and mesially positioned occlusal rests and minor connectors, no need for excessive tooth preparation except for rest seats, because back-action clasps engage in naturally occurring mesiobuccal undercuts of premolar teeth, retention ability with the use of cast clasps, and ease of home care. The back-action clasps with mesial rests also have been found to distribute occlusal loads as same as RPI and better than RPA clasps.²⁸

On the other hand, the disadvantage of this collapsible denture could be the collapsible property of the lingual bar with

the use of hinge attachment that may cause possible stresses on the abutment teeth and alveolar ridges.²⁹ The potential stresses could be reduced by using rigid cast clasps, minor connectors, an indirect retainer, and maximum alveolar support. Meticulous oral hygiene may also be suggested because of a possibility of food accumulation on the distal surface of the abutment teeth where the back action engages.

When the floor of the mouth in an anterior mandible is shallow, the use of this collapsible RPD may not be recommended. The dimensions of the hinge attachment used in this report were 5.5 mm in height and 1.9 mm in thickness. The suggested dimensions of a rigid lingual bar are at least 4 mm in height and 2 mm in thickness.³⁰ This hinge attachment should be used when the distance between the free gingival margin to the floor of the mouth is more than 8.5 mm because it is suggested that the lingual bar be positioned at least 3 mm from the gingival margin.³⁰ In this report, the patient had enough distance (10 mm) for the use of a hinge attachment. In situations of insufficient depth of the floor of the mouth, the swing-lock type RPD could be used for microstomia patients as described by Suzuki et al.¹

A foldable, single-piece RPD was fabricated for the patient described in this report. Although clinical and laboratory procedures were technique-sensitive, this collapsible RPD was easy to handle and within a day, the patient managed insertion and removal of her denture. The patient was provided with instructions for cleaning, inserting, and removing the prosthesis. She expressed satisfaction with both the appearance and masticatory

function in her follow-up calls. She was examined regularly for 4 months postinsertion. She was satisfied and adapted to the prosthesis perfectly. No visible fracture or wear has been observed on RPD components, but this needs to be confirmed with a longer follow-up period. Follow-up appointments will continue to see if there are any treatment complications. If the back-action clasps lose retentive properties, they can be adjusted, or if the clasps break, they can be recast and soldered. If edentulous alveolar ridges continue to resorb, the denture can be relined without any damage to the denture components.

Conclusion

For the patient described, a collapsible mandibular RPD was a suitable treatment. The hinge attachment reduced the cost and simplified the laboratory technique. The insertion and removal of the prosthesis was easy and practical to handle. This technique could be simple, inexpensive, and applicable to microstomia patients.

References

1. Suzuki Y, Abe M, Hosoi T, et al: Sectional collapsed denture for a partially edentulous patient with microstomia: a clinical report. *J Prosthet Dent* 2000;84:256-259
2. Cura C, Cotert HS, User A: Fabrication of a sectional tray and sectional complete denture for a patient with microstomia and trismus: a clinical report. *J Prosthet Dent* 2003;89:540-543
3. Benetti R, Zupi A, Toffanin A: Prosthetic rehabilitation for a patient with microstomia: a clinical report. *J Prosthet Dent* 2004;92:322-327
4. Colvenkar SS: Sectional impression tray and sectional denture for a microstomia patient. *J Prosthodont* 2010;19:161-165
5. Watanabe I, Tanaka Y, Ohkubo, et al: Application of cast magnetic attachments to sectional complete dentures for a patient with microstomia: a clinical report. *J Prosthet Dent* 2002;88:573-577
6. Naylor WP, Manor RC: Fabrication of a flexible prosthesis for the edentulous scleroderma patient with microstomia. *J Prosthet Dent* 1983;50:536-538
7. Dikbas I, Koksall T, Kazazoglu E: Fabricating sectional collapsible complete dentures for an edentulous patient with microstomia induced by scleroderma. *Quintessence Int* 2007;38:15-22
8. Khan Z, Banis JC Jr: Oral commissure expansion prosthesis. *J Prosthet Dent* 1992;67:383-385
9. Conine TA, Carlow DL, Stevenson-Moore P: The Vancouver microstomia orthosis. *J Prosthet Dent* 1989;61:476-483
10. Carlow DL, Conine TA, Stevenson-Moore P: Static orthoses for the management of microstomia. *J Rehabil Res Dev* 1987;24:35-42
11. Dhanasomboon S, Kiatsiriroj K: Impression procedure for a progressive sclerosis patient: a clinical report. *J Prosthet Dent* 2000;83:279-282
12. Whitsitt JA, Battle LW: Technique for making flexible impression trays for the microstomic patient. *J Prosthet Dent* 1984;52:608-610
13. Yenisey M, Külünk T, Kurt S, et al: A prosthodontic management alternative for scleroderma patients. *J Oral Rehabil* 2005;32:696-700
14. Luebke RJ: Sectional impression tray for patients with constricted oral opening. *J Prosthet Dent* 1984;52:135-137
15. Wahle JJ, Gardner LK, Fiebiger M: The mandibular swing-lock complete denture for patients with microstomia. *J Prosthet Dent* 1992;68:523-527
16. Moghadam BK: Preliminary impression in patients with microstomia. *J Prosthet Dent* 1992;67:23-25
17. McCord JF, Tyson KW, Blair IS: A sectional complete denture for a patient with microstomia. *J Prosthet Dent* 1989;61:645-647
18. Winkler S, Wongthai P, Wazney T: An improved splitdenture technique. *J Prosthet Dent* 1984;51:276-279
19. Geckili O, Cilingir A, Bilgin T: Impression procedures and construction of a sectional denture for a patient with microstomia: a clinical report. *J Prosthet Dent* 2006;96:387-390
20. Pizzo G, Scardina GA, Messina P: Effects of a nonsurgical exercise program on the decreased mouth opening in patients with systemic scleroderma. *Clin Oral Investig* 2003;7:175-178
21. Naylor WP, Douglass CW, Mix E: The nonsurgical treatment of microstomia in scleroderma: a pilot study. *Oral Surg Oral Med Oral Pathol* 1984;57:508-511
22. Wood RE, Lee P: Analysis of the oral manifestations of systemic sclerosis (scleroderma). *Oral Surg Oral Med Oral Pathol* 1988;65:172-178
23. Igarashi Y, Ogata A, Kuroiwa A, et al: Stress distribution and abutment tooth mobility of distal-extension removable partial dentures with different retainers: an in vivo study. *J Oral Rehabil* 1999;26:111-116
24. Helal MA, Baraka OA, Sanad ME, et al: Effect of clasp design on retention at different intervals using different abutment materials and in a simulated oral condition. *J Prosthodont* 2014;23:140-145
25. Heasman PA, Thomason JM, Robinson JG: The provision of prostheses for patients with severe limitation in opening of the mouth. *Br Dent J* 1994;176:171-174
26. Baker PS, Brandt RL, Boyajian G: Impression procedure for patients with severely limited mouth opening. *J Prosthet Dent* 2000;84:241-244
27. Rath N, Heshmati R, Yilmaz B, et al: A technique for fabricating a hinged mandibular complete dental prosthesis with swing lock for a patient with microstomia. *J Prosthet Dent* 2013;110:540-543
28. Pezzoli M, Appendino P, Calcagno L, et al: Load transmission evaluation by removable distal-extension partial dentures using holographic interferometry. *J Dent* 1993;21:312-316
29. Itoh H, Baba K, Aridome K, et al: Effect of direct retainer and major connector designs on RPD and abutment tooth movement dynamics. *J Oral Rehabil* 2008;35:810-815
30. Ao A, Wakabayashi N, Nitta H, et al: Clinical and microbiologic effects of lingual cervical coverage by removable partial dentures. *Int J Prosthodont* 2013;26:45-50