

## A TECHNIQUE FOR RETRIEVING FRACTURED IMPLANT SCREWS

**Ahmad Y. Imam, BDS, MS,<sup>a</sup> Alireza Moshaverinia, DDS, MS, PhD,<sup>b</sup> Winston W. L. Chee, DDS,<sup>c</sup> and Edwin A. McGlumphy, DDS, MS<sup>d</sup>**

Oral and Maxillofacial Rehabilitation Department, College of Dentistry, King Abdulaziz University, Jeddah, Saudi Arabia; Center for Craniofacial Molecular Biology, Herman Ostrow School of Dentistry, University of Southern California, Los Angeles, Calif; College of Dentistry, The Ohio State University, Columbus, Ohio

The use of dental implants as a source of support and retention for fixed restorations is common. This report describes the use of a fragment removal instrument together with the use of ultrasonic instrumentation to retrieve a screw fragment. (J Prosthet Dent 2014;111:81-83)

In contemporary dental practice, the use of dental implants as a source of support and retention of fixed restorations is common. Implant complications that can be categorized as implant positional, biologic, or mechanical.<sup>1,2</sup> Several etiologic factors for implant screw fracture have been described, including a nonpassive fit of the suprastructures, fatigue due to biomechanical overload, and improper placement of implants.<sup>3,4</sup> Size limitations and the material used to fabricate retaining screws also increase their susceptible to fracture. This can lead to challenging situations when screws fracture and require retrieval. Sometimes screw fragments cannot be removed, rendering the existing restoration unusable, and soft tissue coverage of the implants might be required to allow fabrication of alternative prostheses.<sup>5</sup> Fortunately, it is possible to retrieve fractured screw fragments in most situations, especially if the screw emerges from the implant.<sup>6</sup>

Recently, a fork-shaped tip and long-shank stainless steel instrument (Fragment Fork; Astra Tech), used in a slow-speed handpiece, has been introduced to remove and retrieve fractured screw fragments. This instrument allows retrieval of screw fragments from the apical portion of the implant body even though no portion of the screw protrudes from the implant.<sup>7</sup> However, there are still some situations where a fractured screw remain lodged within the implant body and the fork-shaped tip is unsuccessful in removing the fragment. This report describes the use of a fragment removal instrument together with ultrasonic instrumentation to retrieve a screw fragment.

A 60-year-old healthy white man presented with 4 broken screws in dental implants (Splint; Zimmer Dental), replacing mandibular first and second molars bilaterally (Fig. 1). The patient reported that several dentists had attempted but failed to remove the

broken screw fragments, and they had advised him that the only remedy would be to have the implants removed and replaced. Clinical examination revealed broken screws fragments at the apical part of the implants together with significant damage to the internal threads. Several issues were discussed with the patient, including the chances of successfully removing the screw fragments from the implants and that successful removal of the screw fragments did not guarantee that the implants would be serviceable as a result of damage to the internal threads of the implants.

The proposed method described here was presented to the patient, together with benefits and risks, and informed consent was obtained from the patient for another attempt to remove the screws and rethread the implants, if required, so that they could potentially support and retain future restorations.

<sup>a</sup>Assistant Professor, Oral and Maxillofacial Rehabilitation Department, College of Dentistry, King Abdulaziz University, Jeddah, Saudi Arabia.

<sup>b</sup>Postdoctoral fellow, Center for Craniofacial Molecular Biology (CCMB), Herman Ostrow School of Dentistry, University of Southern California.

<sup>c</sup>Director, Implant Dentistry, Ralph and Jean Bleak Professor of Restorative Dentistry; and Codirector, Advanced Prosthodontics, Herman Ostrow School of Dentistry, University of Southern California.

<sup>d</sup>Professor, Division of Restorative and Prosthetic Dentistry, College of Dentistry, The Ohio State University.



## PROCEDURE

1. Use the special fork-shaped tip of the long-shank stainless steel instrument (Fragment Fork; Astra Tech) to thread the broken screw fragment deeper into the implant (Fig. 2).

2. Apply a retapping tool (Zimmer Dental) to retap the damaged threads by gently rotating the retapping tool clockwise by no more than 180 degrees and then rotating it counterclockwise (Fig. 3).

3. Try to remove the fractured screw with the forked screw retrieval instrument after retapping the threads above the fragments. In this patient, 3 of the fractured screws were successfully removed. However, the fourth screw remained lodged.

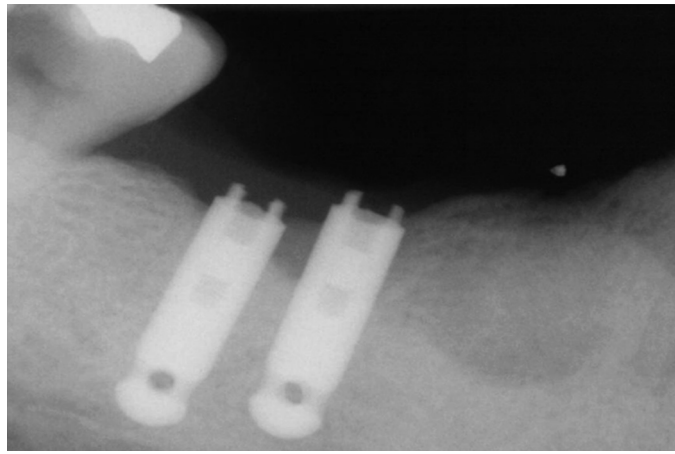
4. For remaining fragments, use ultrasonic instrumentation. Apply with copious irrigation to prevent trauma from heat to the surrounding structures. Alternate the ultrasonic instrumentation with gentle use of the retapping instrument. For this implant, the technique removed a ring of metal, which appeared to be part of a damaged thread of the implant (Fig. 4A).

5. Remove the final fractured screw fragment with the forked screw removal tool (Fig. 4B).


## DISCUSSION

Depending on the depth of the screw fragment, a fractured screw can be a simple clinical complication to resolve or a very difficult and time-consuming procedure that is not always successfully resolved. Obviously the simplest way to manage this complication is for clinicians to understand screw joint mechanics and that all screws have a limit to their ability to maintain their preload. In this particular patient, not only was there an issue with screw fracture, there were also previous attempts to remove the screw fragments, resulting in damaged internal threads of the implant.

When screw fracture occurs, the most important consideration is to not damage the internal threads of the implant. If the screw fragments are



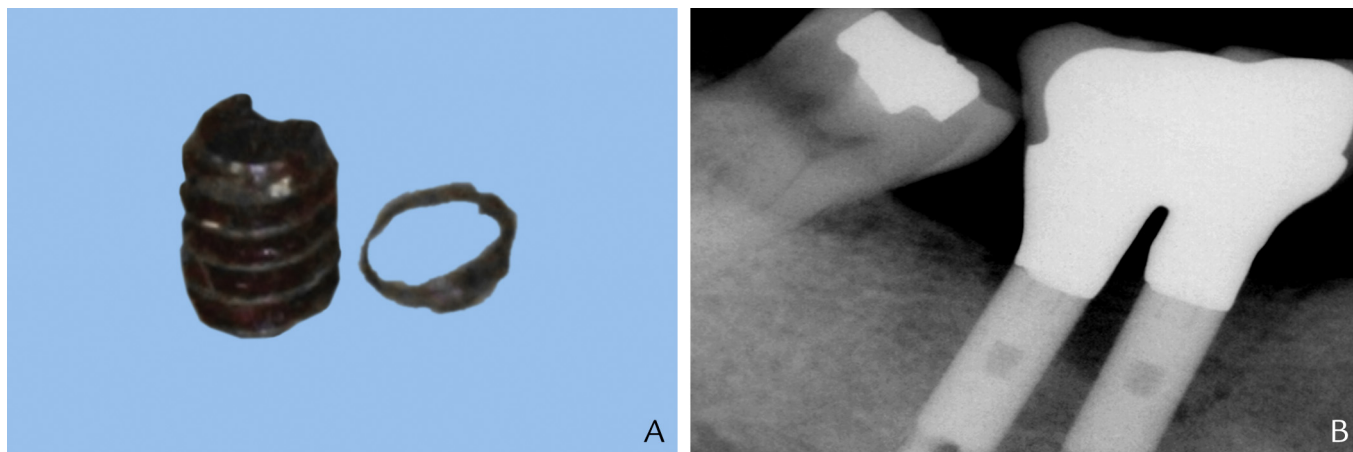
**1** Periapical radiograph showing remaining screw fragments within implants.



**2** Fragment Fork. (Please note fork-shaped tip of instrument.)



**3** Tapping instrument (Zimmer Dental).



**4** A, Screw fragment and separated ring that were retrieved from implant after serial application of ultrasonic instrumentation and use of tapping tool. B, Periapical radiograph after delivery of definitive restoration fabricated on implants with broken screw fragments.

loose, an attempt to remove it by use of an explorer should be the first step. If unsuccessful, an instrument made for retrieval of broken screws, such as the forked instrument, should be tried. If thread damage is present, then retapping the threads may be attempted; this tap must be obtained from the manufacturer of the implant, as the thread design is specific to the implant type. To facilitate tapping the threads, the screw fragment should be displaced deeper into the implant to allow application of the tap. Although this might seem counterintuitive when removing the screw fragment, it is a necessary step.

At times the screw fragment is wedged in a damaged area of the implant, or fragments of the damaged

implant threads might hinder the path of the fractured screw. In these instances, ultrasonic instrumentation may help loosen additional fragments and allow removal of screw fragments. Copious irrigation must be used whenever ultrasonic instrumentation is applied.

## REFERENCES

1. Chee WW, Torbati A, Albouy JP. Retrievable cemented implant restorations. Comparative study. *J Prosthodont* 1998;7:120-5.
2. Goodacre CJ, Bernal G, Rungcharassaeng K, Kan JY. Clinical complications with implants and implant prostheses. *J Prosthet Dent* 2003;90:121-32.
3. Rosenstiel SF, Land MF, Fujimoto J. Contemporary fixed prosthodontics. 4th ed. St Louis: Mosby; 2006. p. 425.
4. Cranin AN, Dibling JB, Simons A, Klein M, Sirakian A. Report of the incidence of implant

insert fracture and repair of Core-Vent dental implants. *J Oral Implantol* 1990;16:184-8.

5. Ow RK, Ho KH. Retrieval of the resilient element in an osseointegrated implant system. *J Prosthet Dent* 1992;68:93-5.
6. Williamson RT, Robinson FG. Retrieval technique for fractured implant screws. *J Prosthet Dent* 2001;86:549-50.
7. Yilmaz B, McGlumphy E. A technique to retrieve fractured implant screws. *J Prosthet Dent* 2011;105:137-8.

## Corresponding author:

Dr Alireza Moshaverinia  
Center for Craniofacial Molecular Biology (CCMB)  
Ostrow School of Dentistry  
University of Southern California  
2250 Alcazar Street, CSA 103  
Los Angeles, CA 90033  
E-mail: [moshaver@usc.edu](mailto:moshaver@usc.edu)

Copyright © 2014 by the Editorial Council for  
*The Journal of Prosthetic Dentistry*.