

# Classification System for Partial Edentulism

Thomas J. McGarry, DDS,<sup>1</sup> Arthur Nimmo, DDS,<sup>2</sup> James F. Skiba, DDS,<sup>3</sup>  
Robert H. Ahlstrom, DDS, MS,<sup>4</sup> Christopher R. Smith, DDS,<sup>5</sup>  
Jack H. Koumjian, DDS, MSD,<sup>6</sup> and Nancy S. Arbree, DDS, MS<sup>7</sup>

---

The American College of Prosthodontists (ACP) has developed a classification system for partial edentulism based on diagnostic findings. This classification system is similar to the classification system for complete edentulism previously developed by the ACP. These guidelines are intended to help practitioners determine appropriate treatments for their patients. Four categories of partial edentulism are defined, Class I to Class IV, with Class I representing an uncomplicated clinical situation and class IV representing a complex clinical situation. Each class is differentiated by specific diagnostic criteria. This system is designed for use by dental professionals involved in the diagnosis and treatment of partially edentulous patients. Potential benefits of the system include (1) improved intraoperator consistency, (2) improved professional communication, (3) insurance reimbursement commensurate with complexity of care, (4) improved screening tool for dental school admission clinics, (5) standardized criteria for outcomes assessment and research, (6) enhanced diagnostic consistency, and (7) simplified aid in the decision to refer a patient.

*J Prosthodont 2002;11:181-193. Copyright © 2002 by The American College of Prosthodontists.*

**INDEX WORDS:** diagnosis, treatment planning, prosthodontics, dental education, outcomes assessment, quality assurance, treatment outcomes, patient risk profiles

---

PARTIALLY EDENTULOUS patients exhibit a wide range of physical variations and health conditions. The absence of organized diagnostic criteria for partial edentulism has been a long-standing impediment to effective recognition

of risk factors that may affect treatment outcomes. Although described thoroughly in the dental literature,<sup>1-9</sup> the diverse nature of partial edentulism has not been organized in such a way to guide dental professionals in the treatment planning process. To address this problem, the American College of Prosthodontists (ACP) Subcommittee on Prosthodontic Classification was formed and charged with developing a classification system for partial edentulism consistent with the existing classification system for complete edentulism.<sup>2</sup> A summary of the ACP edentulous classification system is given in Table 1.

The purpose of this classification system is to provide a framework for the organization of clinical observations. Clinical variables that establish different levels of partial edentulism are organized in a simplified, sequential progression designed to facilitate consistent and predictable treatment planning decisions. This framework is designed to indicate increasing levels of diagnostic and treatment complexity presented by patients with varying degrees of partial edentulism. This may suggest points at which referral to other specialists is appropriate. The framework is structured to support

---

<sup>1</sup>Private Practice, Oklahoma City, OK.

<sup>2</sup>Professor and Chairman, Department of Prosthodontics, University of Florida College of Dentistry, Gainesville, FL.

<sup>3</sup>Private Practice, Montclair, NJ.

<sup>4</sup>Private Practice, Reno, NV, and Associate Clinical Professor, Department of Restorative Dentistry, University of the Pacific, Stockton, CA.

<sup>5</sup>Associate Professor, Department of Clinical Surgery, University of Chicago, Chicago, IL.

<sup>6</sup>Clinical Associate Professor, Department of Restorative Dentistry, University of California-San Francisco School of Dentistry, San Francisco, CA, and Private Practice, Palo Alto, CA.

<sup>7</sup>Professor and Associate Dean of Academic Affairs, Tufts University School of Dental Medicine and Private Practice, Boston, MA.

Accepted April 8, 2002.

This project was funded by the American College of Prosthodontists.

Presented at the Annual Sessions of the American Dental Education Association, Washington, DC, April 2, 2000, and the American College of Prosthodontists, Hawaii, November 15, 2000.

Correspondence to: Thomas J. McGarry, DDS, 4320 McAuley Blvd., Oklahoma City, OK 73120.

Copyright © 2002 by The American College of Prosthodontists

1059-941X/02/1103-0006\$35.00/0

doi:10.1053/jpro.2002.126094

**TABLE 1.** ACP Classification System of Complete Edentulism**Class I**

This class characterizes the stage of edentulism that is most apt to be successfully treated with complete dentures using conventional prosthodontic techniques. All 4 of the diagnostic criteria are favorable.

- Residual bone height of  $\geq 21$  mm measured at the least vertical height of the mandible on a panoramic radiograph.
- Residual ridge morphology resistant to horizontal and vertical movement of the denture base; type A maxilla.
- Location of muscle attachments conducive to denture base stability and retention; type A or B mandible
- Class I maxillomandibular relationship

**Class II**

This class is distinguished by the continued physical degradation of the denture-supporting anatomy. It is also characterized by the early onset of systemic disease interactions and by specific patient management and lifestyle considerations.

- Residual bone height of 16 to 20 mm measured at the least vertical height of the mandible on a panoramic radiograph
- Residual ridge morphology resistant to horizontal and vertical movement of the denture base; type A or B maxilla
- Location of muscle attachments with limited influence on denture base stability and retention; type A or B mandible
- Class I maxillomandibular relationship
- Minor modifiers, psychosocial considerations, mild systemic disease with oral manifestations

**Class III**

This class is characterized by the need for surgical revision of supporting structures to allow for adequate prosthodontic function. Additional factors now play a significant role in treatment outcomes.

- Residual alveolar bone height of 11 to 15 mm measured at the least vertical height of the mandible on a panoramic radiograph
- Residual ridge morphology with minimum influence to resist horizontal or vertical movement of the denture base; type C maxilla
- Location of muscle attachments with moderate influence on denture base stability and retention; type C mandible
- Class I, II, or III maxillomandibular relationship
- Conditions requiring preprosthetic surgery
  - Minor soft tissue procedures
  - Minor hard tissue procedures including alveoloplasty
  - Simple implant placement; no augmentation required
  - Multiple extractions leading to complete edentulism for immediate denture placement
  - Limited interarch space (18 to 20 mm)
- Moderate psychosocial considerations and/or moderate oral manifestations of systemic diseases or conditions such as xerostomia
- TMD symptoms
- Large tongue (occludes interdental space) with or without hyperactivity
- Hyperactive gag reflex

**Class IV**

This class represents the most debilitated edentulous condition. Surgical reconstruction is almost always indicated but cannot always be accomplished because of the patient's health, preferences, past dental history, and financial considerations. When surgical revision is not an option, prosthodontic techniques of a specialized nature must be used to achieve an adequate outcome.

- Residual vertical bone height of  $\leq 10$  mm measured at the least vertical height of the mandible on a panoramic radiograph
- Class I, II, or III maxillomandibular relationships
- Residual ridge offering no resistance to horizontal or vertical movement; type D maxilla
- Muscle attachment location that can be expected to have significant influence on denture base stability and retention; type D or E mandible
- Major conditions requiring preprosthetic surgery
  - Complex implant placement, augmentation required
  - Surgical correction of dentofacial deformities required
  - Hard tissue augmentation required
  - Major soft tissue revision required, that is, vestibular extensions with or without soft tissue grafting
- History of paresthesia or dysesthesia
- Insufficient interarch space necessitating surgical correction
- Acquired or congenital maxillofacial defects
- Severe oral manifestation of systemic disease or conditions such as sequelae from oncologic treatment
- Maxillomandibular ataxia (incoordination)
- Hyperactivity of tongue possibly associated with a retracted tongue position and/or its associated morphology
- Hyperactive gag reflex managed with medication
- Refractory patient (a patient who presents with chronic complaints following appropriate therapy), who may continue to have difficulty achieving their treatment expectations despite the thoroughness or frequency of the treatments provided.
- Psychosocial conditions warranting professional intervention

diagnostically driven treatment plan options and will also be useful in an educational environment for triaging the patient upon entry into an institutional setting.

Partial edentulism is defined as the absence of some but not all of the natural teeth in a dental arch. In a partially edentulous patient, the loss and continuing degradation of the alveolar bone, adjacent teeth, and supporting structures influence the level of difficulty in achieving adequate prosthetic restoration. The quality of the supporting structures contributes to the overall condition and is considered in the diagnostic levels of the classification system.

Only the most significant diagnostic criteria have been identified. Selection of appropriate treatment will be developed subsequently in a Parameters of Care document.<sup>3</sup> It is anticipated that both the edentulous and partially edentulous classification systems will be incorporated into existing electronic diagnostic and procedural databases (SNO-DENT, ICD, CPT, and CDT).

The classification system is intended to offer the following benefits:

1. Improved intraoperator consistency
2. Improved professional communication
3. Insurance reimbursement commensurate with complexity of care
4. An objective method for patient screening in dental education
5. Standardized criteria for outcomes assessment and research
6. Improved diagnostic consistency
7. A simplified, organized aid in the decision-making process relating to referral.

## Applications

Diagnosis must be determined before treatment recommendations can be made. While this classification system is not a predictor of success of the prosthodontic treatment, clinical outcomes will be evaluated in terms of evidence-based criteria.

When combined with the Parameters of Care document, this classification system will provide a basis for diagnosis and treatment procedures. The experiences gained will enable updating of the Parameters of Care. The classification system will be

subject to revision based upon input from clinicians, as well as when new diagnostic and treatment information becomes available.

## Review of the Diagnostic Criteria

This section describes four broad diagnostic categories relevant to classification of partially edentulous patients:

1. Location and extent of the edentulous area(s)
2. Condition of abutments
3. Occlusion
4. Residual ridge characteristics.

The criteria descriptions begin with the least complicated and progress to the most complicated. The diagnostic criteria are as follows.

### ***Criteria 1: Location and Extent of the Edentulous Area(s)***

#### ***A. Ideal or minimally compromised edentulous area***

The edentulous span is confined to a single arch and 1 of the following:

- Any anterior maxillary edentulous area that does not exceed 2 incisors
- Any anterior mandibular edentulous area that does not exceed 4 incisors
- Any posterior maxillary or mandibular edentulous area that does not exceed 2 premolars, or 1 premolar and 1 molar.

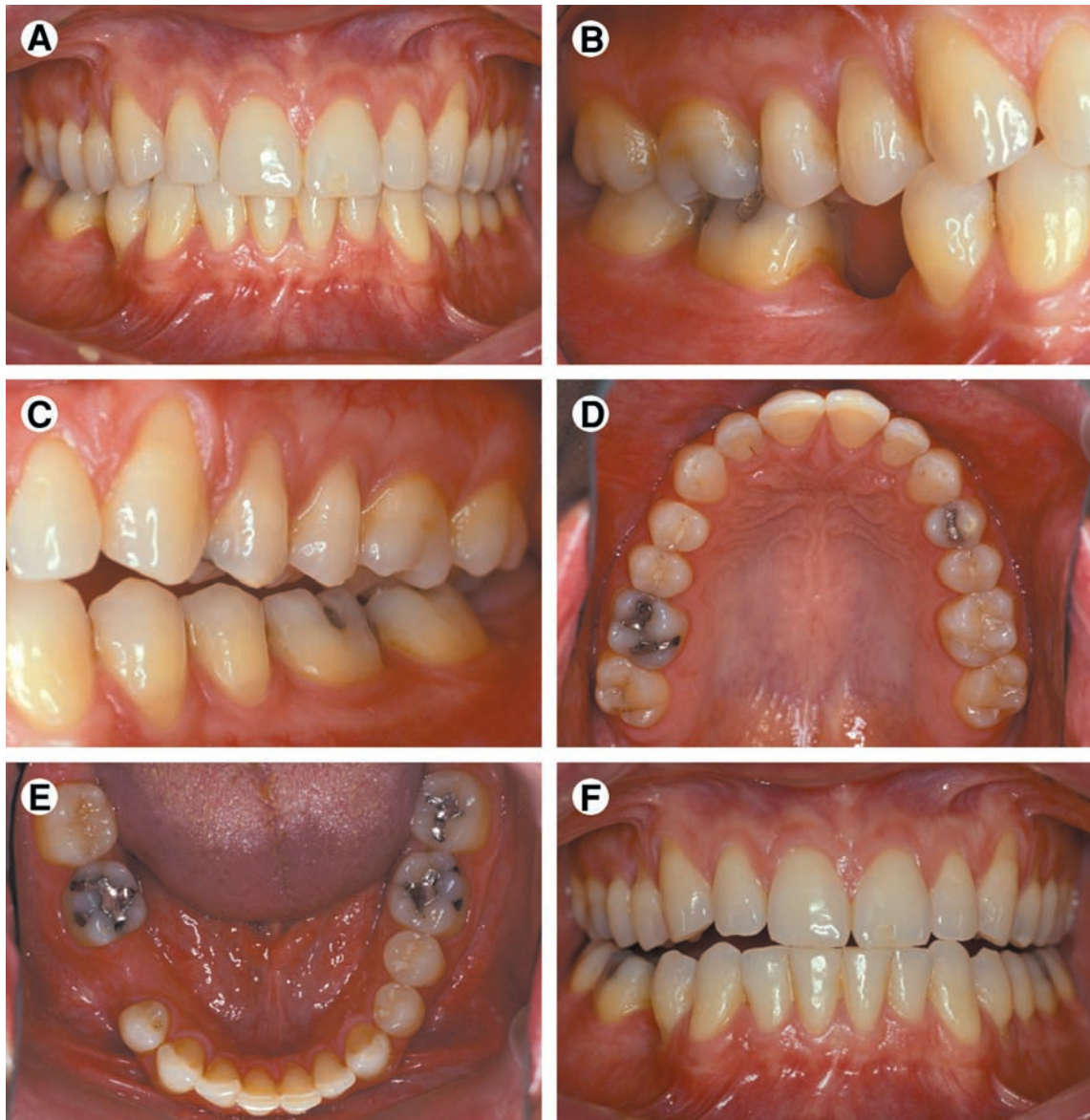#### ***B. Moderately compromised edentulous area***

Edentulous areas in both arches and in 1 of the following:

- Any anterior maxillary edentulous area that does not exceed 2 incisors
- Any anterior mandibular edentulous area that does not exceed 4 incisors
- Any posterior maxillary or mandibular edentulous area that does not exceed 2 premolars, or 1 premolar and 1 molar
- A missing maxillary or mandibular canine.

#### ***C. Substantially compromised edentulous area***

- Any posterior maxillary or mandibular edentulous area greater than 3 teeth or 2 molars
- Any edentulous areas including anterior and posterior areas of 3 or more teeth.



**Figure 1.** Class I patient. This patient is categorized in Class I due to an ideal or minimally compromised edentulous area, abutment condition, and occlusion. There is a single edentulous area in 1 sextant. The residual ridge is considered type A. (A) Frontal view, maximum intercuspation. (B) Right lateral view, maximum intercuspation. (C) Left lateral view, maximum intercuspation. (D) Occlusal view, maxillary arch. (E) Occlusal view, mandibular arch. (F) Frontal view, protrusive relationship.

*D. Severely compromised edentulous area*

Any edentulous area or combination of edentulous areas requiring a high level of patient compliance.

**Criteria 2: Abutment Conditions**

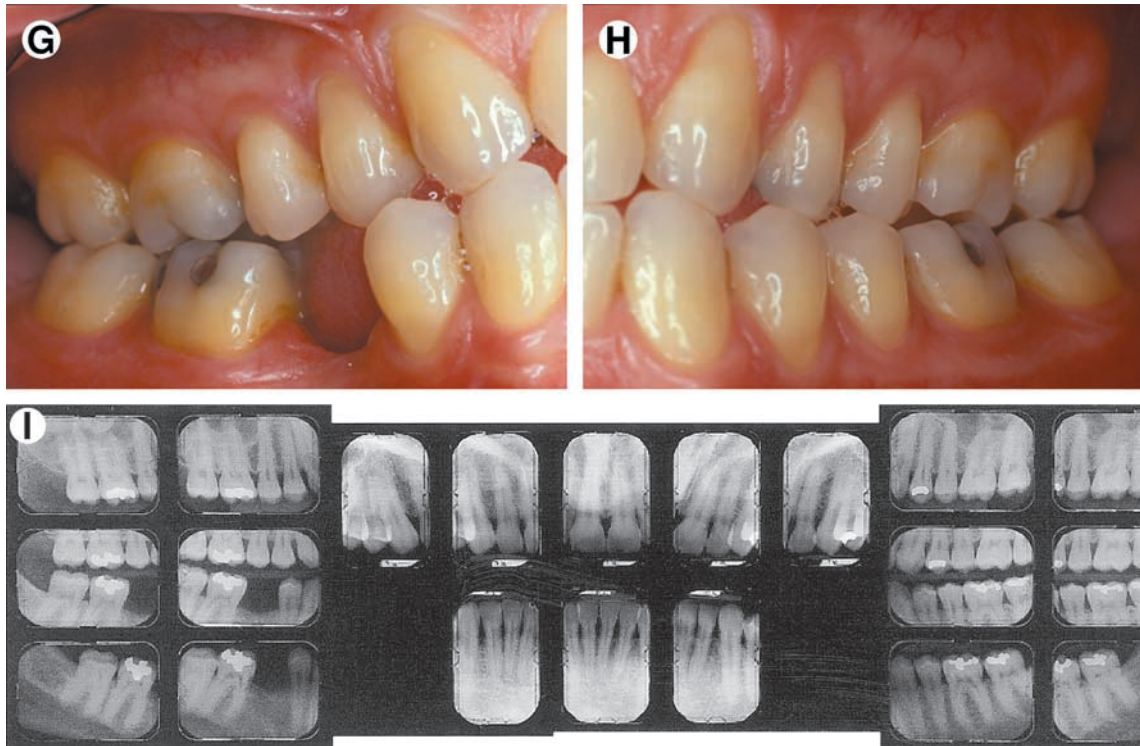
*A. Ideal or minimally compromised abutment conditions*

No preprosthetic therapy is indicated.

*B. Moderately compromised abutment condition*

- Abutments in 1 or 2 sextants\* have insufficient tooth structure to retain or support intracoronar or extracoronar restorations.
- Abutments in 1 or 2 sextants require localized adjunctive therapy (ie, periodontal, endodontic, or orthodontic procedures).





**Figure 1. (Cont'd)** (G) Right lateral view, right working movement. (H) Left lateral view, left working movement. (I) Full mouth radiographic series.

*C. Substantially compromised abutment condition*

- Abutments in 3 sextants have insufficient tooth structure to retain or support intracoronary or extracoronary restorations.
- Abutments in 3 sextants require more substantial localized adjunctive therapy (ie, periodontal, endodontic, or orthodontic procedures).

*D. Severely compromised abutment condition*

- Abutments in 4 or more sextants have insufficient tooth structure to retain or support intracoronary or extracoronary restorations.

\*A sextant is a subdivision of the dental arch. The maxillary and mandibular dental arches may be subdivided into 6 areas or sextants. In the maxilla, the right posterior sextant extends from tooth 1 to tooth 5, the left posterior sextant extends from tooth 12 to tooth 16, and the anterior sextant extends from tooth 6 to tooth 11. In the mandible, the right posterior sextant extends from tooth 28 to tooth 32, the left posterior sextant extends from tooth 17 to tooth 21, and the anterior sextant extends from tooth 22 to tooth 27.

- Abutments in 4 or more sextants require extensive adjunctive therapy (ie, periodontal, endodontic, or orthodontic procedures).
- Abutments have guarded prognoses.

**Criteria 3: Occlusion**

*A. Ideal or minimally compromised occlusal characteristics*

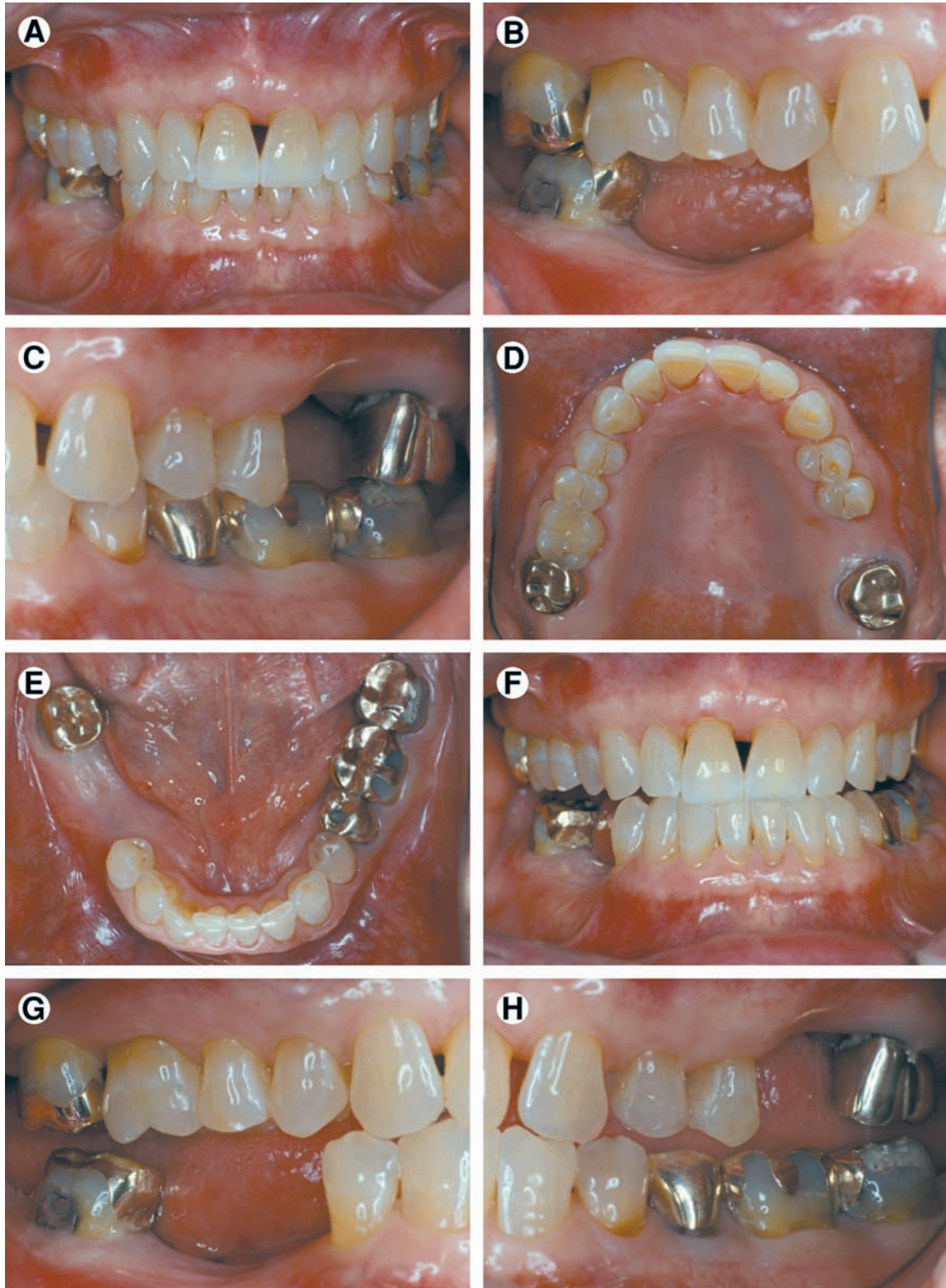
- No preprosthetic therapy is required
- Class I molar and jaw relationships are seen.

*B. Moderately compromised occlusal characteristics*

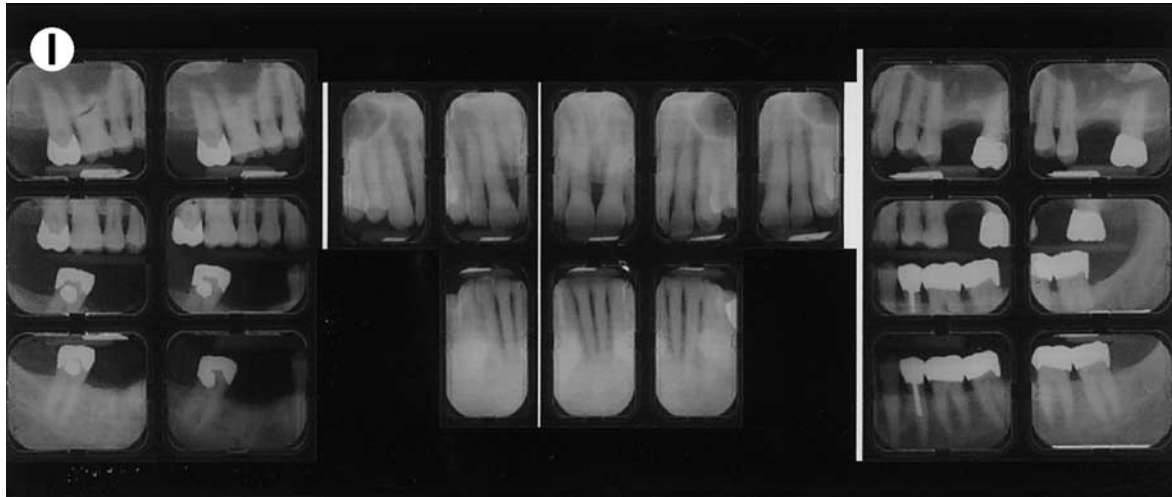
- Occlusion requires localized adjunctive therapy (eg, enameloplasty on premature occlusal contacts).
- Class I molar and jaw relationships are seen.

*C. Substantially compromised occlusal characteristics*

- Entire occlusion must be reestablished, but without any change in the occlusal vertical dimension.
- Class II molar and jaw relationships are seen.



**Figure 2.** Class II patient. This patient is Class II because he has edentulous areas in 2 sextants in different arches. (A) Frontal view, maximum intercuspation. (B) Right lateral view, maximum intercuspation. (C) Left lateral view, maximum intercuspation. (D) Occlusal view, maxillary arch. (E) Occlusal view, mandibular arch. (F) Frontal view, protrusive relationship. (G) Right lateral view, right working movement. (H) Left lateral view, left working movement.



**Figure 2. (Cont'd) (I)** Full mouth radiographic series.

*D. Severely compromised occlusal characteristics*

- Entire occlusion must be reestablished, including changes in the occlusal vertical dimension.
- Class II division 2 and Class III molar and jaw relationships are seen.

**Criteria 4: Residual Ridge Characteristics**

The criteria published for the Classification System for Complete Edentulism are used to categorize any edentulous span present in the partially edentulous patient (see Table 1).

**Classification System for Partial Edentulism**

The 4 criteria and their subclassifications are organized into an overall classification system for partial edentulism.

**Class I (Fig 1A–I)**

This class is characterized by ideal or minimal compromise in the location and extent of edentulous area (which is confined to a single arch), abutment conditions, occlusal characteristics, and residual ridge conditions. All 4 of the diagnostic criteria are favorable.

1. The location and extent of the edentulous area are ideal or minimally compromised:

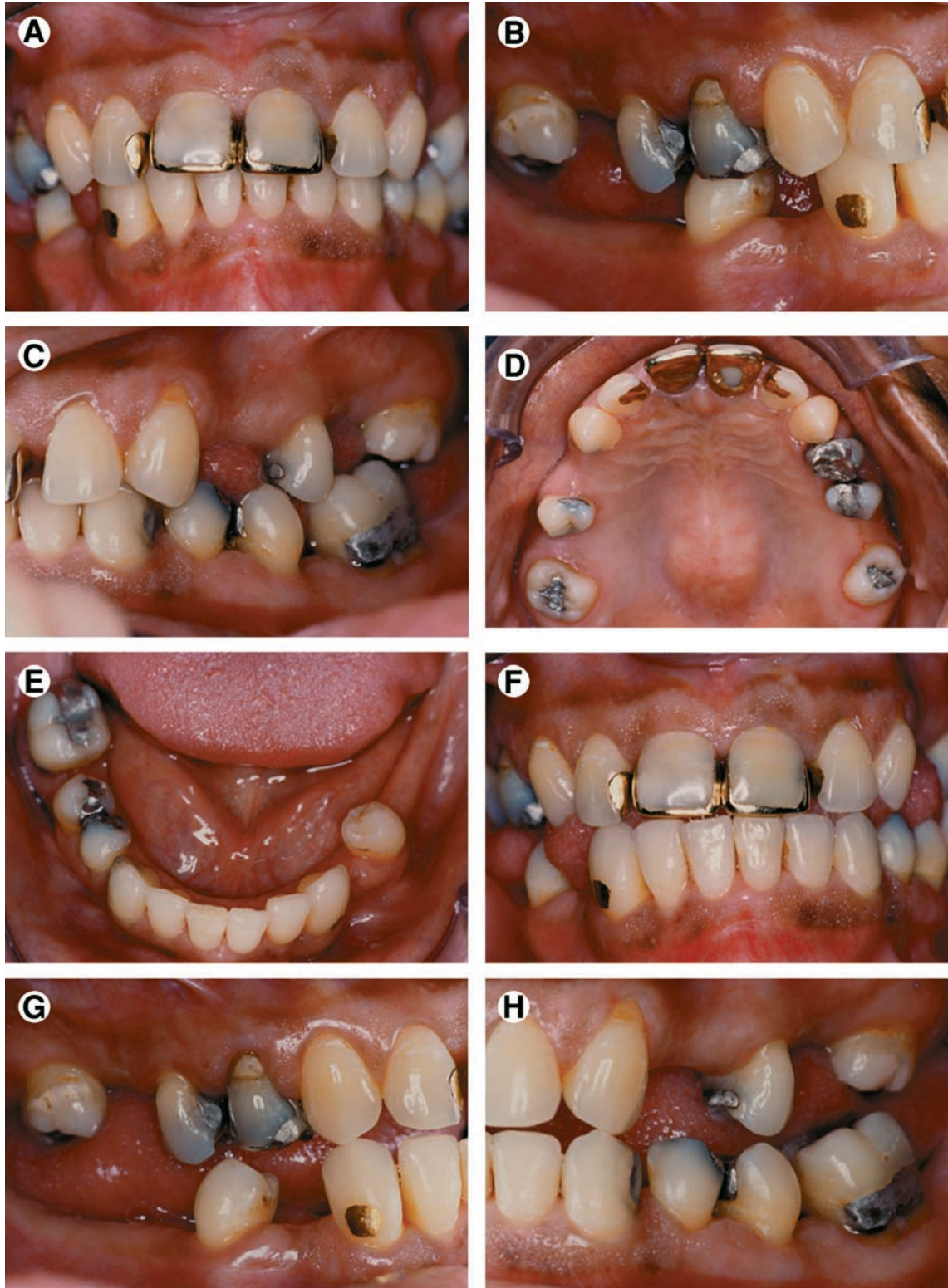
- The edentulous area is confined to a single arch.
  - The edentulous area does not compromise the physiologic support of the abutments.
  - The edentulous area may include any anterior maxillary span that does not exceed 2 incisors, any anterior mandibular span that does not exceed 4 missing incisors, or any posterior span that does not exceed 2 premolars or 1 premolar and 1 molar.
2. The abutment condition is ideal or minimally compromised, with no need for preprosthetic therapy.
  3. The occlusion is ideal or minimally compromised, with no need for preprosthetic therapy; maxillomandibular relationship: Class I molar and jaw relationships.
  4. Residual ridge morphology conforms to the Class I complete edentulism description.

**Class II (Fig 2)**

This class is characterized by moderately compromised location and extent of edentulous areas in both arches, abutment conditions requiring localized adjunctive therapy, occlusal characteristics requiring localized adjunctive therapy, and residual ridge conditions.

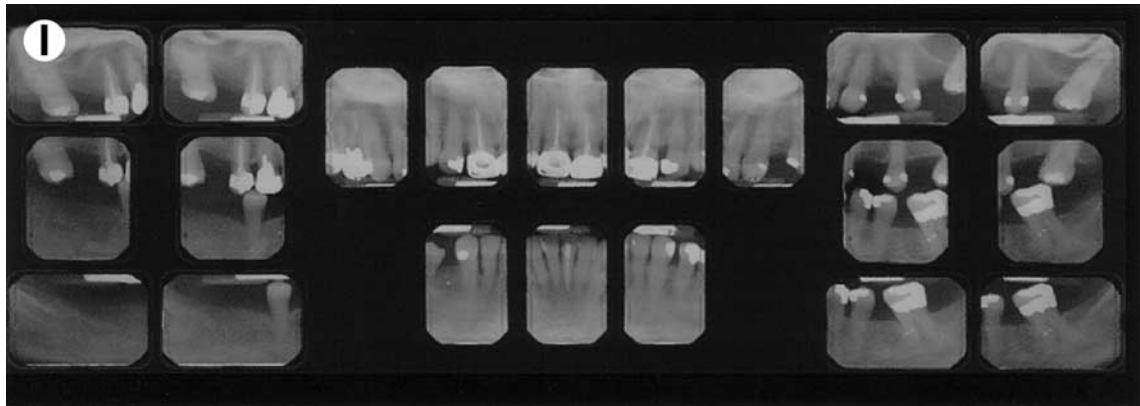
1. The location and extent of the edentulous area are moderately compromised:
  - Edentulous areas may exist in 1 or both arches.





**Figure 3.** Class III patient. This patient is Class III because the edentulous area(s) are located in both arches and multiple locations within each arch. The abutment condition is substantially compromised due to the need for extracoronal restorations. There are teeth that are extruded and malpositioned. The occlusion is substantially compromised because reestablishment of the occlusal scheme is required without a change in the occlusal vertical dimension. (A) Frontal view, maximum intercuspitation. (B) Right lateral view, maximum intercuspitation. (C) Left lateral view, maximum intercuspitation. (D) Occlusal view, maxillary arch. (E) Occlusal view, mandibular arch. (F) Frontal view, protrusive relationship. (G) Right lateral view, right working movement. (H) Left lateral view, left working movement.





**Figure 3. (Cont'd) (I)** Full mouth radiographic series.

- The edentulous areas do not compromise the physiologic support of the abutments.
  - Edentulous areas may include any anterior maxillary span that does not exceed 2 incisors, any anterior mandibular span that does not exceed 4 incisors, any posterior span (maxillary or mandibular) that does not exceed 2 premolars, or 1 premolar and 1 molar or any missing canine (maxillary or mandibular).
2. Condition of the abutments is moderately compromised:
    - Abutments in 1 or 2 sextants have insufficient tooth structure to retain or support intracoronaral or extracoronaral restorations.
    - Abutments in 1 or 2 sextants require localized adjunctive therapy.
  3. Occlusion is moderately compromised:
    - Occlusal correction requires localized adjunctive therapy.
    - Maxillomandibular relationship: Class I molar and jaw relationships.
  4. Residual ridge morphology conforms to the Class II complete edentulism description.

### ***Class III (Fig 3)***

This class is characterized by substantially compromised location and extent of edentulous areas in both arches, abutment condition requiring substantial localized adjunctive therapy, occlusal characteristics requiring reestablishment of the entire occlusion without a change in the occlusal vertical dimension, and residual ridge condition.

1. The location and extent of the edentulous areas are substantially compromised:

- Edentulous areas may be present in 1 or both arches.
- Edentulous areas compromise the physiologic support of the abutments.
- Edentulous areas may include any posterior maxillary or mandibular edentulous area greater than 3 teeth or 2 molars, or anterior and posterior edentulous areas of 3 or more teeth.

2. The condition of the abutments is moderately compromised:

- Abutments in 3 sextants have insufficient tooth structure to retain or support intracoronaral or extracoronaral restorations.
- Abutments in 3 sextants require more substantial localized adjunctive therapy (ie, periodontal, endodontic or orthodontic procedures).
- Abutments have a fair prognosis.

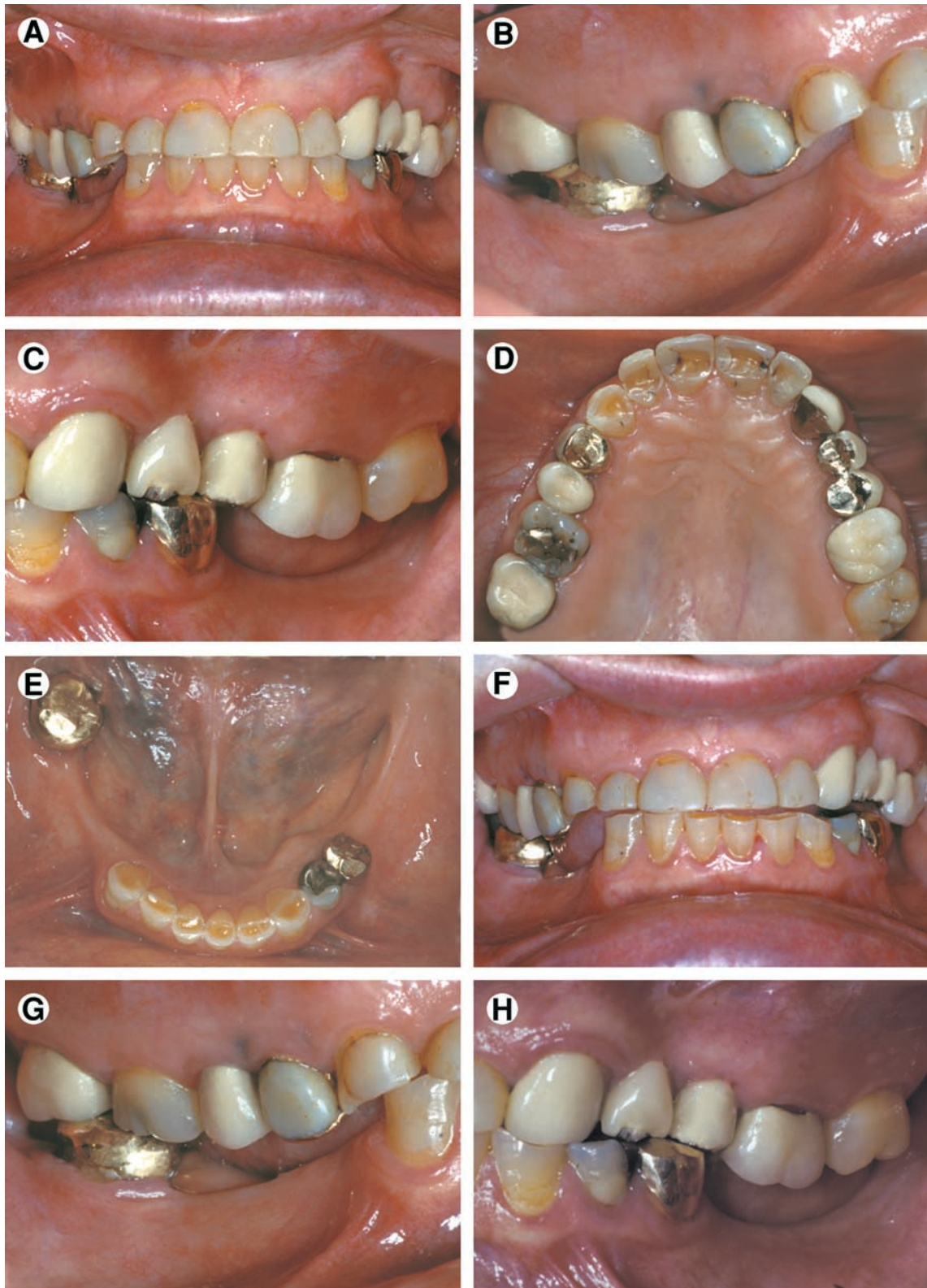
3. Occlusion is substantially compromised:

- Requires reestablishment of the entire occlusal scheme without an accompanying change in the occlusal vertical dimension.
- Maxillomandibular relationship: Class II molar and jaw relationships.

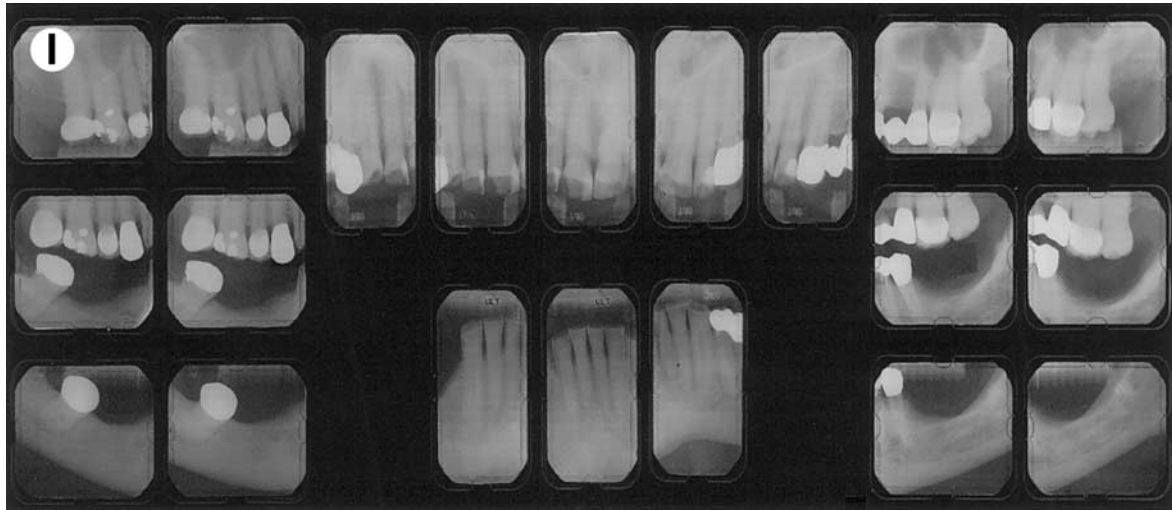
4. Residual ridge morphology conforms to the Class III complete edentulism description.

### ***Class IV (Fig 4)***

This class is characterized by severely compromised location and extent of edentulous areas with



**Figure 4.** Class IV patient. Edentulous areas are found in both arches, and the physiologic abutment support is compromised. Abutment condition is severely compromised due to advanced attrition and failing restorations, necessitating extracoronaral restorations and adjunctive therapy. The occlusion is severely compromised, necessitating reestablishment of occlusal vertical dimension and a proper occlusal scheme. (A) Frontal view, maximum intercuspation. (B) Right lateral view, maximum intercuspation. (C) Left lateral view, maximum intercuspation. (D) Occlusal view, maxillary arch. (E) Occlusal view, mandibular arch. (F) Frontal view, protrusive relationship. (G) Right lateral view, right working movement. (H) Left lateral view, left working movement.



**Figure 4. (Cont'd)** (I) Full mouth radiographic series.

guarded prognosis, abutments requiring extensive therapy, occlusion characteristics requiring reestablishment of the occlusion with a change in the occlusal vertical dimension, and residual ridge conditions.

1. The location and extent of the edentulous areas results in severe occlusal compromise:
  - Edentulous areas may be extensive and may occur in both arches.
  - Edentulous areas compromise the physiologic support of the abutment teeth to create a guarded prognosis.
  - Edentulous areas include acquired or congenital maxillofacial defects.
  - At least 1 edentulous area has a guarded prognosis.
2. Abutments are severely compromised:
  - Abutments in 4 or more sextants have insufficient tooth structure to retain or support intracoronar or extracoronar restorations.
  - Abutments in 4 or more sextants require extensive localized adjunctive therapy.
  - Abutments have a guarded prognosis.
3. Occlusion is severely compromised:
  - Reestablishment of the entire occlusal scheme, including changes in the occlusal vertical dimension, is necessary.
  - Maxillomandibular relationship: class II division 2 or Class III molar and jaw relationships.

4. Residual ridge morphology conforms to the class IV complete edentulism description.

Other characteristics include severe manifestations of local or systemic disease, including sequelae from oncologic treatment, maxillomandibular dyskinesia and/or ataxia, and refractory patient (a patient who presents with chronic complaints following appropriate therapy).

### **Guidelines for the Use of Classification System for Partial Edentulism**

The analysis of diagnostic factors is facilitated with the use of a worksheet (Table 2). Each criterion is evaluated and a checkmark placed in the appropriate box. In those instances in which a patient's diagnostic criteria overlap 2 or more classes, the patient is placed in the more complex class.

The following additional guidelines should be followed to ensure consistent application of the classification system:

1. Consideration of future treatment procedures must not influence the choice of diagnostic level.
2. Initial preprosthetic treatment and/or adjunctive therapy can change the initial classification level. Classification may need to be reassessed after existing prostheses are removed.
3. Esthetic concerns or challenges raise the classification by 1 level in Class I and II patients.



4. The presence of TMD symptoms raises the classification by 1 or more levels in Class I and II patients.
5. In a patient presenting with an edentulous maxilla opposing a partially edentulous mandible, each arch is diagnosed according to the appropriate classification system; that is, the maxilla is classified according to the complete edentulism classification system, and the mandible is classified according to the partial edentulism classification system. The sole exception to this rule occurs when the patient presents with an edentulous mandible opposed by a partially edentulous or dentate maxilla. This clinical situation presents significant complexity and potential long-term morbidity and as such, should be diagnosed as a Class IV in either system.
6. Periodontal health is intimately related to the diagnosis and prognosis for partially edentulous patients. For the purpose of this system, it is assumed that patients will receive therapy to

achieve and maintain periodontal health so that appropriate prosthodontic care can be accomplished.

### Closing Statement

The classification system for partial edentulism is based on the most objective criteria available to facilitate uniform use of the system. Such standardization may lead to improved communications among dental professionals and third parties. This classification system will serve to identify those patients most likely to require treatment by a specialist or by a practitioner with additional training and experience in advanced techniques. This system should also be valuable to research protocols as different treatment procedures are evaluated. With the increasing complexity of patient treatment, this partial edentulism classification system, coupled with the complete edentulism classification system, will help dental school faculty assess entering pa-

**TABLE 2.** Worksheet Used to Determine Classification

	<i>Class I</i>	<i>Class II</i>	<i>Class III</i>	<i>Class IV</i>
Location & Extent of Edentulous Areas				
Ideal or minimally compromised—single arch				
Moderately compromised—both arches				
Substantially compromised—>3 teeth				
Severely compromised—guarded prognosis				
Congenital or acquired maxillofacial defect				
Abutment Condition				
Ideal or minimally compromised				
Moderately compromised—1-2 sextants				
Substantially compromised—3 sextants				
Severely compromised—4 or more sextants				
Occlusion				
Ideal or minimally compromised				
Moderately compromised—local adjunctive tx				
Substantially compromised—occlusal scheme				
Severely compromised—change in OVD				
Residual Ridge				
Class I Edentulous				
Class II Edentulous				
Class III Edentulous				
Class IV Edentulous				
Conditions Creating a Guarded Prognosis				
Severe oral manifestations of systemic disease				
Maxillomandibular dyskinesia and/or ataxia				
Refractory patient				

NOTE. Individual diagnostic criteria are evaluated and the appropriate box is checked. The most advanced finding determines the final classification.

*Guidelines for use of the worksheet*

1. Any single criterion of a more complex class places the patient into the more complex class.
2. Consideration of future treatment procedures must not influence the diagnostic level.
3. Initial preprosthetic treatment and/or adjunctive therapy can change the initial classification level.
4. If there is an esthetic concern/challenge, the classification is increased in complexity by one level in Class I and II patients.
5. In the presence of TMD symptoms, the classification is increased in complexity by one or more levels in Class I and II patients.
6. In the situation where the patient presents with an edentulous mandible opposing a partially edentulous or dentate maxilla, classification IV.

tients for the most appropriate patient assignment for better care. Based on use and observations by practitioners, educators, and researchers, this system will be modified as needed.

## Acknowledgement

The authors thank Dr. David Cagna and Dr. Rodney D. Phoenix, Department of Prosthodontics, University of Texas Health Science Center, San Antonio for their assistance in providing the classification illustrations.

## References

1. DeVan MM: The nature of the partial denture foundation: Suggestions for its preservation. *J Prosthet Dent* 1951;2:210-218
2. Applegate OC: An evaluation of the support for the removable partial denture. *J Prosthet Dent* 1960;10:112
3. Reynolds JM: Abutment selection for fixed prosthodontics. *J Prosthet Dent* 1968;19:483-488
4. Mehta JD, Joglekar AP: Vertical jaw relations as a factor in partial dentures. *J Prosthet Dent* 1969;21:618-625
5. Willarson KL: Removable partial denture prosthesis for the periodontal patient. The current status—an option. *Dent Clin North Am* 1969;13:263-279
6. Kelly E: Changes caused by a mandibular removable partial denture opposing a maxillary complete denture. *J Prosthet Dent* 1972;27:140-150
7. Laney WR, Desjardins RP: Surgical preparation of the partially edentulous patient. *Dent Clin North Am* 1973;17:611-630
8. Turner CH, Ritchie GM: The problems of maxillary complete dentures opposed by retained mandibular incisor and canine teeth (I). *Quintessence Int* 1978;9:29-34
9. Culpepper WD, Moulton PS: Considerations in fixed prosthodontics. *Dent Clin North Am* 1979;23:21-35
10. Saunders TR, Gillis RE Jr, Desjardins RP: The maxillary complete denture opposing the mandibular bilateral distal-extension partial denture: Treatment considerations. *J Prosthet Dent* 1979;41:124-128
11. Dibai N, Mechanic E: Prosthodontic treatment for the complex mandibular Class I partially edentulous patient. *J Dent Que* 1980;17:63-65
12. Zarb GA, MacKay HF: The partially edentulous patient. I. The biologic price of prosthodontic intervention. *Aust Dent J* 1980;25:63-68
13. Pekkarinen V, Yli-Urpo A: Dysfunction of the masticatory system and the mutilated dental arch: Anamnestic index, dysfunction index and occlusal index before restorative and prosthetic treatment. *Proc Finn Dent Soc* 1984;80:73-79
14. Misch CE, Judy KW: Classification of partially edentulous arches for implant dentistry. *Int J Oral Implantol* 1987;4:7-13
15. Arlin ML: Dental implants and the partially edentulous patient. Diagnosis and treatment planning. *Oral Health* 1989;79:19-21
16. Devlin H: Replacement of missing molar teeth—A prosthodontic dilemma. *Br Dent J* 1994;176:31-33
17. Goldberg PV: Retention of teeth and placement of implants in the partially edentulous maxilla: the decision-making process. *Dent Implantol Update* 1995;6:9-13
18. Ben-Ur Z, Shifman BZ, Aviv I: Further aspects of design for distal extension removable partial dentures based on the Kennedy classification. *J Oral Rehabil* 1999;26:165-169
19. Ihde SK: Fixed prosthodontics in skeletal Class III patients with partially edentulous jaws and age-related prognathism: The basal osseointegration procedure. *Implant Dent* 1999;8:241-246
20. Sabri R: Management of missing maxillary lateral incisors. *J Am Dent Assoc* 1999;130:80-84
21. McGarry TJ, Nimmo A, Skiba JF, et al: Classification system for complete edentulism. *J Prosthodont* 1999;8:27-39
22. Parameters of Care for the American College of Prosthodontists. *J Prosthodont* 1996;5:3-71